

Vessels in femoral triangle in a rare relationship

Bandyopadhyay M, Biswas S, Roy R

ABSTRACT

The femoral region of the thigh is utilised for various clinical procedures, both open and closed, particularly in respect to arterial and venous cannulations. A rare vascular pattern was observed during the dissection of the femoral region on both sides of the intact formaldehyde-preserved cadaver of a 42-year-old Indian man from West Bengal. The relationships and patterns found were contrary to the belief that the femoral vein is always medial to the artery, just below the inguinal ligament and the common femoral artery. The femoral artery crossed the vein just deep to the inguinal ligament so that the femoral vein was lying deep to the artery at the base of the femoral triangle. Just deep to the inguinal ligament, the profunda femoris artery (deep femoral artery) arose from the femoral artery, and the long saphenous vein drained into the femoral vein. The embryological and clinical correlations are discussed.

Keywords: femoral artery, femoral vein, profunda femoris artery, great saphenous vein

Singapore Med J 2010; 51(1): e3-e5

INTRODUCTION

The femoral artery, also known as the common femoral artery, is a continuation of the external iliac artery deep to the inguinal ligament. Its largest branch is the profunda femoris artery, or the deep femoral artery, which arises 3.5 cm distal to the inguinal ligament from the lateral side. The femoral artery (common) continues as the popliteal artery after passing through an opening at the insertion of the adductor magnus muscle. The proximal part of the artery and the femoral vein remain within the femoral sheath, and the vein is placed medial to the artery. The femoral vein then runs posterior to the artery, up to the apex of the femoral triangle. The relationship of the femoral vessels in this region is presumed to be constant, except when the femoral vein remains on the medial side of the artery throughout its course in the thigh, or when it is doubled, especially in the adductor canal.⁽¹⁾ The long saphenous

vein, the longest superficial vein in the body, ends in the femoral vein, which is a short distance away from the inguinal ligament after passing through the saphenous opening.⁽²⁾

CASE REPORT

A routine dissection in undergraduate teaching of an intact formaldehyde-preserved cadaver of a 42-year-old Indian man from West Bengal revealed a rare pattern of relationship between the femoral vessels on both sides. The femoral artery crossed the femoral vein deep to the inguinal ligament, such that the artery was lying superficial to the vein at the base of the femoral triangle. The profunda femoris artery was seen lying lateral, and the great saphenous vein medial, to the femoral vessels in the triangle. The inguinal ligament was dissected and then partially cut to trace the upper extent (Fig.1). It revealed that the profunda femoris artery was arising from the femoral artery deep to the inguinal ligament. The great saphenous vein, after passing through the saphenous opening at its usual location, terminated into the femoral vein deep to the inguinal ligament. The tributaries of the great saphenous vein in the triangle were positioned in the usual manner (Fig. 2). The arteria profunda femoris gave rise to its usual branches in addition to the superficial circumflex iliac artery. The superficial epigastric, and the superficial and deep external pudendal arteries were arising from the femoral artery. The femoral nerve and its branches maintained a normal relationship with the vessels.

DISCUSSION

Femoral vein catheterisation becomes necessary when there is no visible peripheral vein for cannulation or when rapid access to a large vein is needed. This is done even in children for various procedures, such as ventriculoperitoneal shunt, as reported by Shenoy et al.⁽³⁾ As the femoral vein has a constant relationship with the medial side of the femoral artery just below the inguinal ligament, it can be easily cannulated there.⁽⁴⁾ Hughes et al, while investigating the relationship between the femoral vessels using ultrasonography, found variations in the crossing between the femoral vessels, and hence, opined that percutaneous access to

Department of Anatomy, Calcutta National Medical College, 32 Gorachand Road, Park Circus, Kolkata 700014, West Bengal, India

Bandyopadhyay M, MBBS, MS
Associate Professor

Biswas S, MBBS, MS
Assistant Professor

Roy R, MBBS, MS
Professor

Correspondence to:
Dr Manimay Bandyopadhyay
Tel: (91) 94 3337 9645
Fax: (91) 03 322 843 582
Email: manimay_bandyopadhyay@yahoo.co.in

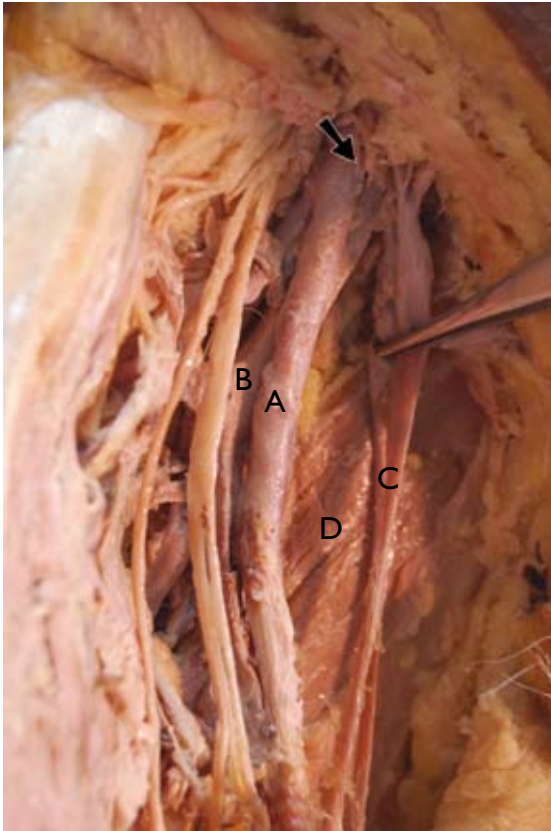


Fig.1 Photograph shows the femoral artery crossing the femoral vein (A) just below the inguinal ligament and great saphenous vein (B), and draining into the femoral vein just deep to the inguinal ligament (C). A part of the inguinal ligament has been resected. The arrow shows the lower limit of the inguinal ligament before the resection. D shows the adductor longus.

the femoral vessels should ideally be undertaken just below the inguinal ligament.⁽⁵⁾ However, in our case, as the femoral vein was positioned deep to the artery just below the inguinal ligament, it would have resulted in failure of the procedure or an arteriovenous fistula. This kind of relationship has not been frequently reported, except by Forty, and Smith and Dimitri.^(6,7) In both of these reports, the drainage site of the great saphenous vein and the origin of the arteria profunda femoris were almost classical. Forty, while performing profundoplasty in a claudication case, found the femoral artery lying medial to the vein. He further reported that the profunda femoris artery crossed the femoral vein superficially after arising from the femoral artery below the inguinal ligament.⁽⁶⁾ Smith and Dimitri, while operating in the femoral region during saphenofemoral ligation, found the superficial femoral artery lying medial to the femoral vein.⁽⁷⁾

A spectrum of variations in the origin of the profunda femoris has been reported.^(1,8-10) Quain found that in one out of 431 (0.23%) cases, the profunda femoris artery started from the femoral artery just

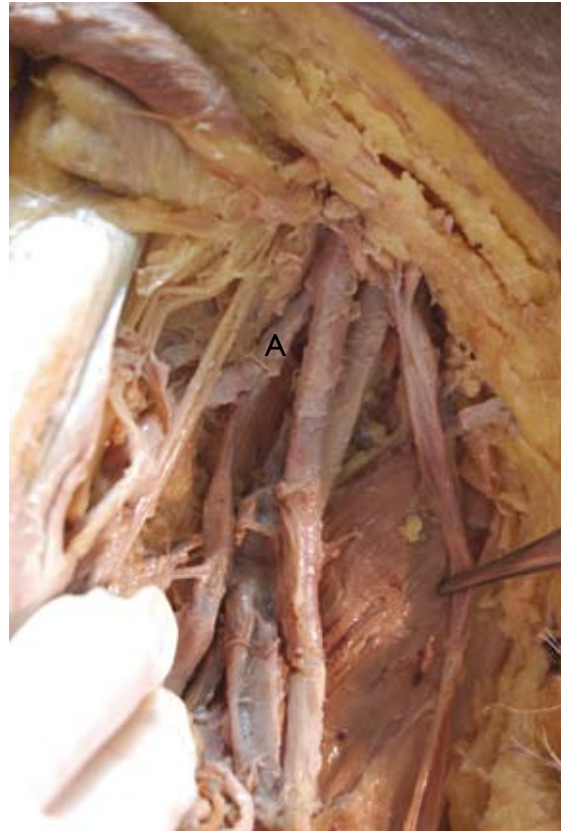


Fig.2 Photograph shows the arteria profunda femoris originating from the femoral artery just below the inguinal ligament (A).

above the inguinal ligament, in seven cases (1.6%), it started just deep to the inguinal ligament, and in 13 cases (3.01%), it started within half an inch below the ligament.⁽¹⁾ Sahin et al reported a case where the deep femoral (profunda femoris) artery originated from the femoral artery on the medial side and ultimately crossed deep to the vein to enter the deep part of the thigh.⁽⁸⁾ Pai et al presented a case where the arteria profunda femoris originated from the femoral artery as the first branch, 1.2 cm below the inguinal ligament, but this was accompanied by high termination of the abdominal aorta, a normal relationship between the femoral vessels and a normal site of drainage of the great saphenous vein.⁽⁹⁾ In our case, the variation in the relationship of the femoral vessels was accompanied by an origin of the profunda femoris artery just deep to the inguinal ligament. Since the profunda femoris artery started just deep to the inguinal ligament, it indicates an absence of any length of the common femoral artery. Knowledge of the site of origin of the profunda femoris artery helps in avoiding iatrogenic femoral arteriovenous fistulas or severe secondary haemorrhage when performing a femoral arterial puncture.⁽¹¹⁾ It can also prevent undue complications in various open procedures. Wolf and Brittenden emphasised the importance of proper

dissection and delineation of the saphenofemoral junction for successful varicose vein surgery.⁽¹²⁾ This would have been difficult in our case, as the usual site of incision of the skin would not have exposed the saphenofemoral junction, which was lying deep to the inguinal ligament. This case demonstrates the importance of the use of angiography before any blind femoral vessel cannulation, varicose vein surgery or femoral arteriotomy. Developmentally, the femoral artery starts developing from the external iliac artery when the embryo is 14 mm in size.⁽¹¹⁾ The alteration of the relationship between the femoral vessels might have started at that stage. The final mature arterial pattern in the femoral region is determined by the blood flow through the different channels of the rete pelvicum and rete femorale. This may be the reason for the higher origin of the arteria profunda femoris and the higher termination of the great saphenous vein.^(8,13,14)

REFERENCES

1. Quain R. Anatomy of the Arteries of the Human Body. London: Taylor & Walton, 1844: 476-8.
2. Williams A, Newell RL. Pelvic girdle, gluteal region and hip joint. In: Standring S, ed. Gray's Anatomy. 39th ed. Philadelphia: Elsevier, 2005:1447-8.
3. Shenoy V, Rao S, Pai M, Naidu C. Difficult femoral vein catheterization - a case report. Indian J Anaesth 2004; 48:231-2.
4. The lower limb. In: Snell RS. Clinical Anatomy for Medical Students. 7th ed. Philadelphia: Lippincott Williams & Wilkins, 2004: 669.
5. Hughes P, Scott C, Bodenham A. Ultrasonography of the femoral vessels in the groin: implications for vascular access. Anaesthesia 2000; 55:1198-202.
6. Forty J. Anomalous relationship between femoral artery and vein: a case report. Clin Anat 1990; 3:195-8.
7. Smith RA, Dimitri SK. Case report: a rare orientation of femoral artery and vein. EJVES Extra 2006; 12:66-7.
8. Sahin B, Uzun A, Emirzeoglu M, Kosif R, Bilgic S. A deep femoral artery passing in front of the femoral vein. Folia Morphol (Warsz) 2003; 62:143-6.
9. Pai MM, Prabhu LV, Prakash, Nayak V. Iliofemoral arterial malformation. Braz J Cardiovasc Surg 2006; 21:472-5.
10. Bergman RA, Afifi AK, Miyauchi R. Profunda femoris artery. In: Illustrated Encyclopedia of Human Anatomic Variation: Opus II: Cardiovascular System: Arteries: Lower Limb. Available at: www.anatomyatlases.org/AnatomicVariants/Cardiovascular/Text/Arteries/ProfundaFemoris.shtml. Accessed February 10, 2010.
11. McMinn RMH, ed. Lower limb. In: Last's Anatomy: Regional and applied. 9th ed. London: Churchill Livingstone. 1994: 155-6.
12. Wolf B, Brittenden J. Surgical treatment of varicose veins. J R Coll Surg Edinb 2001; 46:154-8.
13. Greebe J. Congenital anomalies of the iliofemoral artery. J Cardiovasc Surg (Torino) 1977; 18:317-23.
14. Sañudo JR, Roig M, Rodrigues A, Ferreira B, Domenech JM. Rare origin of the obturator, inferior epigastric and medial circumflex femoral arteries from a common trunk. J Anat 1993; 183:161-3.