

# The first case of Silver-Russell syndrome accompanied by linea alba hernia in China

Wong K F, Wong W W, Li B X, Song Y Z

## ABSTRACT

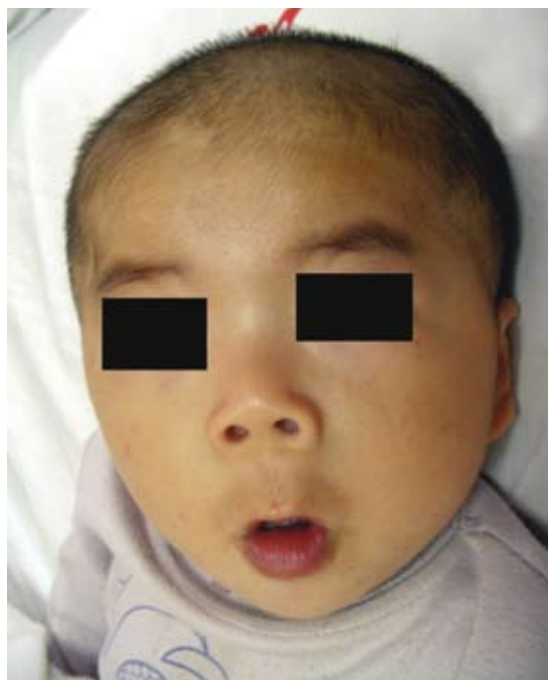A 10-month-old Chinese boy presented with delayed motor development for seven months. Blood and biochemistry investigations revealed no abnormalities. The physical examination showed poor postnatal growth (below  $-2$  standard deviation from the mean at diagnosis), preservation of the occipitofrontal head circumference with delayed closure of the anterior fontanel, classical triangular facial phenotype, asymmetry of the lower extremities and other characteristic features that fulfil the diagnostic criteria of Silver-Russell syndrome clinically. As PubMed and web searches revealed no similar findings, we believe that this may be the first case of Silver-Russell syndrome with linea alba hernia and pes varus reported in China, and possibly the world. The genetic deficit responsible for this case is still under investigation.

**Keywords:** Silver-Russell syndrome, motor developmental delay, delayed closure of anterior fontanel, linea alba hernia, pes varus

*Singapore Med J 2010;51(1):e9-e11*

## INTRODUCTION

Silver-Russell syndrome (SRS) is a heterogeneous genetic disorder. The mode of inheritance is variable, with sporadic cases in the literature described.<sup>(1)</sup> From the heterogeneous presenting features to the patients' radiographs, no single finding is pathognomonic,<sup>(2)</sup> and the whole picture is identified as SRS. The five core clinical diagnostic criteria are: (1) intrauterine retardation, usually with a birth weight  $\leq -2$  standard deviation (SD) from the mean; (2) poor postnatal growth ( $\leq -2$  SD from the mean at diagnosis); (3) preservation of the occipitofrontal head circumference; (4) classic facial phenotype; and (5) asymmetry (especially of the extremities). Due to the clinical and genetic heterogeneities of this syndrome, patients whose features fulfil four of these five criteria could be clinically diagnosed with SRS. The presence of feeding



**Fig. 1** Photograph shows a broad forehead tapering to a micrognathic jaw with a distinctive triangular face and down-curving mouth corners.

difficulties may be an additional diagnostic feature in some cases.<sup>(3,4)</sup>

## CASE REPORT

A 10-month-old Chinese male infant was transferred to our unit when he was suspected to have delayed motor development of more than seven months duration. His parents were unaware of the significance when the infant could not hold his head upright at three months old. The infant was sent to a local hospital one month later for suspected poor developmental progress and inability to roll independently. The cranial computed tomography result was normal. He was diagnosed with calcium deficiency and developmental delay, and was treated with supplements of vitamin D and calcium. There was no significant improvement in the infant, other than being able to hold his head steady in an upright position at seven months old. The patient was then transferred to a children's hospital one month later. No

Department of  
Pediatrics,  
First Affiliated  
Hospital,  
Jinan University,  
West 613,  
Huangpu Dadao Xi,  
Guangzhou 510632,  
Guangdong Province,  
China

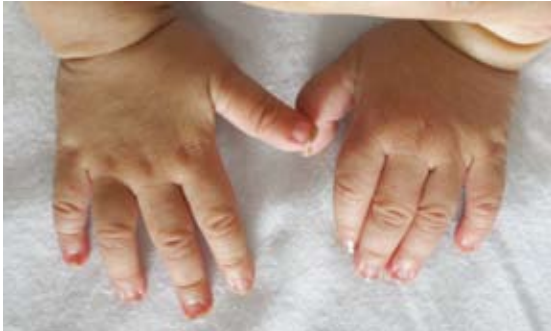Wong KF, MB  
Intern Physician

Wong WW, MB  
Intern Physician

Li BX, MB  
Paediatric Physician

Song YZ, MD  
Associate Chief,  
Professor and  
Programme Director

**Correspondence to:**  
Dr Wong Kiu Fung  
Tel: (86) 1509 990 9604  
Fax: (852) 25294030  
Email: wkfkelvin2004  
@yahoo.com.cn

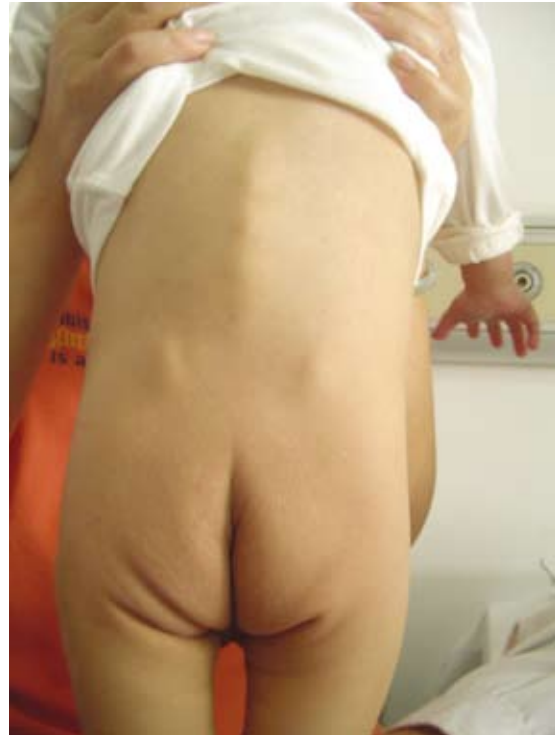

**Fig. 2** Photograph shows clinodactyly (inward curving) of the fifth fingers and maldevelopment of nails in both hands.

evidence of any specific metabolic disorder was found in the urinary gas chromatography-mass spectrometry analysis and the tandem mass spectrometry analysis of blood spots. The infant had earlier been diagnosed with motor developmental delay, but no specific treatment was initiated. He was then transferred to our hospital for advanced investigation because of his significant motor developmental delay. At ten months, he was still unable to crawl, sit unsupported, stand independently or grasp actively with the palmar grip. He had been sweating excessively since four months of age, often wetting his shirt and bedsheets at night. His urine was normal, but the faeces were often hard.

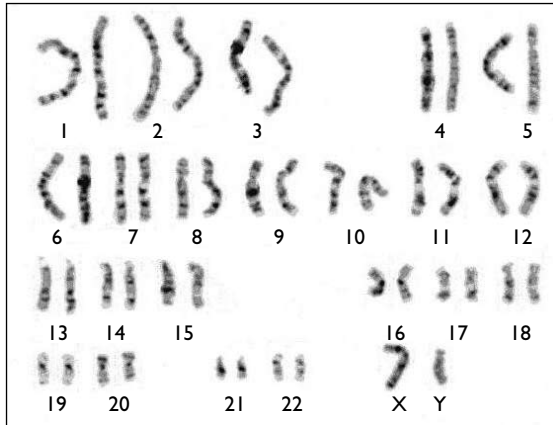
The maternal pregnancy history revealed a G2P2 pregnancy, a birth weight of 2.9 kg and vaginal delivery in a local hospital during the 39th gestational week. The figures for the height and head circumference were not obtained, and the parents denied any history of asphyxia resuscitation. Eczema had been occurring frequently since two months of age, especially on the neck and buttocks, and hypersomnia had been suspected since birth. The infant was less responsive to external stimulus, and often had to be woken up for feeding. He lacked oral sucking strength and often regurgitated during breastfeeding, so adequate food supplements had to be given. Two weeks before presentation, breastfeeding was replaced completely by formula feeding. The infant was unable to smile responsively, feed himself by grasping food or use monosyllabic consonants, which revealed a language delay. The parents were non-consanguineous, and their elder son was in good health. The patient was believed to be the only case in the family as no similar family history was known.

The physical examination revealed a male infant of weight 7 kg (below  $-2$  SD from the mean of the same age and gender), height 69 cm, head circumference 44 cm, crown-rump length 44 cm and chest circumference 41 cm. The infant was conscious and generally cooperative during the examination. Eczema, with an



**Fig. 3** Photograph shows kyphosis and asymmetrical lower extremities with prominent left gluteal folds.

area of 2 cm  $\times$  4 cm, was found on the neck. Eczema with desquamation was also found on the wasting buttocks. There was a café-au-lait (coffee-with-milk) birth mark on the abdominal wall measuring 2 cm  $\times$  2 cm. The broad forehead, tapering to a micrognathic jaw, showed a distinctive triangular face (Fig.1). The anterior fontanel measured 1.5 cm  $\times$  1.5 cm. The patient had a pair of low-set ears, slight right blepharoptosis, a flat and prominent nasal bridge with extroversion of the bilateral nostrils. The patient had a micrognathic jaw and two milk teeth with a wide gap, and liked to protrude his tongue, showing down-curving mouth corners. The chest appeared to be flat, and mild coarse breath sounds without rales or rhonchi were heard. Cardiac auscultation revealed normal heart sounds without any detectable murmur. A soft abdomen and a longitudinal bulging were detected at the midline line, above the umbilicus, and the abdominal wall spacing could be palpated. Auscultation revealed normal bowel sounds. Clinodactyly (inward curving) of the fifth fingers and maldevelopment of the nails were found (Fig. 2). Kyphosis and asymmetrical lower extremities with prominent left gluteal folds were also observed (Fig. 3), along with pes varus on both sides. There was normal range of movement in all the extremities, but hypotonia, especially of the legs, was observed. The patellar reflex was absent, and an undescended right testis was found. There was no abnormality found in



**Fig. 4** Karyotype analysis shows a normal 46,XY karyotype, ruling out the possibility of 18p- syndrome.

the routine blood examination or the biochemical test. Due to the atypical findings of linea alba hernia and pes varus, 18p- syndrome was suspected. However, the karyotype analysis revealed no abnormalities (Fig. 4). Consequently, the final clinical diagnosis was SRS with linea alba hernia and pes varus.

## DISCUSSION

SRS was reported independently by Silver et al in 1953 and by Russell in 1954. The prevalence of SRS in western countries was one in 3000 to one in 100,000,<sup>(3)</sup> but there was no such epidemiological data available in China. Apart from the five core clinical diagnostic criteria, SRS patients may present with additional features, such as down-curving mouth corners, clinodactyly, poor head

control, global developmental delay, increased sweating during infancy, poor feeding habits, gastroesophageal reflux, anorexia and other gastrointestinal presentations, which are further evidences for our diagnosis.<sup>(1)</sup> The patient in our case fulfilled all the major diagnostic criteria except for intrauterine retardation, and together with other documented characteristics, the clinical diagnosis of SRS was very likely. The incidence of SRS in China is sporadic, and the condition is mainly diagnosed in older children,<sup>(5-7)</sup> with none diagnosed during infancy so far. Furthermore, our case was accompanied by linea alba hernia and pes varus, which, up till now, has never been reported. The specific genetic deficit which leads to the presenting features in SRS is still under investigation.

## REFERENCES

1. Abu-Amero S, Monk D, Frost J, et al. The genetic aetiology of Silver-Russell syndrome. *J Med Genet* 2008; 45:193-9.
2. Herman TE, Crawford JD, Cleveland RH, Kushner DC. Hand radiographs in Russell-Silver syndrome. *Pediatrics* 1987; 79:743-4.
3. Galli-Tsinopoulou A, Emmanouilidou E, Karagianni P, et al. A female infant with Silver Russell syndrome, mesocardia and enlargement of the clitoris. *Hormones* 2008; 7:77-81.
4. Price SM, Stanhope R, Garrett C, Preece MA, Trembath RC. The spectrum of Silver-Russell syndrome: a clinical and molecular genetic study and new diagnostic criteria. *J Med Genet* 1999; 36:837-42.
5. Zhang DH, Chen CY, Yang ZC. [A case of Silver-Russell syndrome]. *Orthop J China* 2002; 9:260. Chinese.
6. Qui BP, Huang SK, Chen CY. [Russell-Silver syndrome in a case]. *Zhonghua Er Ke Za Zhi* 2006; 44:147. Chinese.
7. Wang YH, Zhou LN. [A case report of Silver-Russell syndrome]. *Zhongguo Dang Dai Er Ke Za Zhi* 2008; 10:757-8. Chinese.