

Cystojejunostomy for non-parasitic hepatic cyst with biliary communication

Jain S K, Vindal A, Basra B K, Kaza R C M

ABSTRACT

Non-parasitic hepatic cysts containing bile are rare entities and pose a challenge in surgical management as they cannot be managed by simple de-roofing. The biliary communication to the cyst cavity should either be closed meticulously, or these cysts should be managed by an internal drainage procedure such as cystoenterostomy. We report a 17-year-old Indian girl, in which such a cyst was treated by cystojejunostomy.

Keywords: biliary cyst, cystoenterostomy, hepatic cyst, non-parasitic cyst

Singapore Med J 2010;51(2):e27-e29

INTRODUCTION

With the advent of advances in imaging, up to 5% of the population have been found to have one or more liver cysts, with the incidence rising with age. These cysts are normally asymptomatic and are detected incidentally during abdominal imaging. Patients with larger cysts tend to have pain as the presenting symptom.⁽¹⁾ We present a non-parasitic simple hepatic cyst with biliary communication that was treated with a Roux-en-Y cystojejunostomy.

CASE REPORT

A 17-year-old Indian girl presented with constant, dull aching and non-colicky pain, radiating to the right shoulder for the last three months. The pain was not associated with any aggravating or relieving factors, and there was no history of fever, jaundice or loss of appetite and weight. The patient had previously been treated at another hospital for hydatid disease of the liver, and was prescribed long-term albendazole therapy. However, she developed bullous toxic epidermal necrolytic skin lesions while on this therapy and requested for a dermatological opinion. After being treated for the skin lesions in the dermatology department, the patient was referred to the surgery outpatient clinic. On examination, she was found to have no icterus. The liver was palpable 4 cm below the right costal margin in the midclavicular line, and had a smooth surface and well-defined margins. The chest radiograph showed an elevated right hemidiaphragm.

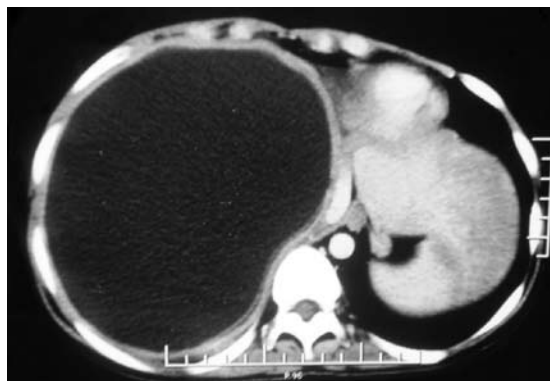

Fig. 1 Contrast-enhanced axial CT image of the abdomen shows a large hypodense lesion involving almost the whole of the right lobe of the liver and abutting the right hemidiaphragm. The cyst wall and its contents are non-enhancing.

The rest of the physical examination was unremarkable.

The routine haematological and biochemical parameters, including the liver function tests, were within normal limits. Hydatid serology was negative, and the blood carcinogenic embryonic antigen and alpha-fetoprotein (AFP) levels were within normal limits. Abdominal ultrasonography showed a large anechoic cystic lesion, measuring 16.5 cm × 16 cm in size, located in the right lobe of the liver abutting the diaphragmatic undersurface. Contrast-enhanced computed tomography (CT) of the abdomen showed a large, thin-walled cystic lesion in the right lobe of the liver measuring 16.3 cm × 15.5 cm × 14.2 cm, which was occupying segments VII and VIII, abutting the right hemidiaphragm and projecting into the thoracic cavity (Fig. 1). There was no evidence of cyst wall calcification, daughter cysts, laminated membranes or hydatid sand. No enhancement of the cyst wall was seen after the injection of the intravenous contrast agent.

After ruling out a hydatid aetiology of the cyst on serology and imaging, a needle aspiration of the cyst was carried out. The results showed clear acellular fluid with no evidence of malignant or atypical cells, or parasites. The hydatid serology of the cyst fluid was negative. The bacteriological culture of the fluid was also found to be sterile. Upon confirmation of its non-parasitic nature, the hepatic cyst was drained using a pigtail catheter under ultrasonography guidance. Initially, 1,200 ml of clear fluid was drained from the cyst. Three days after the

Department of Surgery,
Maulana Azad Medical College and Lok Nayak Hospital, Bahadur Shah Zafar Marg, New Delhi 110002, India

Jain SK MS, FRCS
Professor

Vindal A, MS, DNB, MRCSE
Senior Resident

Basra BK MS
Senior Resident

Kaza RCM, MS
Professor

Correspondence to:
Dr Sudhir Kumar Jain
Tel: (91) 11 2027 7077
Fax: (91) 11 2027 7077
Email: sudhirkumar11@gmail.com

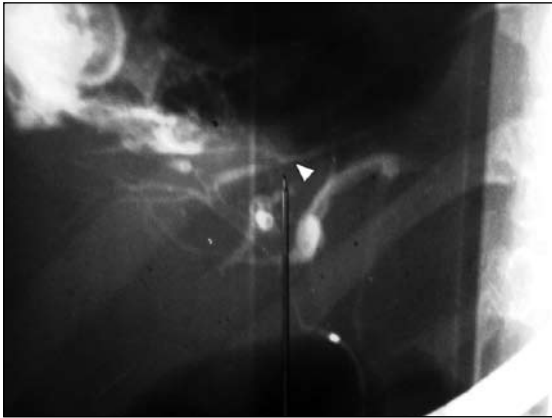

Fig. 2 ERCP shows extravasation of the contrast agent from one of the branches of the right hepatic ducts (arrowhead). The extravasated contrast is seen to outline the cyst in the upper left corner of the radiograph.

insertion of the pigtail catheter, the nature of the fluid changed from clear to bilious. The average daily output was 300–400 ml. The catheter was kept *in situ* to allow free drainage of the cyst in order to enable spontaneous closure of the fistula. However, the output did not decrease after two weeks.

Endoscopic retrograde cholangiopancreatography (ERCP) was performed to determine the cause of the persistent biliary fistula, and the results revealed an extravasation of the contrast medium from a branch of the right hepatic duct into the cyst cavity (Fig. 2). Stenting of the hepatic duct across the site of the fistulous leak was performed, but there was still no decrease in bile output.

Due to the persistent biliary drainage, an open surgery was scheduled for the patient four weeks after the pigtail insertion. The exploration revealed a large cyst of approximately 15 cm × 15 cm in size, located on the posterosuperior aspect of the liver, in contact with the undersurface of the diaphragm. Dense adhesions were present between the liver and diaphragm, which were carefully separated to expose the surface of the cyst. The bile leak was seen from inside the cyst cavity at the site of the catheter entry. The right lobe of the liver was mobilised inferiorly, and the cyst-bearing posterosuperior surface of the liver was exposed. The cyst was opened, and the contents were aspirated. A careful inspection of the inner aspect of the cyst was then performed. There were no solid components, thickening or papillary projections in the wall of the cyst. There was also no evidence of any daughter cysts on the wall or in the cavity of the cyst. A biopsy was taken from the margin of the cyst wall for histopathological examination. A retrocolic Roux-en-Y loop of jejunum was fashioned in the usual manner and anastomosed to the cyst wall (Fig. 3).

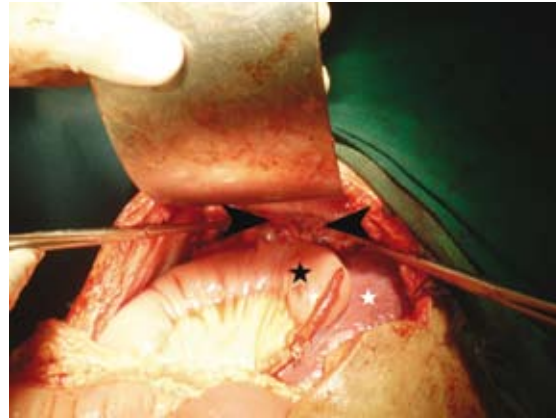


Fig. 3 Intraoperative photograph of the patient shows the completed cystojejunostomy, with the cyst wall (arrowheads), liver (white star) and Roux-en-Y loop of jejunum (black star).

The postoperative period was uneventful, and the patient was discharged on the 10th postoperative day. During the one-year follow-up at the clinic, the patient remained well with no sign of cholangitis. Magnetic resonance (MR) imaging at the six-month and one-year postoperative follow-up showed a marked decrease in the size of the cyst. However, as expected of a communicating cyst, it did not disappear completely.

DISCUSSION

The symptoms of hepatic cysts are not uniform, but they are usually the result of pressure effects, with pain predominating in both simple cysts and polycystic liver disease.⁽¹⁾ The displaced liver or enlarged cyst may compress the stomach and duodenum, causing nausea, vomiting and early satiety.^(1,2) Laparoscopic deroofting and percutaneous sclerosing therapy have emerged as new modalities of treatment in the management of these cysts.⁽³⁾ A uniform management of this entity has not been clearly defined, and multiple therapeutic options have been described. These procedures range from non-surgical methods, such as a simple needle aspiration and aspiration with an injection of sclerosing agents,⁽³⁾ to surgical intervention.^(4,5) Surgery includes external drainage of the cyst via tube cystostomy, internal drainage into a Roux-en-Y loop of jejunum and deroofting procedures.^(4,5) Laparoscopic deroofting of the cyst has been recommended as a safe and reliable procedure, but its role is controversial in cases where there is biliary communication with the cyst.^(6,7)

It is difficult to diagnose biliary communication preoperatively, and this can also be missed at the time of surgery. A missed biliary communication can prove to be catastrophic and may result in biliary peritonitis if the hepatic cyst is treated by simple deroofting.⁽⁸⁾ For this

reason, deroofing has been considered a contraindication for cysts with cystobiliary communication, for which cystojejunostomy has often been used.⁽⁸⁾ In cases where the cyst fluid is bile-stained and where a communication with the biliary tree is suspected, a cystoenteric anastomosis using a Roux-en-Y jejunal loop is indicated. Cystojejunostomy has been recommended by Longmire et al as an excellent alternative procedure for a cyst with cystobiliary communication.⁽⁹⁾ There is a possibility of developing sepsis and cholangitis if the previously sterile cyst becomes infected with enteric organisms after the operation.^(4,5,10) Intraperitoneal drainage in the abovementioned cases is not advisable as it usually results in the formation of a postoperative biliary collection. However, the construction of a Roux-en-Y cystoenterostomy carries a considerable risk of infectious complications and additional surgical demands, as reported in various studies.^(4,5) In the study conducted by Tocchi et al, all the patients who underwent a cystojejunostomy developed relapsing cholangitis which required repeated antibiotic treatments, while one patient required hepatic resection due to septic complications one year later.⁽⁴⁾

In the present case, the patient underwent cystojejunostomy more than two years ago, and has been on regular follow-up. To date, she has not developed any postoperative complications and is symptom-free. Although closure of the bile ductule communication has been advocated by Masatsugu et al,⁽⁷⁾ a formal closure of the bile ductules in the present case was not performed as the tissue inside the cyst wall was highly friable and did not hold sutures. However, it did not lead to

any complications, and the patient made an uneventful recovery. She has been symptom-free and complication-free for more than two years postoperatively. From our experience in this index case, we advocate a simple Roux-en-Y cystojejunostomy as an adequate procedure for the treatment of simple bile containing hepatic cysts.

REFERENCES

1. Lai EC, Wong J. Symptomatic non-parasitic cysts of the liver. *World J Surg* 1990; 14:452-6.
2. Caremani M, Vincenti A, Benci A, Sassoli S, Tacconi D. Ecographic epidemiology of non-parasitic hepatic cysts. *J Clin Ultrasound* 1993; 21:115-8.
3. Martin IJ, McKinley AJ, Currie EJ, Holmes P, Garden OJ. Tailoring the management of nonparasitic liver cysts. *Ann Surg* 1998; 228:167-72.
4. Tocchi A, Mazzoni G, Costa G, et al. Symptomatic nonparasitic hepatic cysts: options for and results of surgical management. *Arch Surg* 2002; 137:154-8.
5. Koperna T, Vogl S, Satzinger U, Schulz F. Nonparasitic cysts of the liver: results and options of surgical treatment. *World J Surg* 1997; 21:850-5, discussion 854-5.
6. Klingler PJ, Gadenstätter M, Schmid T, Bodner E, Schwelberger HG. Treatment of hepatic cysts in the era of laparoscopic surgery. *Br J Surg* 1997; 84:438-44.
7. Masatsugu T, Shimizu S, Noshiro H, et al. Liver cyst with biliary communication successfully treated with laparoscopic deroofing: a case report. *JSLs* 2003; 7:249-52.
8. Salemis NS, Georgoulis E, Gourgiotis S, Tsohataridis E. Spontaneous rupture of a giant non parasitic hepatic cyst presenting as an acute surgical abdomen. *Ann Hepatol* 2007; 6:190-3.
9. Longmire WP Jr, Mandiola SA, Gordon HE. Congenital cystic disease of the liver and biliary system. *Ann Surg* 1971; 174:711-26.
10. Litwin DE, Taylor BR, Langer B, Greig P. Nonparasitic cysts of the liver. The case for conservative surgical management. *Ann Surg* 1987; 205:45-8.