

Variations of the origin and branches of the external carotid artery in a human cadaver

Thwin S S, Soe M M, Myint M, Than M, Lwin S

ABSTRACT

We report a unique variation in the origin and branches of both the left and right external carotid artery (ECA) found during the dissection of a human cadaver. Knowledge of possible anatomical variations of the ECA is especially important in facio-maxillary and neck surgeries. Surgeons need to be aware of the possibility of encountering such variations, as they may lead to difficulties in differentiating between the external and internal carotid arteries, and in identifying the branches and origins. This knowledge is also important for radiologists in the image interpretation of the face and neck regions.

Keywords: ascending pharyngeal artery, external carotid artery, linguofacial trunk, occipito-auricular trunk, superior thyroid artery

Singapore Med J 2010;51(2):e40-e42

INTRODUCTION

Knowledge of the variations of the external carotid artery (ECA) is essential for facio-maxillary surgery and surgery of the neck. It is important for surgeons to differentiate between the ECA and the internal carotid artery (ICA) to ensure that the artery being ligated is the ECA, as the ligation of the ICA can result in hemiparesis. Equally important is the awareness of variation, such as the bilateral or unilateral absence of the external carotid arteries, and the understanding of the abundant anastomoses between the branches of the ECA and ICA, which provide the collateral pathways for cerebral perfusion when significant disease is present in the ICA. This knowledge can help radiologists to understand and interpret carotid system imagings, which is essential for cerebral angiography. We report a rare variation involving both the common carotid artery (CCA) and ECA on both sides.

CASE REPORT

Unique anatomical variations involving both the left and right ECA were found during the dissection of a human

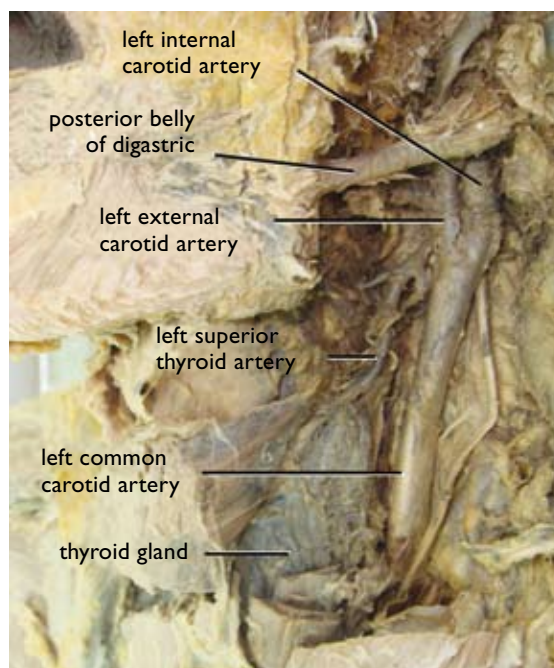


Fig. 1 Photograph shows high bifurcation of the left common carotid artery.

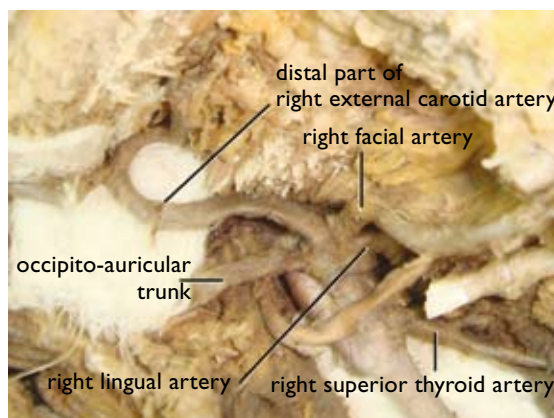


Fig. 2 Photograph shows high origin of the right superior thyroid artery and simultaneous branching of the right ECA into the lingual, facial, occipito-auricular and distal part of the ECA.

cadaver. These variations included: a relatively high bifurcation of the CCA on both sides, and on the right side at the 2nd cervical vertebral (CV2) level and left side at the 3rd cervical vertebral (CV3) level (Fig.1);

Department of Anatomy,
Universiti Kuala Lumpur Royal College of Medicine Perak,
3 Jalan Greentown,
Ipoh 30450,
Malaysia

Thwin SS, MBBS,
MMedSc
Associate Professor

Myint M, MBBS,
MMedSc
Senior Lecturer

Than M, MBBS,
MMedSc
Professor

Lwin S, MBBS,
MMedSc
Senior Lecturer

Department of Public Health

Soe MM, MBBS,
DPTM, MPH
Associate Professor

Corresponding to:
Dr San San Thwin
Tel: (60) 165 577 572
Fax: (60) 5 243 2636
Email: santhwin@yahoo.com

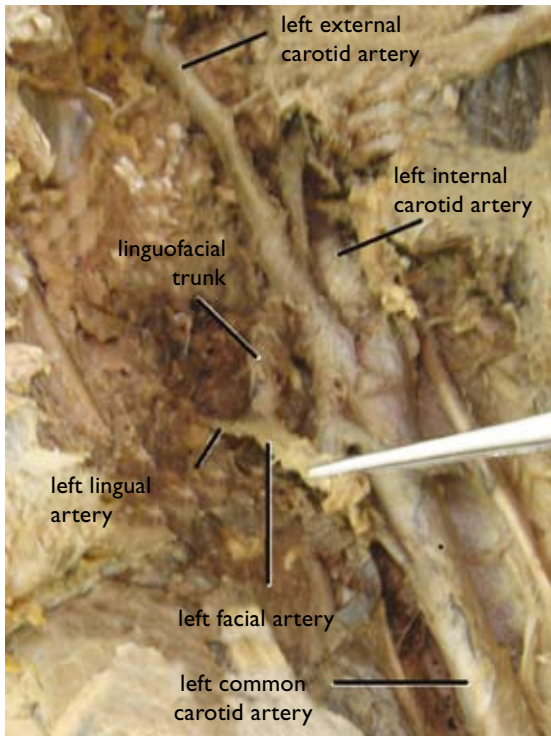


Fig. 3 Photograph shows a common linguofacial trunk on the left side.

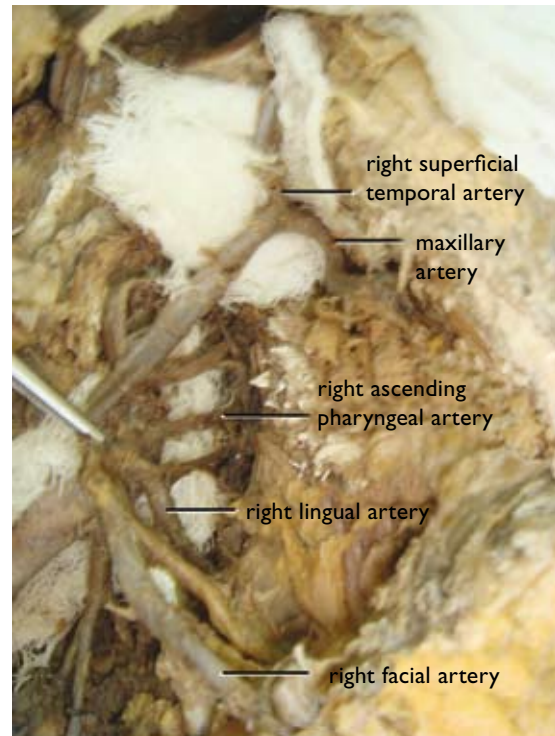


Fig. 5 Photograph shows high origin of the right ascending pharyngeal artery above the lingual artery.

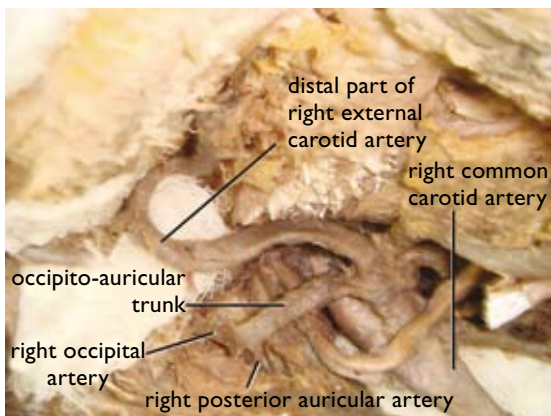


Fig. 4 Photograph shows high bifurcation of the common carotid artery and the presence of the occipito-auricular trunk on the right side.

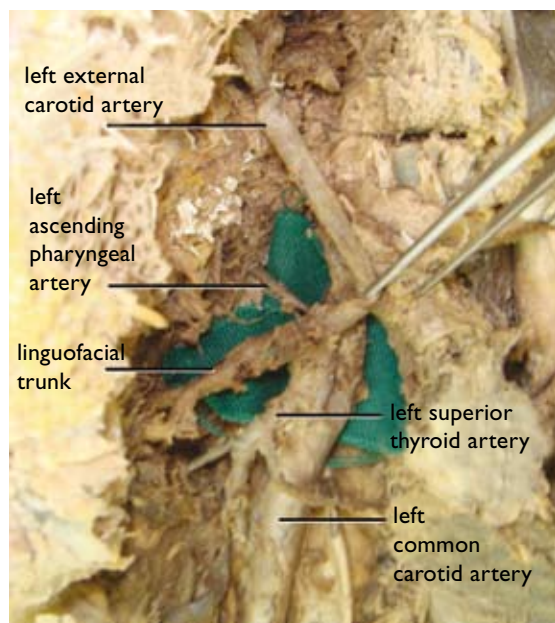


Fig. 6 Photograph shows high origin of the left ascending pharyngeal artery at the level of the linguofacial trunk.

high origin of the right superior thyroid artery at the level where the ECA starts (Fig. 2); simultaneous branching of the right ECA into the lingual, facial, occipito-auricular and distal part of the ECA, after giving off the superior thyroid artery (Fig. 2); common linguofacial trunk on the left side (Fig. 3); common occipito-auricular trunk on the right side (Fig. 4); and high origin of the ascending pharyngeal arteries on both sides, lying medial to the ECA (Figs. 5 & 6).

DISCUSSION

The CCA usually bifurcates at the level of the 3rd cervical

vertebra (50% right side and 55% left side) and the 4th cervical vertebra (40% right side and 35% left side).^(1,2) In this case, a relatively high bifurcation of the CCA was found on the left side below the level of the hyoid bone (CV3), and on the right side, the bifurcation was at the level of the hyoid bone (CV2). Such variations in the bifurcation of the CCA are not uncommon. Bifurcations

as high as the hyoid bone or the styloid process and as low as the cricoid cartilage, or within 3.7 cm of its origin have previously been reported. Bifurcations of the CCA at the level of the 2nd cervical vertebra (hyoid bone) and at the 5th cervical vertebral level on the left side have been reported in 10% and 1% of the cases, respectively.⁽²⁾

The right ECA branches directly at its origin into the superior thyroid, lingual and occipital arteries, as well as into the distal part of the ECA.⁽²⁾ In the present case, the right ECA simultaneously branched into the lingual artery, facial artery, occipito-auricular trunk and the distal part of the ECA at the same level after giving off the superior thyroid artery. Zümre et al in their study on human foetuses found a linguofacial trunk in 20%, a thyro-lingual trunk in 2.5% and a thyro-linguofacial trunk in 2.5% of the human foetuses studied.⁽³⁾ In this case, a similar common linguofacial trunk was seen on the left side. A common occipito-auricular trunk dividing into the occipital and posterior auricular arteries was also observed, similar to that reported by Zümre et al in 12.5% of the human foetuses studied.⁽³⁾

Bannister et al reported that the ascending pharyngeal artery (APA) arose deep to other branches and near the commencement of the ECA.⁽⁴⁾ Sinnatamby also found that the APA arose at the commencement and deep to the ECA.⁽⁵⁾ According to Drake et al, the APA is the second and smallest branch arising from the posterior aspect of the ECA.⁽⁶⁾ However, in this case, the APA on both sides were found to arise at a higher level and from the medial aspect deep to the ECA. On the right side, the APA was seen to arise at the level of the linguofacial trunk, and on the left side it arose above the level of the lingual artery. Anil et al have also reported a variation of the right APA,

which was observed to be arising from the bifurcation of the CCA.⁽⁷⁾

Variations of the origin and branches of the ECA on both sides are rare findings and impart important knowledge that is especially useful for surgeons who operate on the face and neck regions, as well as for radiologists in the interpretation of imagings.

ACKNOWLEDGEMENTS

We would like to thank the Dean, Prof Dr Hashami, the Deputy Dean, Dato' Dr Shafie, Mr Thian, Mr Shamsul, and all the administrative and academic staff of Universiti Kuala Lumpur Royal College of Medicine Perak, Malaysia, for their strong support, as well as Mr Nizam, Mr Das and Mr Safian of the Anatomy Department for their assistance during the dissection.

REFERENCES

1. Poynter CWN. Congenital anomalies of the arteries and veins of the human body with bibliography. Lincoln: The University Studies of the University of Nebraska, 1992; 22:1-106.
2. Gluncic V, Petanjek Z, Marusic A, Gluncic I. High bifurcation of common carotid artery, anomalous origin of ascending pharyngeal artery and anomalous branching pattern of external carotid artery. *Surg Radiol Anat* 2001; 23:123-5.
3. Zümre O, Salbacak A, Çiçekcibaşı AE, Tuncer I, Seker M. Investigation of the bifurcation level of the common carotid artery and variations of the branches of the external carotid artery in human fetuses. *Ann Anat* 2005; 187:361-9.
4. Gabella G. Cardiovascular. In: Bannister LH, Berry MM, Collins P, et al, eds. *Gray's Anatomy*. 38th ed. Edinburgh: Churchill Livingstone, 1995: 1515-9.
5. Sinnatamby CS. *Last's Anatomy: Regional and Applied*. 11th ed. Edinburgh: Churchill Livingstone, 2006.
6. Drake RL, Vogl W, Mitchell AWM. *Gray's Anatomy for Students*. Toronto: Elsevier Churchill Livingstone, 2005.
7. Anil A, Turgut HB, Peker T, Pelin C. Variations of the branches of the external carotid artery. *Gazi Med J* 2000; 11:81-3.