

# Improvised external fixator device to restore motion in a neglected elbow dislocation

Gupta V, Gupta R, Yadav S

## ABSTRACT

**Neglected posterior dislocation of the elbow is a common problem in developing countries. One acceptable form of treatment is open reduction and transarticular Steinmann pin fixation. However, this leads to a stable but stiff elbow. We used an improvised external fixator after open reduction in two cases, which allowed for early mobilisation with adequate stability. This option can be considered when modern implants are not available.**

**Keywords: early mobilisation, external fixator, neglected elbow dislocation**

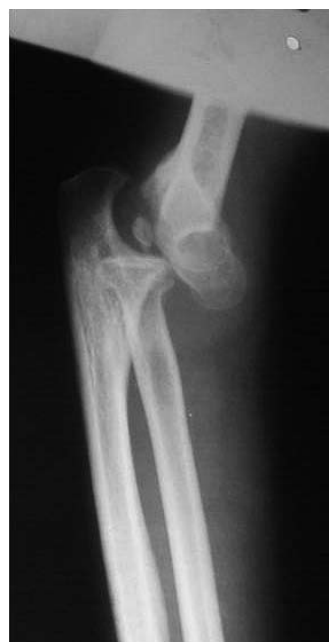*Singapore Med J 2010;51(4):e62-e65*

## INTRODUCTION

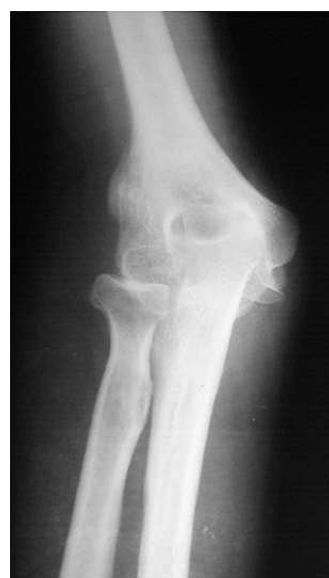Neglected posterior elbow dislocation, which is rare in the west, is occasionally seen in developing countries. The management of a dislocated elbow poses a challenge to an orthopaedic surgeon. Open reduction, followed by intraarticular Steinmann pin fixation, is the preferred method of management of an unreduced elbow after a period of three weeks. Intraarticular fixation hampers early mobilisation, resulting in a stable but stiff elbow. In our centre, we use an improvised external fixator assembly after open reduction that allows for early mobilisation while maintaining stability. This device maintains reduction of the joint and enables immediate elbow mobilisation, as well as encourages cartilage nutrition and growth. We applied this improvised fixator in two of our cases after achieving open reduction. Both patients regained a useful arch of motion within 6–8 weeks without any complications. This simple external fixator has a useful role to play in resource-constrained countries, where modern implants may not be available.

## CASE I

A 25-year-old male labourer presented with a neglected posterior elbow dislocation on the right side without any deficit of three months' duration (Figs. 1 & 2). The elbow was fixed at 15° of flexion with no further



**Fig. 1** Lateral radiograph shows the neglected elbow dislocation.



**Fig. 2** Anteroposterior radiograph shows the neglected elbow dislocation.

movement. Open reduction and V-Y lengthening of the triceps muscle were performed, followed by external fixator application (Fig. 3). Active and active-assisted

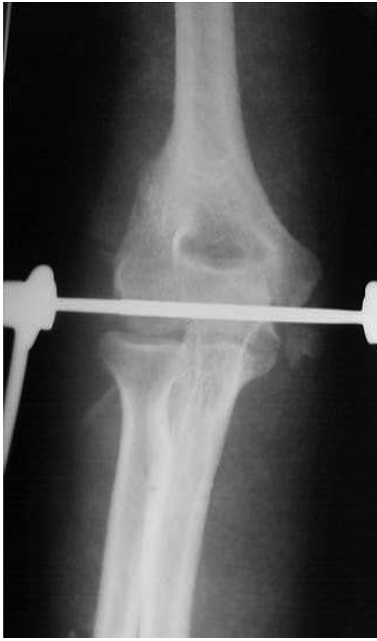Central Institute of  
Orthopaedics,  
Safdarjang Hospital  
and Vardhman  
Mahavir Medical  
College,  
New Delhi 110029,  
India

Gupta V, MS  
Assistant Professor

Gupta R, MS  
Orthopaedic Surgeon

Yadav S, MS  
Orthopaedic Surgeon

**Correspondence to:**  
Dr Vikas Gupta  
Tel: (91) 9810 2721 10  
Fax: (91) 9111 2616 3072  
Email: drvikas@hotmail.com



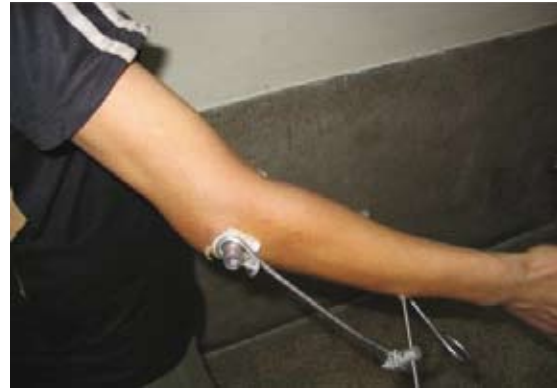**Fig. 3** Postoperative anteroposterior radiograph shows the improvised external fixator, with the lower humeral pin across the axis of rotation of the elbow connected to ulnar pins through the Bohler stirrup.

mobilisation was started on the third postoperative day. The range of movement at six weeks with the fixator was 15°–80° of elbow flexion (Figs. 4 & 5). The assembly was removed at eight weeks. The final range of movement achieved at 12 weeks was 10°–90° of elbow flexion and 10° of pronation and supination each. The patient was satisfied with the result and retained his pre-injury level of activity.

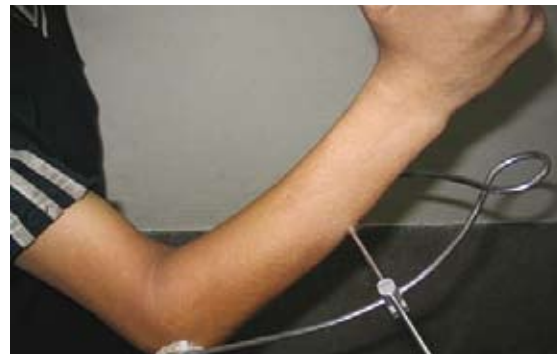## CASE 2

A 29-year-old woman presented after two-and-a-half months of unreduced posterior elbow dislocation on the left side with no neurovascular deficit. Her preoperative range of movement was 10°–20° flexion. Open reduction with V-Y triceps plasty was performed, followed by the application of the improvised external fixator. Active and active-assisted motion exercises were started on the third postoperative day. The fixator was removed at six weeks. At 12 weeks, the patient's range of movement was 5°–110° of elbow flexion, 20° of supination and 10° of pronation.

The surgery was performed under general anaesthesia, with the patient in the lateral decubitus position. The patient's arm was supported over a padded post that enables the manipulation of the elbow during surgery. The incision was sited over the posterolateral aspect of the elbow beginning at the midline, about 10 cm proximal to the olecranon. The incision was slightly curved laterally at the tip of the olecranon and continued



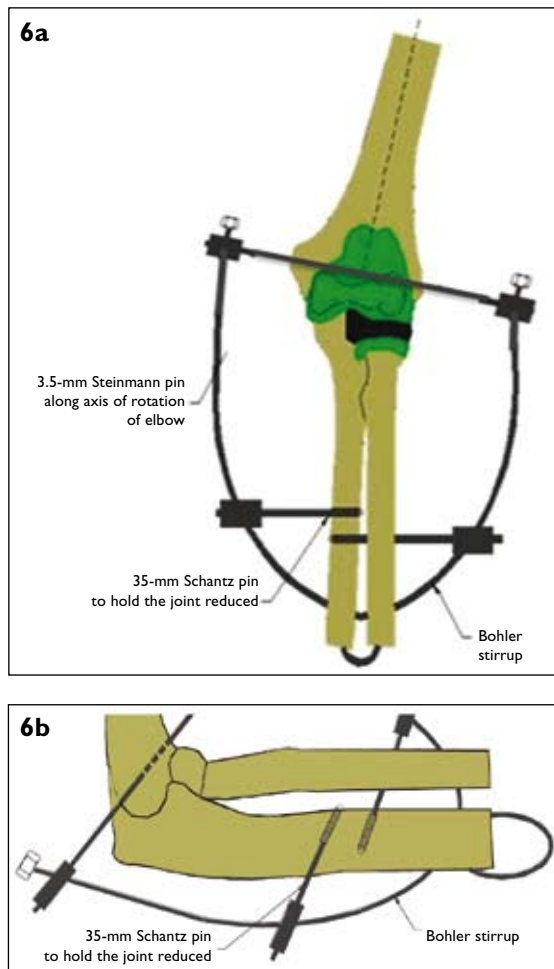
**Fig. 4** Photograph shows the elbow extension at six weeks post operation.



**Fig. 5** Photograph shows the elbow flexion at six weeks post operation.

distally for 5 cm in the forearm. The aponeurosis of the triceps was reflected distally in the form of an inverted V.<sup>(1)</sup> The distal humerus was freed of all muscular and capsular attachments by subperiosteal dissection. The ulnar nerve was then transported anteriorly and held with a facial sling. After an adequate release of the collateral ligaments around the condyles of the humerus, the joint was inspected and reduced.

The next step involved the application of the external fixator. The joint was held reduced, distracted by an assistant and maintained in 90° of flexion. A 3-mm Steinmann pin was then introduced from the medial side across the axis of rotation of the elbow (axis pin placement). The axis of rotation can be marked on the lateral aspect of the capitellum. A tubercle was present at the site of the origin of the lateral collateral ligament. This tubercle represents the geometric centre of curvature of the capitellum, which is the site of the flexion axis of the elbow. On the medial aspect of the distal humerus, the axis of rotation lies just anterior and inferior to the medial epicondyle. This pin was connected to the Bohler stirrup. Next, two half pins were inserted along the subcutaneous border of the distal ulna. These Schanz pins were adequately spaced to allow for better rotational control. The elbow was placed in 90° flexion and maintained in distraction when applying the ulnar



**Fig. 6** Illustrations show the application of the external fixator in the (a) frontal view and (b) sagittal view.

fixation. These pins were then connected to the Bohler stirrup using universal clamps (Figs. 6a & b). Once the whole assembly was in place, the elbow was flexed and extended to ensure that the reduction was maintained and that there was no tendency for subluxation. The sharp end of the Steinmann pin was cut and the wound closed over the suction drain.

Postoperatively, the drain was kept for 48 hours. Once the initial swelling, redness and pain had subsided, the patient was started on passive and active-assisted elbow mobilisation under the supervision of a therapist. 6–8 weeks after the application, depending on the patient's overall progress, the external fixator was removed and the active use of the extremity was encouraged.

## DISCUSSION

Neglected posterior elbow dislocation causes considerable functional disability. The elbow is usually fixed in a few degrees of flexion and further flexion is limited to 10° to 15° only. Allende and Freytes have

stated that attempted closed reduction of the elbow after three weeks is hazardous due to soft tissue contracture and localised osteopenia.<sup>(2)</sup> Attempts at closed reduction may cause a fracture of the bone or damage to the articular surface. Open reduction and release of the incipient contractures are required to restore the joint surfaces. The management of this condition creates a therapeutic paradox. To reduce the joint, all soft tissues encapsulating the joint must be released. This includes stripping the capsule and ligaments both anteriorly and posteriorly. However, once this extensive release is done, the joint becomes grossly unstable, easily dislocating back to the posterior position, unless it is transfixed.

Open reduction is conducted using a technique described by Speed, which involves lengthening the triceps muscle and releasing the contracted medial and lateral collateral ligaments.<sup>(1)</sup> The resultant medial-lateral as well as anterior-posterior instability following open reduction requires external stabilisation. Repair of the collateral ligaments in a neglected elbow dislocation is not recommended as it results in a fibrosis around the joint, which eventually restricts movement. Most authors have used Kirschner wires or the Steinmann pin, transfixing the olecranon and humerus or the capitellum and radial head. This intraarticular fixation hinders early mobilisation and adds to the stiffness of an already stiff elbow.

Arafiles described the creation of an intraarticular cruciate ligament to stabilise the joint following an open reduction and to allow early<sup>(3)</sup> elbow motion. He reported good results in his 11 cases. Hotchkiss reported good results in neglected dislocated elbows that were treated using a compass hinged external fixator to maintain joint reduction and permit elbow motion.<sup>(4)</sup> However, the compass elbow hinge device is costly, cumbersome and technically difficult to apply.

We devised an external fixator assembly, which is applied immediately after achieving open reduction of the joint. This external fixator is easily procured and assembled in the operating theatre. It prevents both medial-lateral and anterior-posterior subluxation and yet achieves the desired function of elbow mobility. Both flexion/extension and supination/pronation movements are started the next postoperative day, under the supervision of a therapist. The fixator is removed after 6–8 weeks, during which the useful arch of elbow motion is restored.

Both the patients in this study achieved a good and useful range of elbow motion after a mean follow-up period of three months. There was a superficial pin tract infection in one case, which subsided after local wound

care and oral antibiotics. This assembly maintains joint reduction, permits early elbow motion and enhances muscle tendon stretching. The procedure is simple, cost effective and adjuvant to open reduction of an unreduced elbow dislocation. It converts an unstable, stiff elbow into a stable and mobile one. Owing to the original injury to the joint and the repeated trauma of unsuccessful manipulation, posttraumatic osteoarthritis may be expected later on in these cases.

#### REFERENCES

1. Speed JS. An operation for unreduced posterior dislocation of the elbow. *South Med J* 1925; 18:193.
2. Allende G, Freytes M. Old dislocation of the elbow. *J Bone Joint Surg* 1944; 26: 691-706.
3. Arafiles RP. Neglected posterior dislocation of the elbow. A reconstruction operation. *J Bone Joint Surg Br* 1987; 69:199-202.
4. Hotchkiss RN. Fractures and dislocations of the elbow. In: Bucholz RW, Heckman JD, Court-Brown C, eds. *Rockwood and Green's Fractures in Adults*. 5th ed. Philadelphia: Lippincott Williams & Wilkins, 2001; 927.