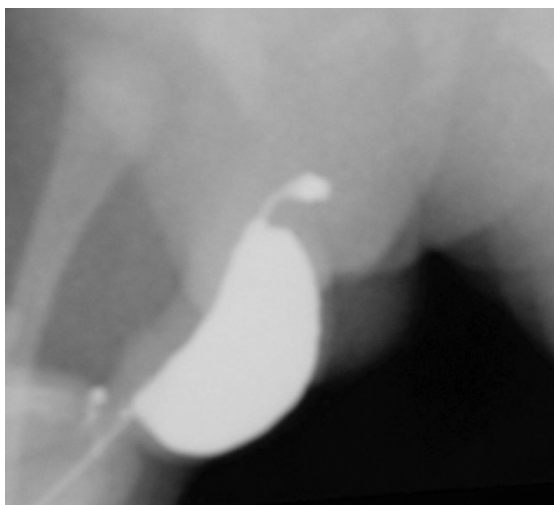


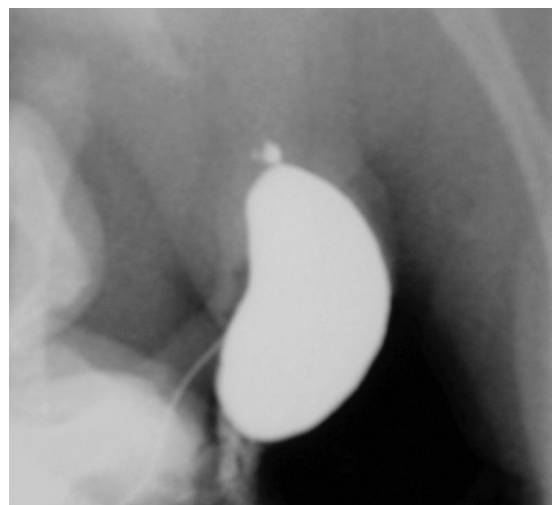
## CME Article

## Clinics in diagnostic imaging (I30)

Khan R A, Wahab S, Ullah E



**Fig. 1** Anteroposterior view of the retrograde urethrogram.



**Fig. 2** Lateral view of the retrograde urethrogram.

### CASE PRESENTATION

A 35-day-old male infant presented at the emergency department with complaints of difficulty in micturition for four days. The infant was delivered at term to a primigravida mother. There was no significant perinatal history. According to the mother, the infant had a large sized phallus, and after an apparent act of micturition, the patient continued to dribble urine for a period of time. Local examination revealed a grossly enlarged and deformed

phallus, an unretractable prepuce, which dribbled urine on pressing. Both testes were descended and the abdominal wall appeared to be normal. Haematological and biochemical examinations, including renal function test, were normal. Renal tract sonography with respect to the upper renal tract was also noncontributory. There was no evidence of any other congenital anomalies. Subsequently, retrograde urethrography (RGU) was performed (Figs. 1 & 2). What is the diagnosis?

Division of  
Paediatric Surgery,  
Jawaharlal Nehru  
Medical College  
Hospital,  
Aligarh Muslim  
University,  
Aligarh 202002,  
Uttar Pradesh,  
India

Khan RA, MS, MCh  
Lecturer

Department of  
Radiodiagnosis

Wahab S, MD  
Lecturer

Ullah E, MD,  
Professor

Correspondence to:  
Dr Shagufta Wahab  
Tel: (91) 94 10210281  
Fax: (91) 52376 5489  
Email: drshaguftawahab  
@yahoo.co.in

## IMAGE INTERPRETATION

Fig. 1 shows a large saccular dilatation of the ventral anterior urethra. The dilatation seems to be fusiform in shape, and the catheter appears to be entering in the middle of the dilated penile urethra (Fig. 2).

## DIAGNOSIS

Congenital megalourethra.

## CLINICAL COURSE

Multiple attempts at per urethral catheterisation did not materialise. Therefore, cystourethroscopy under general anaesthesia was planned. Endoscopic evaluation revealed that the fossa navicularis was normal, but the anterior urethra was dilated. The bladder mucosa was normal and the bladder neck was competent. Since the patient was passing urine with an infrequent need for pressing of the urethra to empty the dilated urethra, he was discharged, and Nesbitt's reduction urethroplasty was planned at a later date.

## DISCUSSION

The term megalourethra denotes a congenital, diffuse dilatation of the anterior urethra, which results in an abnormally large and grotesque shape of the phallus in a neonate. It is usually classified as fusiform or scaphoid.<sup>(1)</sup> This has to be differentiated from another condition known as congenital diverticula of the urethra. Based on anatomic configuration, it is categorised into two types: saccular or diffuse. Localised protrusion from the lumen into the ventral wall of the anterior urethra is known as saccular diverticula, while in the diffuse type, a generalised dilatation of the entire anterior urethra is observed.<sup>(2)</sup> The latter has also been termed as megalourethra or urethral ectasia.<sup>(2)</sup> Therefore, some authors are of the opinion that congenital anterior urethral diverticula and megalourethra are in the same spectrum. However, Appel et al opined that congenital urethral diverticula is not a part of this spectrum, as it is associated with narrow orifices as well, thereby causing obstruction, whereas megalourethra does not have a true distal anatomic obstruction.<sup>(3)</sup>

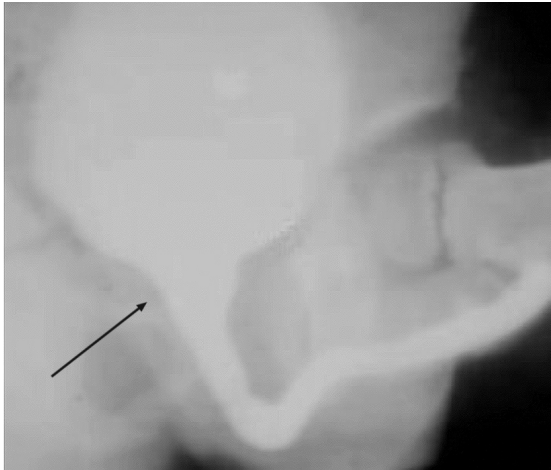
Megalourethra is a rare congenital urethral abnormality characterised by dilatation of the anterior urethra without distal obstruction. In the scaphoid form, usually only the corpus spongiosum is affected and poorly developed. In the fusiform type, which is the more severe form, the corpora cavernosa as well as the corpus spongiosum are affected.<sup>(1)</sup> In scaphoid megalourethra, there is a deficiency of the corpus spongiosum, but the glans and corpora cavernosa are normal, although they may be elongated. It is the more common variety and usually not associated with life-threatening complications. The fusiform type has a severe

deficiency of all the corpora and urethra; therefore, the urethra remains unsupported and becomes long, floppy and dilated. The fusiform type is usually associated with life-threatening congenital anomalies.<sup>(4,5,6)</sup> Although the exact aetiology of megalourethra is unknown, the embryologic event that is implicated is the arrest in the early phase of the development of the corpus spongiosum and corpora cavernosa. However, in either form, no true anatomic obstruction has been identified. Megalourethra is associated with other abnormalities of the upper urinary tract, and among these abnormalities, hydronephrosis, cystic dysplasia, vesicoureteric reflux and prune-belly syndrome have frequently been described.<sup>(7)</sup> Urethral duplication and posterior urethral valves have also been reported.<sup>(8,9)</sup> An association with anorectal malformations has previously been described.<sup>(3)</sup>

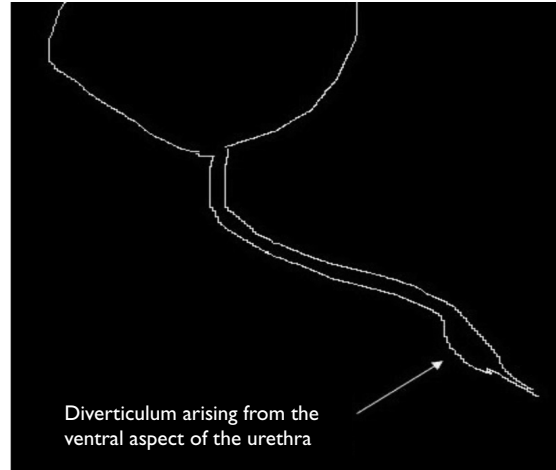
Clinically, babies with congenital megalourethra can present with a large, deformed penis which distends on voiding but which may be decompressed with pressure, deformity of the penis with erection or voiding, recurrent urinary tract infections and dribbling or poor urinary stream. They may also present with symptoms pertaining to associated anomalies, especially those of the urinary system. These boys may also present with failure to thrive, urinary ascites, or even urosepsis.<sup>(2,5,6)</sup>

The other differential diagnoses to be ruled out are anterior urethral valve (AUV), congenital urethral diverticulum, Cowper's syringocele and congenital urethral stricture. In AUV, dilatation of the urethra proximal to the valve is observed (Fig. 3). It may sometimes mimic a diverticulum. However, in such a case of AUV, the proximal end of the urethral dilatation forms an obtuse angle with the ventral floor of the urethra. In urethral diverticulum, the proximal lip forms an acute angle with the ventral floor of the urethra (Fig. 4). Cowper's syringocele occurs when there is dilatation of the main draining duct. During voiding, it presents as a filling of a globular structure at the ventral aspect of the bulbourethra (Fig. 5).<sup>(10)</sup> Urethral stricture is usually post-traumatic, but rare cases of congenital variety have also been reported<sup>(11)</sup> (Fig. 6). Failure of canalisation of the cloacal membrane during foetal development is a plausible mechanism.<sup>(11)</sup> Voiding cystourethrography (VCUG) and RGU are two essential and useful diagnostic tools to differentiate these anterior urethral abnormalities. Occasionally, the characteristic finding of megalourethra may not be demonstrated on initial VCUG; therefore, it must be repeated if the symptoms do not subside. Ultrasonography of the upper renal tract is recommended to rule out associated anomalies. Cystourethroscopy is usually the confirmatory adjunct.<sup>(12)</sup>


The standard management followed is a one-stage



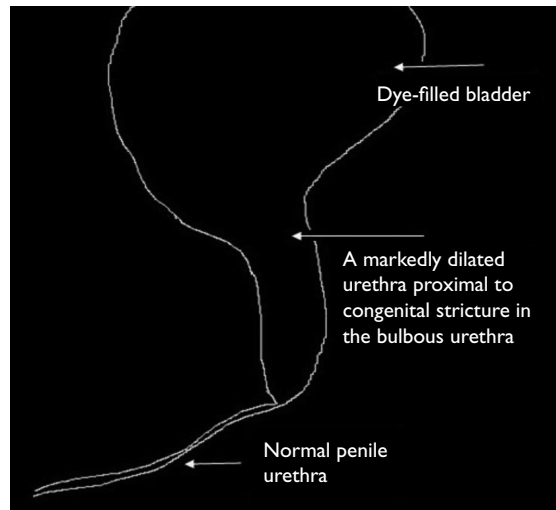
**Fig. 3** Micturating cystourethrogram (MCU) of a patient with an anterior urethral valve. The MCU clearly shows that there is dilatation of the urethra proximal to the valve (arrow), with no evidence of angulation in the ventral floor of the urethra.



**Fig. 4** Line drawing of the micturating cystourethrogram of a patient with a urethral diverticulum. It is clear that the diverticulum is arising from the ventral floor of the urethra and that the proximal lip forms an acute angle with the ventral floor.



**Fig. 5** Line drawing of the micturating cystourethrogram of a patient with Cowper's Syringocele. The main draining duct of the gland is obstructed, which results in the distension of the gland which appears as a filling of a globular structure on the ventral aspect of the bulbourethra.



**Fig. 6** Line drawing of the micturating cystourethrogram in a patient with a congenital urethral stricture. Because of the stricture, which usually occurs at the bulbous portion of the urethra, there is gross dilatation of the urethra proximal to the stricture, while the distal urethra will appear either hypoplastic or normal.

correction of the defect as proposed by Nesbitt. It involves the full-length degloving of the penile shaft, followed by a reconstruction of the neourethra over an appropriate-sized catheter after excising the redundant urethra. Excessive skin is also excised and the edges are reapproximated. Proximal urinary diversion is optional.<sup>(13)</sup> Recently, an alternative approach which involves staged correction has been proposed. In the first stage, marsupialisation of the megalourethra is done ventrally to prevent stasis, bacterial colonisation and infection. This is followed by closure of the defect when the child grows older.<sup>(14)</sup> The prognosis in the fusiform variety is poor, and since all the corpora are affected, the chances of creating a functional phallus are minimal. These patients may benefit from penile reconstruction at a later date.<sup>(6)</sup>

**ABSTRACT**

**A 35-day-old boy presented with complaints of an enlarged deformed penis and a history of difficulty in micturition. Haematological and biochemical analyses as well as renal tract sonography were normal. Retrograde urethrography revealed congenital megalourethra which was confirmed on cystourethroscopy. The literature pertaining to the types, aetiology, associated abnormalities, differential diagnosis, imaging and management of megalourethra is discussed.**

**Keywords:** congenital megalourethra, retrograde urethrography, voiding cystourethrography

**REFERENCES**

1. Kester RR, Mooppan UM, Ohm HK, Kim H. Congenital megalourethra. *J Urol* 1990; 143:1213-5.
2. Dorairajan T. Defects of spongy tissue and congenital diverticula of the penile urethra. *Aust New Zeal J Surg* 1963; 32:209-14.
3. Appel RA, Kaplan GW, Brock WA, Streit D. Megalourethra. *J Urol* 1986; 135:747-51.
4. Shrom SH, Cromie WJ, Duckett JW Jr. Megalourethra. *Urology* 1981; 17:152-6.
5. Wakhlu AK, Wakhlu A, Tandon RK, Kureel SN. Congenital megalourethra. *J Pediatr Surg* 1996; 31:441-3.
6. Belman AB. Hypospadias and other urethral abnormalities. In: Kelalis PP, King LR, Belman AB, eds. *Clinical pediatric urology*. 3rd ed. Philadelphia: Saunders 1992: 619-63.
7. Stephens FD, Fortune DW. Pathogenesis of megalourethra. *J Urol* 1993; 149:1512-6.
8. Locke JR, Noe HN. Megalourethra: surgical technique for correction of an unusual variant. *J Urol* 1987; 138:110-1.
9. Sharma AK, Kothari SK, Goel D, Agarwal LD, Tamani RN. Megalourethra with posterior urethral valves. *Pediatr Surg Int* 1999; 15:591-2.
10. Kirks DR, Grossman H. Congenital saccular anterior urethral diverticulum. *Radiology* 1981; 140:367-72.
11. Sugimoto M, Kakehi Y, Yamashita M, et al. Ten cases of congenital urethral stricture in childhood with enuresis. *Int J Urol* 2005; 12:558-62.
12. Karnak I, Senocak ME, Büyükpamukçu N, Hiçsönmez A. Rare congenital abnormalities of the anterior urethra. *Pediatr Surg Int* 1997; 12:407-9.
13. Nesbitt TE. Congenital megalourethra. *J Urol* 1955; 73:839-42.
14. Reissigl A, Eberle J, Bartsch G. Megalourethra. *Br J Urol* 1991; 68:435-8.

**SINGAPORE MEDICAL COUNCIL CATEGORY 3B CME PROGRAMME**  
**Multiple Choice Questions (Code SMJ 201004B)**

	True	False
<b>Question 1.</b> Congenital megalourethra affects the following:		
(a) Anterior urethra.	<input type="checkbox"/>	<input type="checkbox"/>
(b) Posterior urethra.	<input type="checkbox"/>	<input type="checkbox"/>
(c) Whole of the urethra.	<input type="checkbox"/>	<input type="checkbox"/>
(d) Bladder neck.	<input type="checkbox"/>	<input type="checkbox"/>
<b>Question 2.</b> Regarding the fusiform variety of congenital megalourethra:		
(a) It is the more severe form of the anomaly.	<input type="checkbox"/>	<input type="checkbox"/>
(b) It is associated with other congenital anomalies.	<input type="checkbox"/>	<input type="checkbox"/>
(c) The prognosis is poor.	<input type="checkbox"/>	<input type="checkbox"/>
(d) All of the above.	<input type="checkbox"/>	<input type="checkbox"/>
<b>Question 3.</b> What is the investigation that is first indicated in congenital megalourethra?		
(a) Voiding cystourethrography and/or retrograde urethrography.	<input type="checkbox"/>	<input type="checkbox"/>
(b) Urethroscopy.	<input type="checkbox"/>	<input type="checkbox"/>
(c) Magnetic resonance urography.	<input type="checkbox"/>	<input type="checkbox"/>
(d) Diethylene triamine pentaacetate scan.	<input type="checkbox"/>	<input type="checkbox"/>
<b>Question 4.</b> What procedure is indicated for congenital megalourethra?		
(a) Sistrunk's operation.	<input type="checkbox"/>	<input type="checkbox"/>
(b) Nesbitt's operation.	<input type="checkbox"/>	<input type="checkbox"/>
(c) Chamberlain's procedure.	<input type="checkbox"/>	<input type="checkbox"/>
(d) Dennis Brown urethroplasty.	<input type="checkbox"/>	<input type="checkbox"/>
<b>Question 5.</b> Which of the following form the differential diagnosis of congenital megalourethra?		
(a) Anterior urethral valve.	<input type="checkbox"/>	<input type="checkbox"/>
(b) Urethral diverticulum.	<input type="checkbox"/>	<input type="checkbox"/>
(c) Cowper's syringocele.	<input type="checkbox"/>	<input type="checkbox"/>
(d) All of the above.	<input type="checkbox"/>	<input type="checkbox"/>

**Doctor's particulars:**

Name in full: \_\_\_\_\_

MCR number: \_\_\_\_\_ Specialty: \_\_\_\_\_

Email address: \_\_\_\_\_

**SUBMISSION INSTRUCTIONS:**

(1) Log on at the SMJ website: <http://www.sma.org.sg/cme/smj> and select the appropriate set of questions. (2) Select your answers and provide your name, email address and MCR number. Click on "Submit answers" to submit.

**RESULTS:**

(1) Answers will be published in the SMJ June 2010 issue. (2) The MCR numbers of successful candidates will be posted online at [www.sma.org.sg/cme/smj](http://www.sma.org.sg/cme/smj) by 5 July 2010. (3) All online submissions will receive an automatic email acknowledgment. (4) Passing mark is 60%. No mark will be deducted for incorrect answers. (5) The SMJ editorial office will submit the list of successful candidates to the Singapore Medical Council.

**Deadline for submission: (April 2010 SMJ 3B CME programme): 12 noon, 28 June 2010.**