

Complete congenital third branchial fistula: does the theoretical course apply?

Aneeza W H, Mazita A, Marina M B, Razif M Y

ABSTRACT

The course of a third branchial fistula is derived from its embryological origin, in accordance with the branchial apparatus theory. Treatment of this condition requires complete removal of the tract in order to avoid recurrence; however, this can pose a risk to the surrounding structures. We report the case of a complete third branchial fistula as well as a literature review on its theoretical course and management.

Keywords: branchial apparatus, third branchial fistula

Singapore Med J 2010; 51(7): e122-e125

INTRODUCTION

The branchial apparatus has been well described and held accountable for many congenital anomalies of the head and neck region. A congenital fistula is not as commonly encountered as a cyst or sinus, and a complete congenital fistula from the third branchial apparatus is a rare occurrence.

CASE REPORT

A 14-year-old boy presented with a discharging sinus on the left neck, which had failed to respond to multiple courses of antibiotics over the past six months. He had a history of left neck swelling at birth, which had enlarged and then burst at ten days of life. It had been managed conservatively at that time, and the condition had never recurred until the current presentation. Examination revealed a small opening with pus discharge at the junction of the middle and lower third of the anterior border of the sternocleidomastoid muscle (Fig. 1). Computed tomography (CT) fistulogram was performed, where the external opening was cannulated and infused with contrast material. It revealed a lobulated lesion at the patient's left neck, which measured 2 cm × 2 cm × 4 cm and which tracted medially and superiorly into the pyriform fossa (Fig. 2).

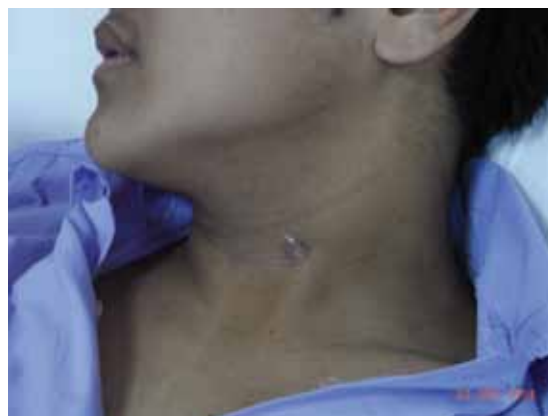

Fig. 1 Photograph shows the external opening of the third branchial fistula at the left anterior middle and lower third of the sternocleidomastoid muscle.

The patient was taken to the operating theatre for exploration and excision of the fistula. Under general anaesthesia, the external opening of the tract was dilated with a probe to delineate the tract (Fig. 3). A transverse elliptical incision was made around the external opening. A subplatysmal flap was raised superiorly and inferiorly, and the tract was dissected from the surrounding tissues. It opened into an air-filled sac deep into the sternocleidomastoid muscle, anteromedial to the carotid sheath, and then traversed the upper pole of the thyroid gland (Fig. 4). A thyroid lobectomy was also performed. The recurrent laryngeal nerve was identified and preserved. The internal opening of the tract was identified at the left pyriform fossa by direct laryngoscopy (Fig. 5). Part of the pyriform fossa was excised and the pharynx was repaired. A histopathological examination of the specimen confirmed the presence of a tract lined by squamous epithelium. The patient was started on intravenous antibiotics and nasogastric tube feeding postoperatively. A barium swallow test performed ten days later showed pooling of contrast at level C5 but no extravasations. The patient also complained of hoarseness of voice, and the scope examination showed left vocal cord palsy, which was managed expectantly.

Department of
Otorhinolaryngology,
Universiti Kebangsaan
Malaysia Medical
Centre,
Jalan Yaacob Latif,
Bandar Tun Razak,
Cheras,
Kuala Lumpur 56000,
Malaysia

Aneeza WH, MD
Medical Officer

Mazita A, MBChB, MS
Senior Lecturer and
Clinical Specialist

Marina MB, MD, MS
Senior Lecturer and
Clinical Specialist

Razif MY, MBBS, MS
Senior Lecturer and
Clinical Specialist

Correspondence to:
Dr Mohd Razif
Mohamad Yunus
Tel: (60) 3 9145 5555
Fax: (60) 3 9173 7840
Email: rafiz72@gmail.
com

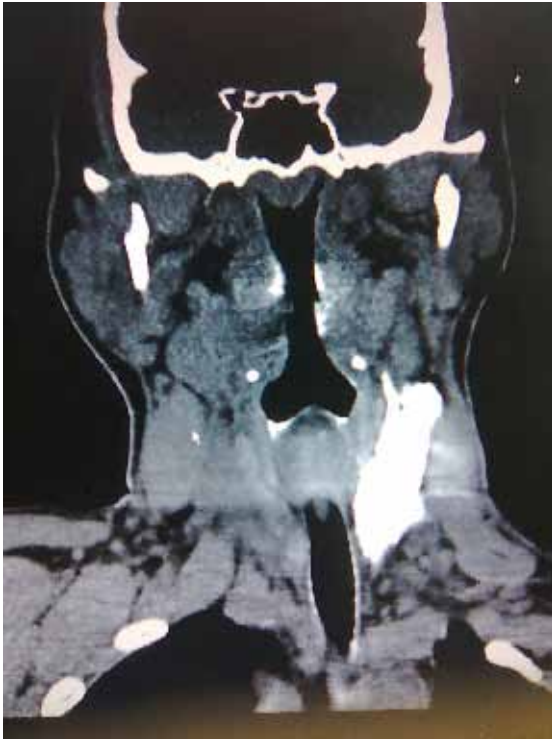

Fig. 2 Coronal CT image with contrast injected through the external opening of the fistula shows the contrast filling the cystic defect within the fistula tract.

He was last seen at 17 weeks post operation and is currently doing well.

DISCUSSION

The branchial apparatus comprises six arches with the mesoderm as its core, separated by clefts and pouches on the ectodermal and endodermal sides, respectively.⁽¹⁾ Maldevelopment of the branchial apparatus leads to branchial anomalies that occur in the form of a sinus, cyst or fistula. These anomalies may originate from the first to fourth cleft/pouch, with the commonest (95%) arising from the second cleft/pouch.⁽²⁾ Our patient had a true fistula with both internal and external openings. He had a history of neck swelling during infancy, which was similarly documented by other authors as a first presentation in their cases. He later presented with a discharging fistula during childhood.⁽³⁾

A branchial fistula is thought to form when the mesenchyme that separates the cleft and pouch involutes, thus uniting them.⁽⁴⁾ Therefore, the fistula would be caudal to the structures derived from the corresponding arch and dorsal to the structures from the following arch. A third branchial fistula would course between the third and fourth arch structures. In theory, the course starts externally from the skin opening at the upper third of the sternocleidomastoid muscle, through

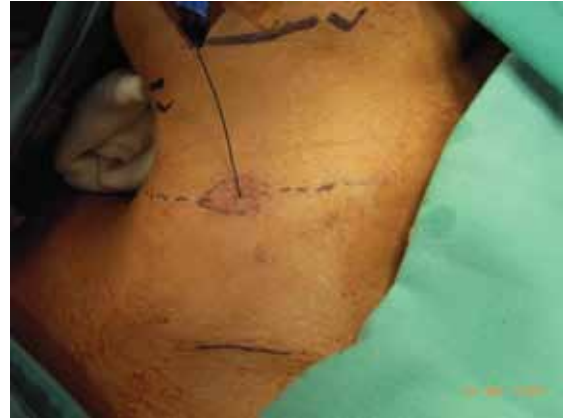

Fig. 3 Photograph shows the tract dilated serially using a metal probe to enable the injection of methylene blue dye.

the subplatysma near (not through) the superior pole of the thyroid gland, and then ascends along the carotid sheath posterior to the internal carotid artery, under the glossopharyngeal nerve (third arch derivative) and superficial to the hypoglossal nerve (fourth arch derivative). It then pierces the thyrohyoid membrane, which lies superior to the thyroid cartilage (fourth arch derivative) and passes above the superior laryngeal nerve (also a fourth arch derivative) to open at the superior part of the pyriform fossa.⁽¹⁾ These structures were observed during surgery in our patient. However, recurrent infections and fibrotic scar tissues made it difficult to identify the small structures.

During dissection, we noted that the tract traverses through the superior pole of the thyroid gland and not merely near it as proposed, and thus required a partial thyroidectomy in order to achieve complete excision of the tract. In addition, the tract did not pass behind the internal carotid artery. It has been proposed that the course of a third branchial fistula is more in keeping with the derivation of the thymopharyngeal duct.⁽⁵⁾ According to this theory, the thymus, before fusion in the midline, retains a lumen called the thymopharyngeal duct. After the fusion of the thymus, this duct usually closes and the thymus then descends at 7–8 weeks of gestation. If the thymopharyngeal duct fails to close, its tract would lead from the pyriform fossa through the thyroid gland and then descend to end at the cervical inlet. The presence of an external opening can be explained by a previous non-healing incision and drainage wound. Lee and Krishnan reported a similar course of a third branchial fistula, where a previous incision and drainage were performed on their patient.⁽⁶⁾ To date, there is little proof that a third branchial fistula that develops from a branchial apparatus anomaly truly exists.⁽⁷⁾ It has been reported that the typical course of

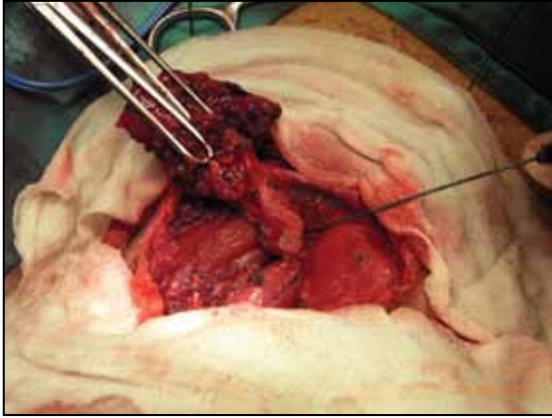


Fig. 4 Photograph shows the tract traversing through the left thyroid lobe, necessitating a thyroid lobectomy to enable complete excision of the fistula.

a fistula tract is not observed in cases of a large mass or concomitant cyst.⁽⁸⁾ Jaka and Singh reported a complete third branchial fistula that followed the famously described tract that passes posterior to the common and internal carotid artery, but they did not mention the involvement of the thyroid gland.⁽⁹⁾ In short, the theory about the origin of a branchial fistula in the branchial apparatus remains controversial, and readers should be aware that the course of these fistulas is not always typical. Nevertheless, knowledge of the theoretical tract is essential, as it describes the possible structures related to the tract, especially when planning a surgical excision.

Most authors recommend either an ultrasonography of the neck, barium swallow or CT imaging for a branchial anomaly. Some authors even advocate the use of magnetic resonance (MR) imaging.^(4,5,9,10) CT fistulogram was used in our case, as there was an external opening. CT imaging is recommended, as it allows delineation of the tract while detecting any abnormal soft tissue swelling or deformation of the pyriform sinus fossa due to adjacent soft tissue swelling, and also detects the presence of gas in the tract.⁽¹¹⁾ Gas, which is better detected on CT compared to MR imaging, is pathognomonic for pyriform sinus fistula.⁽¹²⁾ CT would also be able to sufficiently assess the involvement of the thyroid gland, which is seen as a swelling with poor margin definition and loss of high attenuation of the affected lobe.⁽¹¹⁾ CT imaging with fistulogram not only delineated the tract satisfactorily, but also allowed us to assess its involvement with the thyroid gland and its relation to the surrounding major structures in our patient. Ultrasonography is useful as an initial investigation of a neck mass, where the presence of gas raises suspicion of a pyriform fossa

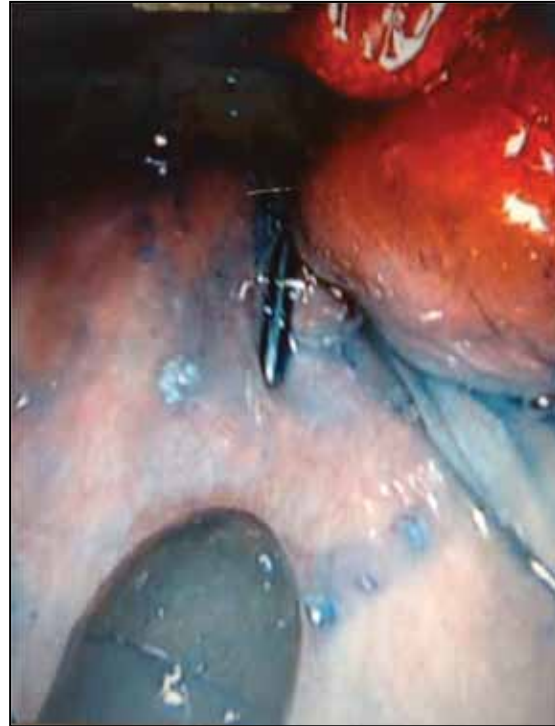

Fig. 5 Indirect laryngoscopic view shows the internal opening of the fistula that opens into the right pyriform fossa.

sinus. A barium swallow with thin contrast material is used when there is no external opening to delineate the tract. It is only performed during the quiescent stage when the sensitivity is 80%.⁽¹³⁾

We advocate the use of barium swallow during the postoperative period in order to assess for the presence of remnants of the branchial fistula and leaking of contrast at the repaired hypopharynx. The reported pooling of contrast at the C5 level, which is suggestive of fistula remnants, may likely be a false negative due to the surrounding oedema.

The treatment of choice for a third branchial fistula is surgical resection, as there has been no evidence of spontaneous regression and this condition is at a high risk of recurrent infection. The standard method of excision is the use of a stepladder incision. Another method is the stripping of the tract. Stripping of the branchial fistula involves passing the stripper inside the tract using wire stilletes, vein strippers or arterial intimal strippers. Its advantage lies in that it is a simple method and does not involve the use of extensive dissection.⁽⁷⁾ However, it is a blind technique that poses a higher risk of injury to the surrounding structures, especially with a branchial fistula that had recurrent infection with surrounding fibrosis. Regardless of the technique used, complete removal of the tract is essential to avoid recurrence. The tract may be delineated intraoperatively using

methylene blue dye injection. Some authors, however, find this technique suboptimal due to the extravasation of dye into the surrounding tissue.^(6,14)

In our experience, methylene blue dye injection proved not only to be inexpensive but also practical. During the dissection of the tract, over-traction caused the tract to break, resulting in internal retraction of the tract into the soft tissue. However, re-identifying the tract was easy due to the presence of the dye, and it was thus successfully excised. Another method of delineating the tract is by using the Fogarty catheter; however, maintaining a catheter in the tract during surgery is difficult. Edmonds et al have recommended the use of direct laryngoscopy and transillumination of the tract with a rigid telescope.⁽¹⁴⁾ A hemithyroidectomy may be required to fully excise the tract, and this has been advocated by other authors.⁽¹³⁾ The recurrence rate of branchial anomaly is 3% for a primary lesion and as high as 22% for lesions with previous infection and surgery.⁽¹⁵⁾ Recurrence arises mostly when the thyroid tissue is not removed or when the tract is not identified.⁽⁴⁾ Another complication of surgery is injury to the recurrent laryngeal nerve. The left vocal cord palsy in our patient was most likely due to neuropraxia caused by retraction injury during dissection.

In conclusion, the tract of the third branchial fistula remains a theoretical issue. The rarity of cases encountered makes a prospective study on its course difficult. Surgical excision remains the treatment for the condition, and caution must be exercised to avoid

recurrent laryngeal nerve injury. A hemithyroidectomy should be considered for complete excision of the tract.

REFERENCES

1. Link TD, Bite U, Kasperbaur JL, Harner SG. Fourth branchial pouch sinus: a diagnostic challenge. *Plast Reconstr Surg* 2001; 108:695-701.
2. Gross E, Sichel JY. Congenital neck lesions. *Surg Clin North Am* 2006; 86:383-92.
3. Lin JN, Wang KL. Persistent third branchial apparatus. *J Pediatr Surg* 1991; 26:663-5.
4. Yang C, Cohen J, Everts E, et al. Fourth branchial arch sinus: clinical presentation, diagnostic workup, and surgical treatment. *Laryngoscope* 1999; 109:442-6.
5. James A, Stewart C, Warrick P, Tzifa C, Forte V. Branchial sinus of the piriform fossa: reappraisal of third and fourth branchial anomalies. *Laryngoscope*; 117:1920-4.
6. Lee ST, Krishnan MM. Branchial fistula--a review. *Singapore Med J* 1991; 32:50-2.
7. Maran AG, Buchanan DR. Branchial cysts, sinuses and fistulae. *Clin Otolaryngol Allied Sci* 2007; 3:77-92.
8. Liberman M, Kay S, Emil S, et al. Ten years of experience with third and fourth branchial remnants. *Jour Pediatr Surg* 2002; 37:685-90.
9. Jaka RC, Singh G. Complete congenital third branchial fistula on the right side. *Otolaryngol Head Neck Surg* 2007; 137:518-9.
10. Chang KW, Lee BG, Gutierrez KM. Third branchial cleft fistula infected with *Actinomyces*. *Int J Pediatr Otorhinolaryngol Extra* 2008; 3:20-3.
11. Gan YU, Lam SL. Imaging findings in acute neck infection due to pyriform sinus fistula. *Ann Acad Med Singapore* 2004; 33:636-40.
12. Mukerji SS, Parmar H, Ibrahim M, Bradford C. An unusual cause of recurrent pediatric neck abscess: pyriform sinus fistula. *Clin Imaging* 2007; 31:349-51.
13. Cases JA, Wenig BM, Silver CE, Surks MI. Recurrent acute suppurative thyroiditis in an adult due to a fourth branchial pouch fistula. *J Clin Endocrinol Metab* 2000; 85:953-6.
14. Edmonds JL, Girod DA, Woodroof JM, Bruegger DE. Third branchial anomalies. Avoiding recurrences. *Arch Otolaryngol Head Neck Surg* 1997; 123:438-41.
15. Choi SS, Zalzal GH. Branchial anomalies: a review of 52 cases. *Laryngoscope* 1995; 105:909-13.