

# An unusual case of knee locking

Lee K H, Chang P C C, Lie D T T, Koh J S B, Ong K L

## ABSTRACT

**Knee locking is an incapacitating condition that requires urgent orthopaedic intervention. The most common cause is meniscal injury, followed by torn anterior cruciate ligament, osteochondral loose bodies and foreign bodies in the joint space. This report describes a patient who had an unusual case of left knee locking. After clinical examination and radiological investigations, the provisional diagnosis was a lateral meniscal tear, which was not visible on magnetic resonance imaging. Diagnostic arthroscopy of the left knee revealed a 1-cm yellowish lump on the medial meniscus, and the histology revealed pigmented villonodular synovitis. The menisci and cruciate ligaments were intact.**

**Keywords:** knee locking, pigmented villonodular synovitis

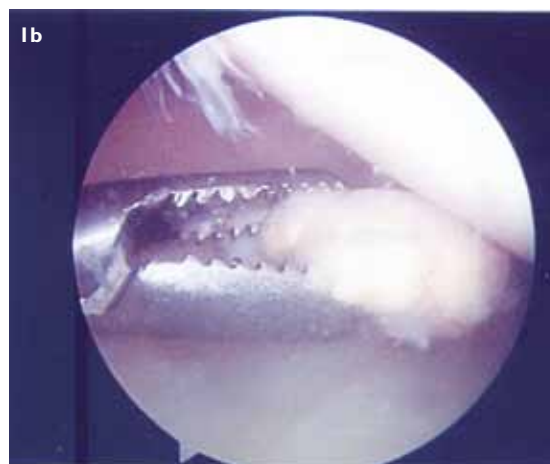
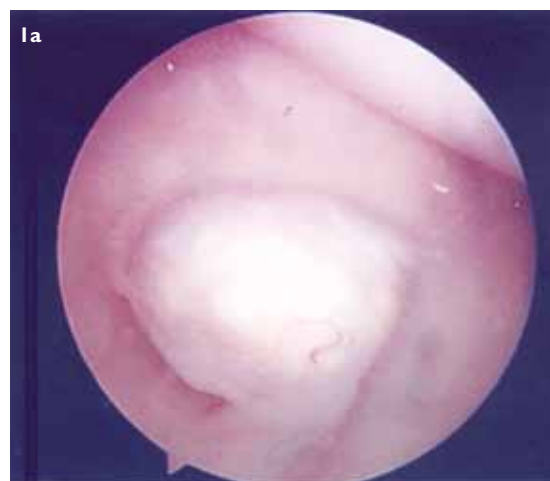*Singapore Med J 2010;51(8):e140-e142*

## INTRODUCTION

Pigmented villonodular synovitis (PVNS) is a rare disorder of unknown aetiology that affects the synovial lined joints, bursae and tendon sheaths. Although this condition can affect any synovial joint, it typically and most commonly affects the knee joint, followed by the hips and ankle. Pathologically, two main forms of PVNS are described, with the diffuse form more commonly observed than the localised form. Myers and Masi estimated an annual incidence of approximately two cases per million population.<sup>(1)</sup> Knee locking secondary to PVNS is rarely reported. We present a case of PVNS with symptoms of locking which was not apparent on preoperative radiographs or magnetic resonance (MR) imaging, but was later diagnosed on arthroscopy.

## CASE REPORT

A 43-year-old Chinese man, who had a left knee arthroscopy performed 15 years ago due to knee pain, presented at our clinic with a four-month history of painful intermittent left knee locking. As a result of his knee pain and locked knee, the patient experienced difficulties in his activities of daily



**Fig. 1** Arthroscopic images show solitary pigmented villonodular synovitis in the knee joint.

living, including squatting and sleeping.

Physical examination of the left knee revealed signs of locking and mild lateral joint line tenderness with negative Lachman's test. MR imaging of the left knee revealed degeneration of the body of the left medial meniscus, but no tear of the meniscus or intra-articular bodies was observed. The posterior surface of the left patella was also reported to be diffusely thin. On the basis of these conflicting results, the provisional diagnosis was that of left meniscal tear that was not visible on MR imaging, and an arthroscopic lateral meniscectomy was planned. On arthroscopy, a solitary 1-cm yellowish pedunculated lump was detected on the medial meniscus of the left knee (Fig. 1). The medial and lateral menisci, cartilage and the anterior cruciate

Department of  
Orthopaedic Surgery,  
Singapore General  
Hospital,  
Outram Road,  
Singapore 169608

Lee KH, MBBS, MRCSE  
Medical Officer Trainee

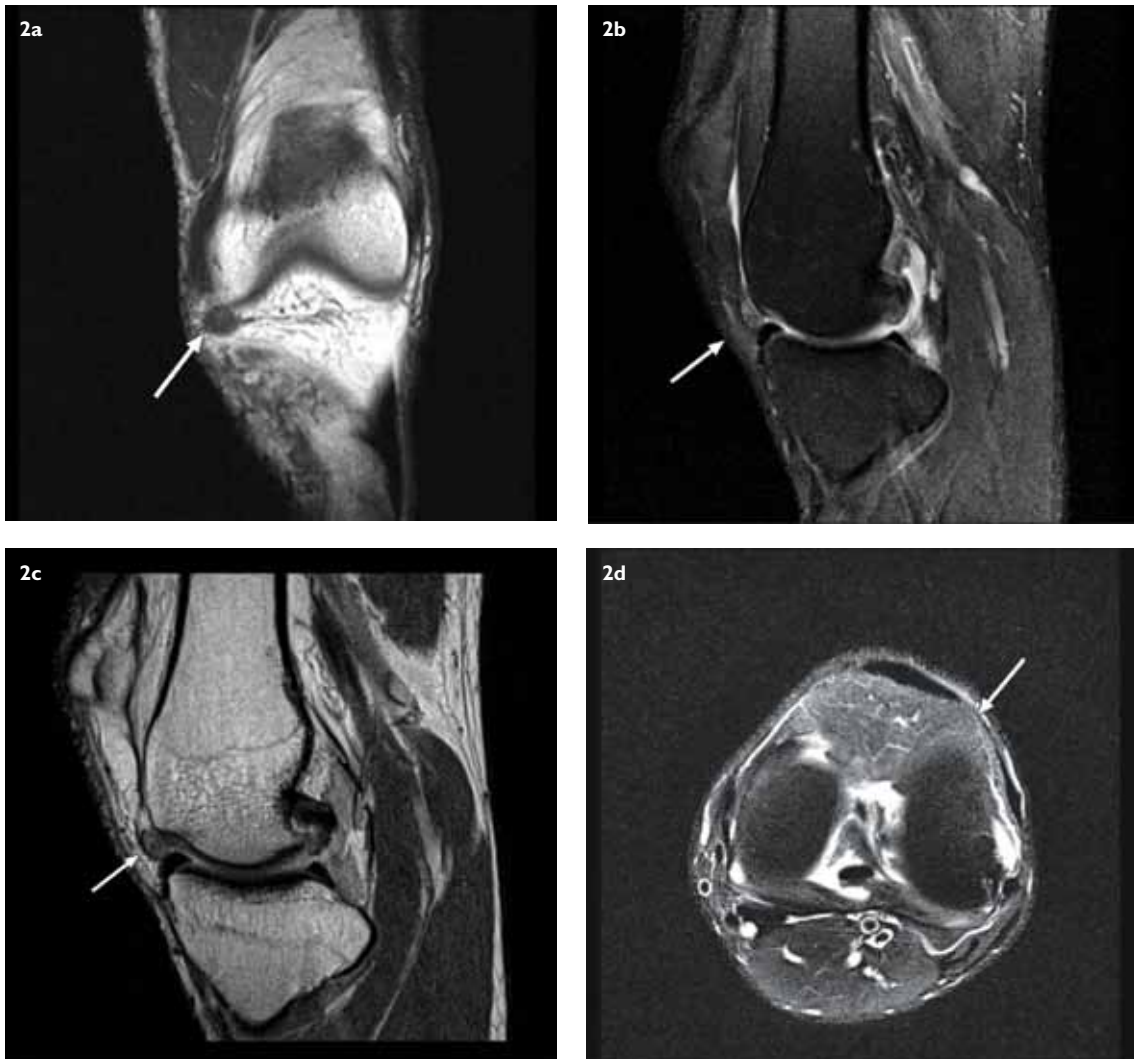Chang PCC, MBBS,  
FRCS  
Senior Consultant and  
Director of Sports  
Medicine Service

Lie DTT, MBBS, FRCS  
Senior Consultant

Koh JSB, MBBS, FRCS  
Consultant

Ong KL, MBBS, MRCS  
Registrar

**Correspondence to:**  
Dr Lee Kong Hwee  
Tel: (65) 6321 4040  
Fax: (65) 6321 8100  
Email: konghwee.lee@  
mohh.com.sg



**Fig. 2** MR images before arthroscopy indicate pigmented villonodular synovitis (PVNS). (a) T1-W coronal image shows PVNS with void signal intensity (arrow). (b) T1-W and (c) T2-W sagittal images show low-signal intensities (arrows). (d) T2-W axial image shows void signal (arrow).

ligament were found to be intact.

Excision of the lump was performed, and histological examination revealed an encapsulated nodule composed of a large number of histiocytes, foamy macrophages, fibroblasts and occasional Touton-type giant cells, which was suggestive of nodular tenosynovitis. No evidence of malignancy was present. Postoperatively, the patient experienced complete resolution of his left knee pain and locking symptoms. He was referred for outpatient physiotherapy to improve his quadriceps strength and to increase the range of motion of his knee. On retrospective study of the MR images postoperatively, we were able to locate the localised PVNS (Fig. 2).

## DISCUSSION

PVNS is typically an insidious monoarticular disease affecting the knee joint, and the patient usually complains of pain, swelling and locking. Clinical examination

often reveals signs of intra-articular disease, such as locking, swelling and joint line tenderness. As PVNS is a rare condition, diagnosing the disease as the cause of knee locking is clinically challenging. There have been reports on localised PVNS causing locking symptoms, mimicking meniscal injuries and other intra-articular pathologies.<sup>(2)</sup> But interestingly, in our patient, the localised medial PVNS not only caused knee locking, as previously reported, but also symptoms on the lateral joint line. Therefore, in cases of localised PVNS, localisation of symptoms may not be accurate.

MR imaging is the current imaging modality of choice for PVNS. Characteristically, PVNS exhibits low or void signal intensity on both T1- and T2-weighted MR images, and these changes were present in our patient's MR images (Fig. 2). However, if the diagnosis remains in doubt, as in the case of our patient, diagnostic arthroscopy is indicated for direct visualisation of synovial pathology

and for obtaining tissue for histological analysis.

Treatment of localised PVNS involves excision, either via open synovectomy or arthroscopically. With the advancement of arthroscopic synovectomy, excision of localised PVNS can be conducted with fewer morbidities and with an equivalent outcome as open synovectomy.<sup>(3)</sup> Localised PVNS carries a good prognosis with a very low chance of recurrence.<sup>(4)</sup> In a study conducted by Ogilvie-Harris et al, 25 patients with localised and diffuse PVNS were followed up for an average of four-and-a-half years post surgery (range 2–11 years). Postoperatively, all five localised PVNS patients reported no residual pain, locking or synovitis. No recurrence was noted during the follow-up period, and all five patients were satisfied with the outcome.<sup>(3)</sup> In another study by Rao and Vigorita, among the eight patients who were followed up for 5–120 months, only one patient suffered a recurrence.<sup>(5)</sup> However, due to the small population size of the above studies, these results might not be statistically significant.

For the more common diffuse PVNS, even though the pathological changes are similar to the localised form, the treatment is controversial. The options available include surgical synovectomy, arthroscopic synovectomy and radiation synovectomy.<sup>(6,7)</sup> The outcome is generally poorer in this group, with a higher

recurrence rate and more persistent intra-articular symptoms.

In summary, although the occurrence of localised PVNS is uncommon, it may be worthwhile to consider this differential diagnosis when the results of imaging modalities do not support the physical findings.

## REFERENCES

1. Myers BW, Masi AT. Pigmented villonodular synovitis and tenosynovitis: a clinical epidemiologic study of 166 cases and literature review. *Medicine (Baltimore)* 1980; 59:223-38.
2. Roach R and dos Remedios I. Localised pigmented villonodular synovitis: an uncommon cause of knee pain mimicking a meniscal tear. *Br J Sports Med* 2003; 37:368-9.
3. Ogilvie-Harris DJ, McLean J, Zarnett ME. Pigmented villonodular synovitis of the knee. The results of total arthroscopic synovectomy, partial, arthroscopic synovectomy, and arthroscopic local excision. *J Bone Joint Surg Am* 1992; 74:119-23.
4. Zvijac JE, Lau AC, Hechtman KS, Uribe JW, Tjin-A-Tsoi EW. Arthroscopic treatment of pigmented villonodular synovitis of the knee. *Arthroscopy* 1999; 15:613-7.
5. Rao AS, Vigorita VJ. Pigmented villonodular synovitis (giant-cell tumor of the tendon sheath and synovial membrane). A review of eighty-one cases. *J Bone Joint Surg Am* 1984; 66:76-94.
6. Flandry FC, Hughston JC, Jacobson KE, et al. Surgical treatment of diffuse pigmented villonodular synovitis of the knee. *Clin Orthop Relat Res* 1994; (300):183-92.
7. Blanco CE, Leon HO, Guthrie TB. Combined partial arthroscopic synovectomy and radiation therapy for diffuse pigmented villonodular synovitis of the knee. *Arthroscopy* 2001; 17:527-31.