

Sciatic nerve division: a cadaver study in the Indian population and review of the literature

Prakash, Bhardwaj A K, Devi M N, Sridevi N S, Rao P K, Singh G

ABSTRACT

Introduction: The sciatic nerve is the largest nerve, with a long course in the inferior extremity. Its division into the tibial and common peroneal nerves can occur at any level from the sacral plexus to the inferior part of the popliteal space. These anatomical variations may contribute to clinical conditions such as piriformis syndrome, sciatica and coccygodynia.

Methods: This study was performed on cadavers in order to study the level of sciatic nerve division. The inferior extremities of 43 cadavers were classified into six groups depending on the level of sciatic nerve division in the gluteal region, the upper, middle and lower parts of the back of the thigh, and the popliteal fossa.

Results: The highest incidence of sciatic nerve division (40.7 percent) was observed in the lower part of the posterior compartment of the thigh. In 34.9 percent of the specimens, the sciatic nerve was divided into tibial and common peroneal nerves in the popliteal fossa. 16.3 percent of extremities showed sciatic nerve division proximal to its entrance in the gluteal region.

Conclusion: In sciatic nerve neuropathies, the extent of neurological deficits depends on the level of sciatic nerve division. Sciatic nerve division into tibial and common peroneal components at a higher level can result in the involvement of only one out of the two divisions from sciatic neuropathy. It can also result in a failure of the sciatic nerve block while performing popliteal block anaesthesia.

Keywords: anatomy, cadaver, common peroneal nerve, sciatic nerve, tibial nerve

Singapore Med J 2010; 51(9): 721-723

INTRODUCTION

The sciatic nerve is the thickest nerve in the human body. Sciatic neuropathy is a result of injuries to the sciatic nerve, leading to neurological deficits. Its long course makes it vulnerable to nerve injury from various causes.⁽¹⁾ It bifurcates into two major divisions (tibial and common peroneal), most commonly at the lower part of the posterior compartment of the thigh.⁽²⁻⁵⁾ Several authors have reported variations on its division into the tibial and common peroneal nerve from the sacral plexus to the lower part of the popliteal space.⁽³⁻¹⁰⁾ These anatomical variations may contribute to piriformis syndrome, sciatica, coccygodynia and muscle atrophy.⁽¹¹⁾ This should be taken into account by clinicians who are planning interventions around the sciatic nerve and its division in the lower extremity. Even in the current era, the cadaver is the best means to study anatomy. Hence, this study was undertaken on cadavers to study the incidence of sciatic nerve division into tibial and common peroneal nerves in the Indian population, which has not been reported in the literature.

METHODS

A total of 43 properly embalmed and formalin-fixed cadavers (29 male and 14 female) were studied. Both the inferior extremities (n = 86) were dissected in order to expose the sciatic nerve, including its division into the tibial and common peroneal nerves. They were categorised into six groups (A–F), depending on the level of division of the sciatic nerve into the tibial and common peroneal nerves. In the cadavers in Group A, the sciatic nerve divided proximal to its exit in the gluteal region. In Group B, it divided in the gluteal region. In Groups C, D and E, it divided in the upper, middle and lower region of the back of the thigh, respectively. In Group F, the sciatic nerve divided in the popliteal fossa.

RESULTS

In 15 (ten male and five female) of the 86 (17.4%) extremities, the sciatic nerves divided into the tibial and common peroneal nerves before their exit in the

Department of Anatomy,
Vydehi Institute of
Medical Sciences and
Research Centre,
82 EPIP Area,
Whitefield,
Bangalore,
Karnataka 560066,
India

Prakash, MBBS, MD
Associate Professor

Devi MN, MBBS, MD
Assistant Professor

Sridevi NS, MBBS, MD
Assistant Professor

Rao PK, MBBS, MS
Professor

Department of
Ophthalmology,
Katihar Medical College,
Karimbagh,
PO Box No. 23,
Katihar,
Bihar 854105,
India

Bhardwaj AK, MBBS, MS
Assistant Professor

Department of Anatomy,
Institute of Medical
Sciences,
Banaras Hindu
University,
Varanasi,
Uttar Pradesh 221005,
India

Singh G, MBBS, MS
Professor and Former
Director

Correspondence to:
Dr Prakash
Tel: (91) 802 841 3838
Fax: (91) 802 841 2956
Email: prakashrinku@
rediffmail.com

Table I. A comparison of the level of sciatic nerve division found in various studies.

Study	Year	No. of specimens; lower extremities	Incidence of division of the sciatic nerve in the gluteal region (%)	
			Before exit	After exit
Pokorný et al ⁽¹³⁾	2006	91; 182	20.9	79.1
Ugrenović et al ⁽¹⁴⁾	2005	100; 200	4.0	96.0
Gabrielli et al ⁽¹⁵⁾	1997	40; 80	13.7	86.3
Güvençer et al ⁽¹⁷⁾	2009	25; 50	48.0	52.0
Present study	2009	43; 86	16.3	83.7

gluteal region, and were hence classified under Group A. Fig. 1 shows the division of the sciatic nerve into tibial and common peroneal nerves prior to its exit in the gluteal region in both the extremities of a cadaver. In two (one male and female each) out of 86 (2.3%) extremities, the sciatic nerve made tibial and common peroneal divisions in the gluteal region (Group B). In three (two male and 1 female) out of 86 (3.5%) extremities, it divided at the upper part of the posterior compartment of the thigh (Group C). 2.3% of the extremities (one male and one female) showed a division of the sciatic nerve at the middle part of the back of the thigh (Group D). Group E reported the highest incidence of sciatic nerve division; in 35 (24 male and 11 female) out of 86 extremities (40.7%), the sciatic nerve divided at the lower part of the posterior compartment of the thigh. 30 (21 male and nine female) out of 86 extremities (34.9%) were classified under Group F, as they showed division of the sciatic nerve into tibial and common peroneal nerves in the popliteal fossa. No significant difference was observed within the groups in the level where the sciatic nerve divides between male and female in the previously mentioned cadavers in the Indian population.

DISCUSSION

During embryological development at the base of the limb bud, the nerves contributing to the lower limb form two plexuses (lumbar and sacral).⁽¹²⁾ Later, as the elements from each of these plexuses grow out into the limb, they are subdivided into dorsal and ventral components, for the dorsal and ventral musculatures.⁽¹²⁾ The sciatic nerve is formed when the large dorsal component of the sacral plexus (common fibular nerve) and the ventral component (tibial nerve) move downward close together.⁽¹²⁾ Hence, based on their previously mentioned developmental formation, it is possible that the common fibular and the tibial divisions of the sciatic nerve separate from each

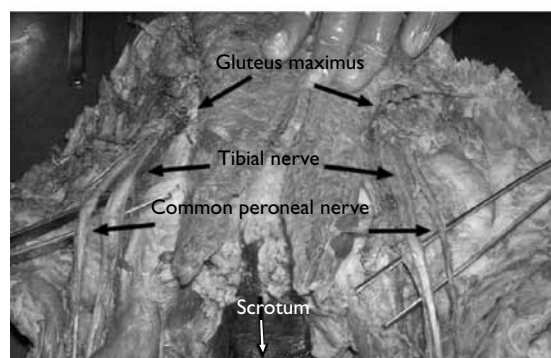


Fig. 1 Photograph shows the sciatic nerve dividing into tibial and common peroneal nerves before exiting in the gluteal region in both extremities of the cadaver.

other at different levels from their origins; in the gluteal region, the posterior compartment of the thigh or the popliteal fossa, as observed in this study.

Various studies have reported on the level of sciatic nerve division into tibial and common peroneal nerves (Table I). The incidence of sciatic nerve division before its exit in the gluteal region in our study was 16.3%, which was lower than that found in a study conducted by Pokorný et al (20.9%),⁽¹³⁾ but higher than that reported by Ugrenović et al (4.0%) and Gabrielli et al (13.7%).^(14,15) Saleh et al studied the level of division of the sciatic nerve sheath into the tibial nerve and common peroneal nerve above the knee in 30 cadaver specimens, and reported that the sciatic nerve divided at a distance of 50–180 mm above the popliteal fossa crease.⁽¹⁶⁾ Güvençer et al examined 50 gluteal regions in 25 cadavers and observed that in 52% of the cases, the sciatic nerve exited the pelvis as a whole nerve without any division, whereas in 48% of the cases, a high division of sciatic nerve was recorded (Table I).⁽¹⁷⁾ Suresh et al recorded the measurements from the magnetic resonance images of 59 patients and proposed a formula for determining the point of bifurcation of the sciatic nerve at the posterior thigh using a linear regression model.⁽¹⁸⁾

Acute sciatic neuropathies commonly result from

hip arthroplasty, hip fracture or dislocation.⁽¹⁾ On the other hand, causes such as coma, which result in prolonged compression, are relatively rare.⁽¹⁾ The extent of involvement and neurological deficits vary depending on the level of division of the sciatic nerve. A high division of the sciatic nerve into the tibial and common peroneal nerves can result in the escape of either the tibial or the common peroneal nerve from one of the aforementioned causes, which would finally result in a decrease in neurological deficits as compared to the low division of the sciatic nerve. One important consequence of the high division of the sciatic nerve that has been reported by various authors is that it may lead to the failure of popliteal block anaesthesia.^(19,20)

REFERENCES

1. Yuen EC, So YT. Sciatic neuropathy. *Neurol Clin* 1999; 17:617-31.
2. Paval J, Nayak S. A case of bilateral high division of sciatic nerve with a variant inferior gluteal nerve. *Neuroanatomy* 2006; 5:33-4.
3. Standring S. *Gray's Anatomy: the Anatomical Basis of Clinical Practice*. 39th ed. London: Churchill Livingstone, 2005: 1364-458.
4. Rosse C, Gaddum-Rosse P, Hollinshead WH. *Hollinshead's Textbook of Anatomy*. 5th ed. Philadelphia: Lippincott-Raven Publishers, 1997: 324-651.
5. Moore KL, Dalley AF. *Clinically Oriented Anatomy*. 4th ed. Philadelphia: Lippincott Williams & Wilkins, 1999: 347-560.
6. Ndiaye A, Sakho Y, Fall F, Dia A, Sow ML. [Sciatic nerve in gluteal portion: application of sciatic nerve post injection lesion.] *Morphologie* 2004; 88:135-8. French.
7. Arifoglu Y, Sürücü HS, Sargon MF, Tanyeli E, Yazar F. Double superior gemellus together with double piriformis and high division of the sciatic nerve. *Surg Radiol Anat* 1997; 19:407-8.
8. Valade N, Ripart J, Nouvellon E, et al. Does sciatic parasacral injection spread to the obturator nerve? An anatomic study. *Anesth Analg* 2008; 106:664-7.
9. Benzon HT, Katz JA, Benzon HA, Iqbal MS. Piriformis syndrome: anatomic considerations, a new injection technique, and a review of the literature. *Anesthesiology* 2003; 98:1442-8.
10. Schwemmer U, Markus CK, Greim CA, et al. Sonographic imaging of the sciatic nerve and its division in the popliteal fossa in children. *Paediatr Anaesth* 2004; 14:1005-8.
11. Babinski MA, Machado FA, Costa WS. A rare variation in the high division of the sciatic nerve surrounding the superior gemellus muscle. *Eur J Morphol* 2003; 41:41-2.
12. Demiryurek D, Bayramoglu A, Erbil M, Aldur MM, Mustafa ES. Bilateral divided piriformis muscle together with the high division of the sciatic nerve. *Gazi Med J* 2002; 13:41-4.
13. Pokorný D, Jahoda D, Veigl D, Pínkerová V, Sosna A. Topographic variations of the relationship of the sciatic nerve and the piriformis muscle and its relevance to palsy after total hip arthroplasty. *Surg Radiol Anat* 2006; 28:88-91.
14. Ugrešević S, Jovanović I, Krstić V, et al. [The level of the sciatic nerve division and its relations to the piriform muscle]. *Vojnosanit Pregl* 2005; 62:45-9. Serbian.
15. Gabrielli C, Olave E, Mandiola E, et al. Inferior gluteal nerve course associated to the high division of the sciatic nerve. *Rev Chil Anat* 1997; 15:79-83.
16. Saleh HA, El-fark MM, Abdel-Hamid GA. Anatomical variation of sciatic nerve division in the popliteal fossa and its implication in popliteal nerve block. *Folia Morphol (Warsz)* 2009; 68:256-9.
17. Güvençer M, Iyem C, Akyer P, Tetik S, Naderi S. Variations in the high division of the sciatic nerve and relationship between the sciatic nerve and the piriformis. *Turk Neurosurg* 2009; 19:139-44.
18. Suresh S, Simion C, Wyers M, et al. Anatomical location of the bifurcation of the sciatic nerve in the posterior thigh in infants and children: a formula derived from MRI imaging for nerve localization. *Reg Anesth Pain Med* 2007; 32:351-3.
19. Vluka JD, Hadžić A, April E, Thys DM. The division of the sciatic nerve in the popliteal fossa: anatomical implications for popliteal nerve blockade. *Anesth Analg* 2001; 92:215-7.
20. Nayak S. An unusual case of trifurcation of the sciatic nerve. *Neuroanatomy* 2008; 5:6-7.