

# Differential expression of galectin-3 in advancing thyroid cancer cells: a clue toward understanding tumour progression and metastasis

Htwe T T, Karim N, Wong J, Jahanfar S, Mansur M A

## ABSTRACT

**Introduction:** Galectin-3 is a member of the beta-galactoside-binding protein family that plays an important role in cell-to-cell adhesion and in cell-to-matrix interaction. Cellular expression of galectin-3 is correlated with cancer aggressiveness and metastasis.

**Methods:** We examined the differential expression of galectin-3 in a collection of 142 cases of thyroid lesions, including 108 cases of papillary thyroid carcinoma (PTC) and 34 cases of follicular carcinoma (FCA). An immunohistochemical method was applied and semiquantitative scoring was performed on the staining intensity of the positive tissue. Scoring was done on cells at the central portion of the tumour foci and on cells at the periphery that were adjacent to the neighbouring normal thyroid tissue matrix.

**Results:** A significantly higher expression ( $p = 0.001$ ) of galectin-3 was observed in the advancing peripheral thyroid cancer cells compared to the centrally located cells that were not in close contact with the neighbouring stromal tissue in cases with PTC compared to those with FCA.

**Conclusion:** This finding supported the role of galectin-3 in its cell-to-cell adhesion and cell-to-matrix interaction. Galectin-3 is a potential tumour marker for indicating local and distance metastasis, especially in cases with PTC.

**Keywords:** galectin-3, metastasis, thyroid cancer

*Singapore Med J 2010;51(11):856-859*

## INTRODUCTION

Galectin-3 is a 31-kDa carbohydrate-binding protein that has an affinity for  $\beta$ -galactoside.<sup>(1,2)</sup> Galectin-3 molecules are localised mainly in the cytoplasm and

are expressed on the cell surface.<sup>(3)</sup> This protein is involved in diverse biological processes, such as cell-to-cell and cell-to-matrix interactions,<sup>(4-6)</sup> induction of pre-mRNA splicing,<sup>(7)</sup> cell proliferation,<sup>(8)</sup> cell cycle regulation,<sup>(5,9)</sup> angiogenesis<sup>(10)</sup> and more importantly, tumourigenesis<sup>(11-13)</sup> and metastasis.<sup>(2,11,12)</sup> Studies have revealed that galectin-3 level is elevated in a variety of primary and metastatic tumour cells.<sup>(11)</sup> However, this finding is not a consistent observation.<sup>(2)</sup> Studies have mentioned a direct correlation in the expression of galectin-3 in supporting and enhancing tumour progression, invasion and metastasis.<sup>(13)</sup> Galectin-3 was supposed to enhance the metastatic potential in breast cancer cell and in primary gastric cancer.<sup>(14,15)</sup> However, a recent study on papillary thyroid carcinoma (PTC) has observed that there was a decreased intensity of galectin-3 expression at the invasive edges of the tumours during tumour progression.<sup>(16)</sup> Although the expression of galectin-3 has been widely studied in thyroid malignancies, its differential expression in the expanding thyroid lesion has not yet been thoroughly investigated, and controversies still exist. We examined the differential expression of galectin-3 in a collection of 142 cases of thyroid lesions, including 108 cases of PTC and 34 cases of follicular carcinoma (FCA), using immunohistochemistry to explore its relationship in local invasiveness.

## METHODS

A total of 142 surgically removed thyroid lesions, including 108 cases of PTC and 34 cases of FCA were included in this study. Specimens were retrieved from the archived collection of slides and wax blocks during the years 2004 to 2007, from the Pathology Department of General Hospital, Ipoh, Malaysia and General Hospital of Kuching, Sarawak, Malaysia. All cases were of classical PTC and FCA without distant metastasis. Data on age, tumour size and stage, as well as local and distant metastasis were obtained from the original pathology reports and by re-evaluation of the archived

Pathology Discipline,  
University Kuala  
Lumpur-Royal  
College of Medicine  
Perak,  
No. 3 Jalan  
Greentown,  
Ipoh 30450,  
Malaysia

Htwe TT, MBBS,  
DPath, MSc  
Associate Professor

Mansur MA,  
MBBS, DCP  
Professor and Head

Public Health  
Discipline

Jahanfar S, BSc,  
MSc, PhD  
Associate Professor

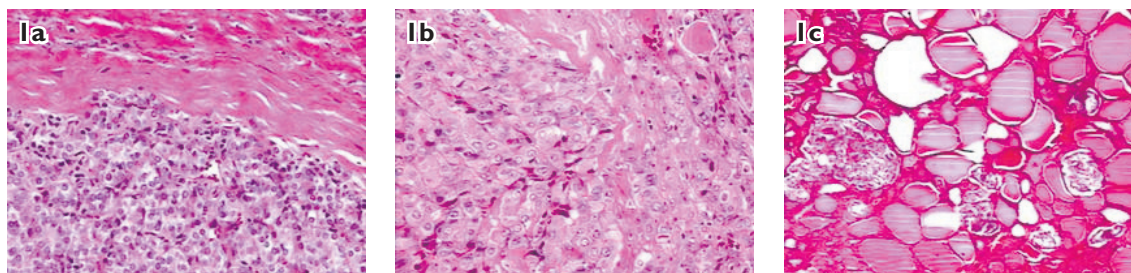
Department of  
Pathology,  
Hospital Raja  
Permaisuri Bainun,  
Jalan Hospital,  
Ipoh 30990,  
Malaysia

Karim N, MPath,  
FRCPath, FRCPA  
Consultant Pathologist  
and Chief of Pathology  
Services, Ministry of  
Health Malaysia

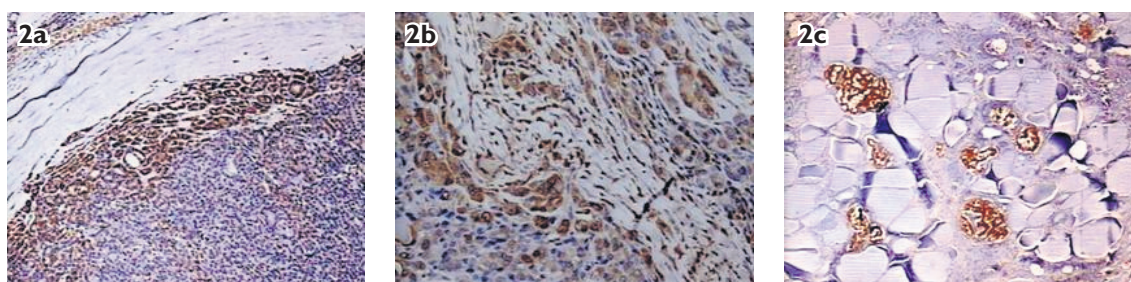
Department of  
Pathology,  
Sarawak General  
Hospital,  
Jalan Tun Ahmad  
Zaidi Adruce,  
Kuching 93586,  
Malaysia

Wong J, MD, MPath  
Consultant Pathologist

Correspondence to:  
Dr Than Than Htwe  
Tel: (60) 5243 2635  
Fax: (60) 5243 2636  
Email: ththan@rcmp.  
unikl.edu.my



**Fig. 1** Photomicrographs show (a & b) the cancerous thyroid lesion at the site, including adjacent stroma tissue (Haematoxylin & eosin,  $\times 200$ ); and (c) multifocal papillary thyroid cancer (Haematoxylin & eosin,  $\times 200$ ).



**Fig. 2** Photomicrographs show (a & b) a cancerous thyroid lesion with stronger expressions of galectin-3 in the advancing peripheral cells than in the cells that are centrally located (Galectin-3 immunostain,  $\times 200$ ); and (c) a strong expression of galectin-3 in the multifocal papillary thyroid cancer (Galectin-3 immunostain,  $\times 200$ ).

slides. Ethical approval was obtained from the Medical Research and Ethics Committee, Ministry of Health, Malaysia.

Blocks that were suitable for the study were selected by three pathologists. Tissue blocks with sufficient thyroid tissue, including capsular component, were selected. Immunohistochemical staining for galectin-3 was done only after the report on routine histopathological procedure using conventional haematoxylin and eosin (H & E) staining method was received. Formalin-fixed paraffin-embedded thyroid tissues were cut at 4  $\mu\text{m}$  thickness, mounted onto aminopropyltriethoxysilane-coated slides, and dried overnight at 56.7°C. The sections were dewaxed, rehydrated and boiled in phosphate-buffered saline (PBS) for one minute in order to allow antigen retrieval. Endogenous peroxidase activity was blocked by treating with 0.5% hydrogen peroxide in methanol for 15 minutes. The immunostaining procedure was performed on Lab Vision Autostainer 480 (Thermo Fisher Scientific Inc, Fremont, CA, USA). The slides were incubated with anti-galectin-3 monoclonal antibody (DAKO, Glostrup, Denmark). Antibodies were diluted in 1:50 concentration before being used. PBS was used for washing in each step. The slides were then covered in mouse serum blocking reagent for 15 minutes, followed by avidin and biotin blocking reagent for 15 minutes each. They were subsequently counterstained with haematoxylin and DPX mounted for microscopic evaluation. Colonic tissue was used as a positive and

negative control, where the primary antibody was omitted for the latter.

The slides were screened and observed by three pathologists who had no prior access to the H & E report of the specimens, so as to avoid bias. The morphology and cytological appearances were recorded. The evaluation was done by the semiquantitative scoring method as referenced by Ho et al.<sup>(17)</sup> Scoring was done based on the intensity of the staining characteristics on a scale of 1 to 3: a score of 1 for focal/weak staining; a score of 2 for moderate staining; and a score of 3 for strongly positive staining reaction. The average scoring among the three pathologists was calculated. Using this method, both the heterogeneous positive distributions and the different intensities of the staining could be simultaneously evaluated. All fields in a given specimen were individually scored, the percentage of fields determined, and the scores added to yield an average staining intensity score for the entire specimen. Scoring was done carefully on cells at the central part (C) of the lesion and cells at the periphery (P), adjacent to the neighbouring normal thyroid tissue. Descriptive analysis of the variables and statistical significances were calculated by non-parametric chi-square test using the Statistical Package for the Social Sciences version 11.0 (SPSS Inc, Chicago, IL, USA).

## RESULTS

A positive staining reaction was noted as intracytoplasmic

**Table I. Expression of galectin-3 in papillary and follicular thyroid carcinoma according to the staining intensity scored.**

	No. (%)		
	PTC	FCA	Total
Galectin-3 negative	1 (0.7)	3 (2.1)	4 (2.8)
Galectin-3 positive			
Score 1: Weak	0 (0.0)	21 (14.8)	21 (14.8)
Score 2: Moderate	18 (12.7)	9 (6.3)	27 (19.0)
Score 3: Strong	89 (62.7)	1 (0.7)	90 (63.4)
Total	108 (76.1)	34 (23.9)	142 (100)

PTC: papillary thyroid carcinoma; FCA: follicular carcinoma

brown staining within thyroid epithelial cells. It varied from diffuse extensive deposition to fine granularity and occasional membranous deposition toward the luminal aspect of the epithelial cells. A positive nuclear staining was also counted as positive staining reaction. Macrophages and red blood cells within vascular spaces that also showed cytoplasmic granular staining were taken in caution as interferences in the scoring. Adjacent normal and non-cancerous thyroid tissue showed scattered insignificant foci of positive staining reaction. A strongly positive staining intensity was noted, preferably in the peripheral cells adjacent to the neighbouring normal thyroid tissue (P) and a weaker staining intensity was noted in the cells at the central portion (C), as shown in Figs. 1 and 2. Table I shows four (2.8%) negative staining reactions out of the total 142 cases of cancerous lesions, of which 21 (14.8%) were weakly positive, 27 (19.0%) moderately positive and 90 (63.4%) strongly positive for galectin-3. Table II shows a differential expression of galectin-3 in PTC and FCA. Although eight (5.8%) PTC and three (2.2%) FCA had an equal staining distribution and intensity (C = P) in galectin-3 positivity, 99 (71.7%) PTC and 28 (20.3%) FCA expressed a higher uptake and staining reaction in the cells at the periphery (P) than cells that were located in the central portion of the tumour (C < P). This finding was highly significant ( $p = 0.001$ ) for cases with PTC compared to those with FCA on calculation using a non-parametric chi-square test.

## DISCUSSION

Galectin-3 has been regarded as a useful tumour marker for differentiating malignant tumours from benign nodules of the thyroid by many researchers. It has also been demonstrated that the expression of galectin-3 correlated with metastatic potential in certain malignancies, including thyroid cancers. From this study, particularly in cases with PTC, there was a significantly stronger expression ( $P = 0.001$ ) of galectin-3 in the

**Table II. Differential expression of galectin-3 in papillary and follicular thyroid carcinoma.**

	No. (%)		
	PTC	FCA	Total
C = P Galectin-3 positive*	8 (5.8)	3 (2.2)	11 (8.0)
C < P Galectin-3 positive**	99 (71.7)	28 (20.3)	127 (92.0)
Total	107 (77.5)	31 (22.5)	138 (100)

Note: Out of 142 cases, 4 (2.8%) of the cases were inconclusive and were thus not included in the calculation.

\* Galectin-3 positive staining in both central and peripheral epithelial cells. \*\* Galectin-3 positive staining in peripheral more than central epithelial cells.

PTC: papillary thyroid carcinoma; FCA: follicular carcinoma

advancing cancerous cells at the periphery of the lesion compared to the cells in the central portion that were lagging behind. According to a review by Takenaka et al,<sup>(12)</sup> it was suggested that galectin-3 plays a role in metastasis through the induction of angiogenesis via its carbohydrate-binding capacity.

Concerning cell-matrix interaction, galectin-3, as a non-integrin laminin-binding protein, has an indirect regulation on exciting integrin molecules.<sup>(12)</sup> The overexpression of galectin-3 at the peripherally located cells adjacent to the matrix may explain the recent assumption on the anoikis-resistant, anti-apoptotic property of galectin-3 in enhancing cell-matrix interaction and dissemination. Anoikis is a kind of apoptosis that is induced by disruption of cell-matrix interaction.<sup>(5,18,19)</sup> As tumour progression and metastasis are the most important factors of death in patients with malignant tumours, this finding may support the explanation of galectin-3 as an indicator for its metastasising potential and its expanding nature. Henceforth, it will be a useful biomarker in predicting the severity and intensity of metastasis, as well as the prognosis in the clinical management of thyroid malignancy.

Conversely, an inverse relationship between galectin-3 expression and the invasive potential was suggested in some studies.<sup>(3,16)</sup> The study by Kawachi et al reported that a decreased level of galectin-3 may aid the release of cancer cells from the primary lesions for invasion and metastasis. It was explained that decreased galectin-3 may loosen the connection of tumour cells from the primary lesions to the stroma, and this loosening may facilitate extracapsular penetration, vessel invasion and distant metastasis.<sup>(3)</sup> Türköz et al also observed a decreased level of galectin-3 overexpression at the invasive edges of PTC,<sup>(16)</sup> and reported that galectin-3 expression is more pronounced in the early stages of papillary carcinoma and decreases during tumour progression. In a literature review, Takenaka et al



explained that the levels of galectin-3 expression depend on the organ or tissue, suggesting that tumour or tissue-specific factor may modulate galectin-3 expression.<sup>(12)</sup> From the findings by Kawachi et al, it was assumed that galectin-3 works differently at different stages of thyroid neoplasm proliferation.<sup>(3)</sup> Thus, the level of galectin-3 expression seems to be dependent on the organ or tissue, and may be modulated by tumour or tissue-specific factors.

Moreover, the study by Kawachi et al demonstrated that primary lesions of PTC with metastasis contained a significantly higher concentration of galectin-3 than those without metastases, although the expression of galectin-3 was significantly decreased in metastatic lesions in the lymph nodes compared to their primary lesions.<sup>(3)</sup> This finding is in contrast to what we have observed, as shown in the high expression of multifocal local metastatic lesions in PTC (Figs. 1c & 2c). This could be due to the different ways in which galectin-3 works at different stages of thyroid neoplasm proliferation. Kawachi et al has observed that the increased expression of galectin-3 in thyroid tumour is related to the biological status or the morphogenesis of the neoplasm, and also the adhesion among tumour cells, or between tumour cells and the surrounding milieu.<sup>(3)</sup> We also believe that the difference in the neighbouring matrix may have some interactions, as the study by Kawachi et al was looking at the lymph nodes metastasis, while our finding was on a local invasion within thyroid tissue. Further investigation on the relationship between galectin-3 expression in local and distant metastasis is an important focus for future research.

Thus, based on the varied findings and reports on different types of malignancy, we concur with Kawachi et al that galectin-3 expression is related to cell-cell or cell-matrix adhesion, and also with Bresalier et al's report that upregulation of galectin-3 results in an increase in metastasis.<sup>(3,13)</sup> Our findings have revealed and proved the hypothesis that a differential expression of galectin-3 expression at the peripherally located cells close to the neighbouring milieu indicates the advancing property of galectin-3 in tumour progression, and is thus a useful marker when looking at the advancement of tumours, especially in PTC.

In summary, a significantly stronger expression ( $p = 0.001$ ) of galectin-3 was observed in the advancing follicular cells at the periphery of thyroid cancer lesions compared to the cells in the central portion that are lagging behind. This finding was more pronounced in PTC than in FCA. In conclusion, galectin-3 might be a useful tumour marker for thyroid cancers with respect to

tumour progression, although the precise mechanisms of galectin-3 regulation are yet unknown.

## ACKNOWLEDGEMENTS

This research was funded by the Universiti Kuala Lumpur short-term research grant (UniKL/CRPGS/str06077). We would like to express our sincere thanks to laboratory technologists, Mr Kadir Ithnin and Ms Ong Gaik Bei for their painstaking effort in conducting the laboratory work.

## REFERENCES

1. Barondes SH, Castronovo V, Cooper DN, et al. Galectins: a family of animal beta-galactoside-binding lectins. *Cell* 1994; 76:597-8.
2. Perillo NL, Marcus ME, Baum LG. Galectins: versatile modulators of cell adhesion, cell proliferation, and cell death. *J Mol Med* 1998; 76:402-12.
3. Kawachi K, Matsushita Y, Yonezawa S, et al. Galectin-3 expression in various thyroid neoplasms and its possible role in metastasis formation. *Hum Pathol* 2000; 31:428-33.
4. Kasai K, Hirabayashi J. Galectins: a family of animal lectins that decipher glycocodes. *J Biochem* 1996; 119:1-8.
5. Kim HR, Lin HM, Biliran H, Raz A. Cell cycle arrest and inhibition of anoikis by galectin-3 in human breast epithelial cells. *Cancer Res* 1999; 59:4148-54.
6. Matarrese P, Fusco O, Tinari N, et al. Galectin-3 overexpression protects from apoptosis by improving cell adhesion properties. *Int J Cancer* 2000; 85:545-54.
7. Dagher SF, Wang JL, Patterson RJ. Identification of galectin-3 as a factor in pre-mRNA splicing. *Proc Natl Acad Sci USA* 1995; 92:1213-7.
8. Inohara H, Akahani S, Raz A. Galectin-3 stimulates cell proliferation. *Exp Cell Res* 1998; 245:294-302.
9. Lin HM, Moon BK, Yu F, Kim HR. Galectin-3 mediates genistein-induced G(2)/M arrest and inhibits apoptosis. *Carcinogenesis* 2000; 21:1941-5.
10. Nangia-Makker P, Honjo Y, Sarvis R, et al. Galectin-3 induces endothelial cell morphogenesis and angiogenesis. *Am J Pathol* 2000; 156:899-909.
11. Raz A, Zhu DG, Hogan V, et al. Evidence for the role of 34-kDa galactoside-binding lectin in transformation and metastasis. *Int J Cancer* 1990; 46:871-7.
12. Takenaka Y, Fukumori T, Raz A. Galectin-3 and metastasis. *Glycoconj J* 2004; 15:543-9.
13. Bresalier RS, Mazurek N, Sternberg LR, et al. Metastasis of human colon cancer is altered by modifying expression of the beta-galactoside-binding protein galectin 3. *Gastroenterology* 1998; 115:287-96.
14. Song YK, Billiar TR and Lee YJ. Role of galectin-3 in breast cancer metastasis: involvement of nitric oxide. *Am J Pathol* 2002; 160:1069-75.
15. Miyazaki J, Hokari R, Kato S, et al. Increased expression of galectin-3 in primary gastric cancer and the metastatic lymph nodes. *Oncol Rep* 2002; 9:1307-12.
16. Türköz HK, Oksüz H, Yurdakul Z and Özcan D. Galectin-3 expression in tumor progression and metastasis of papillary thyroid carcinoma. *Endocr Pathol* 2008; 19:92-6.
17. Ho SB, Niehans GA, Lyftogt C, et al. Heterogeneity of mucin gene expression in normal and neoplastic tissues. *Cancer Res* 1993; 53:641-51.
18. Francis H. Disruption of epithelial cell-matrix interactions induces apoptosis. *J Cell Biol* 1994; 124:619-26.
19. Zhu Z, Sanchez-Sweatman O, Huang X, et al. Anoikis and metastatic potential of cloudman S91 melanoma cells. *Cancer Res* 2001; 61:1707-16.