

CME Article

Clinics in diagnostic imaging (I32)

Lodha A, Kamaluddeen M, Akierman A, Shroff M

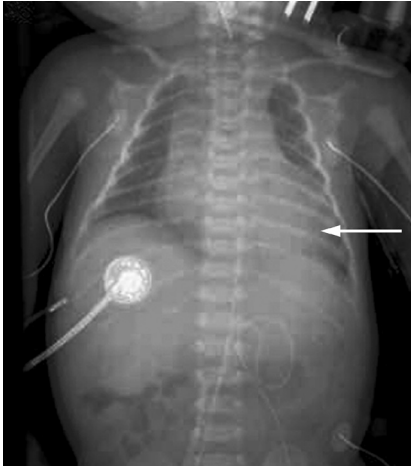


Fig 1. Chest radiograph (anterioposterior view) of a two-day-old neonate.

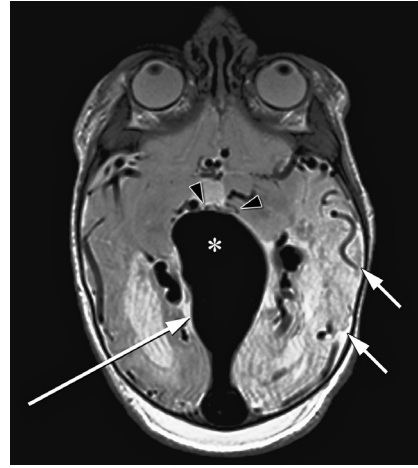


Fig 3. MR axial T-2 image of the newborn brain.

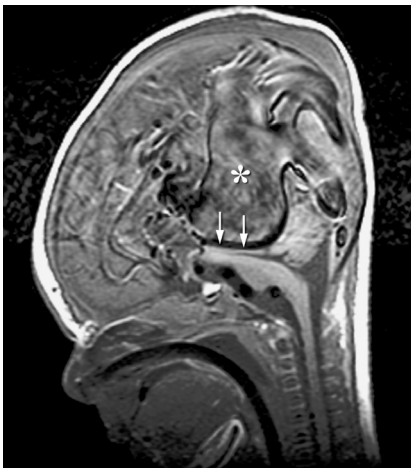


Fig 2. MR sagittal T-1 image of the newborn brain and brain stem.

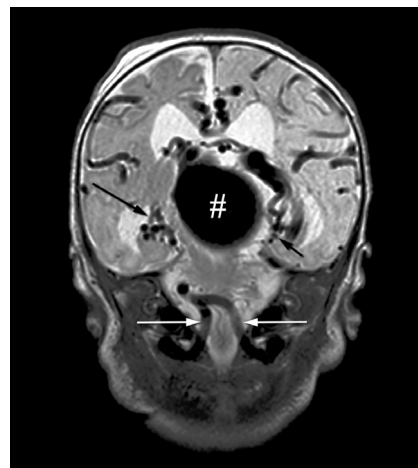


Fig 4. MR coronal T-2 image of the newborn brain.

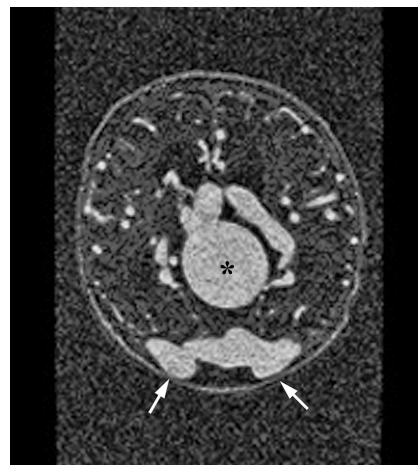


Fig 5. Axial gadolinium-enhanced MR angiography image of the newborn brain.

Department of
Paediatrics/
Neonatology,
Foothills
Medical Centre,
University of Calgary,
1403 29 Street NW,
Calgary,
AB T2N 2T9,
Canada

Lodha A, MD,
DM, MSc
Assistant Professor

Department of
Paediatrics/
Neonatology,
Peter Lougheed
Centre,
University of
Calgary,
3500 26 Avenue NE,
Calgary,
AB T1Y 6J4,
Canada

Kamaluddeen M, MD,
MRCP, FAAP
Clinical Assistant
Professor

Akierman A, MD,
FRCPC
Associate Professor

Section of
Neuroradiology,
Department of
Medical Imaging,
University of Toronto,
The Hospital for
Sick Children,
555 University Avenue,
Toronto,
ON M5G 1X8,
Canada

Shroff M, MD
Associate Professor

Correspondence to:
Dr Abhay Lodha
Tel: (1) 403 944 8163
Fax: (1) 403 944 4892
Email: abhay.lodha@
albertahealthservices.ca

CLINICAL PRESENTATION

A two-day-old, full-term male infant with a birth weight of 2,900 g was admitted to the neonatal intensive care unit with high output cardiac failure. The infant was found to be non-dysmorphic, with weight and length at the 50th percentile. There was no clinical evidence of sepsis. Physical examination was significant for hepatomegaly, active precordium, pansystolic murmur and hypotension requiring inotropic support. A cranial bruit was detected on auscultation. Complete blood count, electrolytes and blood gas were normal. Chest radiography and magnetic resonance (MR) imaging of the brain were performed (Figs.1–5). What do these images show? What is the diagnosis?

IMAGE INTERPRETATION

Chest radiograph (Fig. 1) shows cardiomegaly and pulmonary oedema due to heart failure. MR sagittal T-1 image (Fig. 2) shows the enlarged vein of Galen (*) and the straight sinus with heterogeneous signal due to complex and turbulent flow. Note the considerable mass effect on the brain stem (arrows). MR axial T-2 image (Fig. 3) shows an abnormal increased signal in the left hemisphere region (white arrows). Note the enlarged vein of Galen (*) draining into the enlarged straight sinus (long white arrow) and multiple small abnormal vessels at the sites of the arteriovenous fistulae (black arrowheads). MR coronal T-2 image (Fig. 4) shows the dilated vein of Galen (#), the hypertrophied vertebral arteries (white arrows) and multiple small arteriovenous fistulae (black arrows). Axial gadolinium-enhanced MR angiography (Fig. 5) at a superior level shows the aneurysmal dilatation of the vein of Galen (*), multiple dilated veins and enlarged lateral sinuses (arrows).

DIAGNOSIS

Vein of Galen malformation with high-output cardiac failure.

CLINICAL COURSE

Electrocardiogram and two-dimensional echocardiography were found to be normal. MR images of the brain (Figs 2–5) revealed a large vein of Galen malformation, extensive cerebral ischaemia and multiple cerebral infarcts. Electroencephalogram showed seizure activity in the frontal, central and occipital regions with discontinuous background and left hemisphere attenuation. Due to the extensive network of the feeding vessels to the arteriovenous (AV) malformation precluding surgical treatment and the associated global ischaemic brain damage, a decision was made to provide palliative care.

DISCUSSION

Cyanotic or acyanotic heart disease, birth asphyxia, severe anaemia, fluid overload, sepsis, hypoglycaemia, hypocalcaemia and systemic AV fistula are the common aetiological factors responsible for heart failure in neonates.⁽¹⁾ Patent ductus arteriosus remains the most common cause of heart failure in premature infants.⁽¹⁾

MR imaging of the brain is an essential investigation to establish an obscure cause of cardiac failure in neonates when no obvious cardiac cause is present. Central nervous system examination should be an integral part of the management of heart failure in neonates, principally to rule out AV fistula, such as vein of Galen malformations (VGAM). In this situation, judicious and

timely management based on the aetiology is the key to survival and preclusion of morbidity. Seizures and mental retardation are the major symptoms observed if the correction of the AV shunt is not carried out in time.⁽²⁾ The signs of cardiac failure include tachypnoea, tachycardia, diaphoresis, failure to thrive or excessive weight gain, poor feeding, lethargy, hepatomegaly, periorbital oedema and cardiomegaly on chest radiography. The most common acute presentation may be cardiovascular collapse, as neonates have little myocardial reserve and a limited ability for a compensatory increase in cardiac output.⁽¹⁾

Treatment consists of meticulous attention to fluid and sodium intake, adequate calorie intake and pharmacotherapy, which conventionally includes diuretics, digoxin and captopril. The management of high output cardiac failure due to AV shunts in the brain can be very challenging in the newborn.⁽¹⁾ AV malformation consists of multiple feeding arteries, principally the anterior and posterior choroidal arteries as well as the anterior cerebral artery draining directly into an enlarged venous pouch.⁽³⁾ VGAM should be distinguished from aneurysmal dilatation of the true vein of Galen caused by an adjacent brain AV malformation, which entails a very high risk of haemorrhage.⁽⁴⁾ The initial management of VGAM is a conservative approach. An embolisation procedure in a neonate is fraught with complications and where possible, the infant is treated medically for cardiac failure until the age of five or six months, with regular outpatient assessment.⁽⁴⁾ Elective embolisation involves obliterating the AV shunts with glue by the arterial route. Surgery has little role in the modern-day treatment of VGAM. Untreated VGAM carries a poor prognosis and is always fatal, but it is equally important to recognise that treatment may be inappropriate in some cases,⁽⁴⁾ as was the case in our patient.

In conclusion, high-flow AV shunts of the brain in neonates necessitate early and appropriate diagnostic tests like MR imaging, and a multidisciplinary team approach that consists of neonatologists, interventional radiologists, paediatric cardiologists, neurologists and ancillary staff. MR imaging of the brain should be considered in the diagnostic evaluation of all cases of cardiac failure where no obvious cardiac condition exists.

ABSTRACT

A two-day-old, full-term male infant was admitted to the neonatal intensive care unit with heart failure. He was found to be non-dysmorphic, with no clinical evidence of sepsis. Physical examination was significant for

hepatomegaly, active precordium, pansystolic murmur and hypotension requiring inotropic support. A cranial bruit was detected on auscultation. Chest radiography revealed cardiomegaly and pulmonary oedema due to heart failure. Electrocardiogram and two-dimensional echocardiography were normal. Magnetic resonance imaging of the brain showed a large vein of Galen malformation, extensive cerebral ischaemia and multiple cerebral infarcts. This case illustrates the importance of auscultation of the cranium to rule out vein of Galen malformation, a potential cause of high-output cardiac failure in neonates in the absence of other common causes of heart failure.

Keywords: cardiac failure, vein of Galen malformations

Singapore Med J 2010;51(11):896-899

REFERENCES

1. Hellmann J, Millman G, Lodha A. Neonatology. In: Laxer R, Lee Ford-Jones E, Friedman J, Gerstle J, eds. The Hospital for Sick Children Atlas of Pediatrics. Philadelphia: Current Medicine, 2005.
2. Lasjaunias PL, Chng SM, Sachet M, et al. The management of vein of Galen aneurysmal malformations. *Neurosurgery* 2006; 59:S184-94; discussion S3-13.
3. Raybaud CA, Strother CM, Hald JK. Aneurysms of the vein of Galen: embryonic considerations and anatomical features relating to the pathogenesis of the malformation. *Neuroradiology* 1989; 31:109-28.
4. Bhattacharya JJ, Thammaroj J. Vein of galen malformations. *J Neurol Neurosurg Psychiatry* 2003; 74 Suppl 1:i42-4.

SINGAPORE MEDICAL COUNCIL CATEGORY 3B CME PROGRAMME
Multiple Choice Questions (Code SMJ 201011B)

	True	False
Question 1. What is the cause of heart failure in this neonate?		
(a) Sepsis.	<input type="checkbox"/>	<input type="checkbox"/>
(b) Congenital heart disease.	<input type="checkbox"/>	<input type="checkbox"/>
(c) Fluid overload.	<input type="checkbox"/>	<input type="checkbox"/>
(d) Vein of Galen malformation.	<input type="checkbox"/>	<input type="checkbox"/>
Question 2. Signs of heart failure in neonates include:		
(a) Tachypnoea.	<input type="checkbox"/>	<input type="checkbox"/>
(b) Tachycardia.	<input type="checkbox"/>	<input type="checkbox"/>
(c) Diaphoresis and lethargy.	<input type="checkbox"/>	<input type="checkbox"/>
(d) Excessive weight gain and poor feeding.	<input type="checkbox"/>	<input type="checkbox"/>
Question 3. The diagnosis of vein of Galen malformation is confirmed by the following tests:		
(a) Complete blood counts.	<input type="checkbox"/>	<input type="checkbox"/>
(b) Electrocardiography.	<input type="checkbox"/>	<input type="checkbox"/>
(c) Head ultrasonography.	<input type="checkbox"/>	<input type="checkbox"/>
(d) Magnetic resonance imaging of the brain.	<input type="checkbox"/>	<input type="checkbox"/>
Question 4. The most common cause of heart failure in premature infants is:		
(a) Patent ductus arteriosus.	<input type="checkbox"/>	<input type="checkbox"/>
(b) Sepsis.	<input type="checkbox"/>	<input type="checkbox"/>
(c) Hypoglycaemia.	<input type="checkbox"/>	<input type="checkbox"/>
(d) Congenital heart disease.	<input type="checkbox"/>	<input type="checkbox"/>
Question 5. In the event of an untreated arteriovenous shunt, the late symptoms are:		
(a) Seizures and mental retardation.	<input type="checkbox"/>	<input type="checkbox"/>
(b) Intraventricular haemorrhage.	<input type="checkbox"/>	<input type="checkbox"/>
(c) Periventricular leukomalacia.	<input type="checkbox"/>	<input type="checkbox"/>
(d) Brain tumour.	<input type="checkbox"/>	<input type="checkbox"/>

Doctor's particulars:

Name in full: _____

MCR number: _____ Specialty: _____

Email address: _____

SUBMISSION INSTRUCTIONS:

(1) Log on at the SMJ website: <http://www.sma.org.sg/cme/smj> and select the appropriate set of questions. (2) Select your answers and provide your name, email address and MCR number. Click on "Submit answers" to submit.

RESULTS:

(1) Answers will be published in the SMJ January 2011 issue. (2) The MCR numbers of successful candidates will be posted online at www.sma.org.sg/cme/smj by 7 January 2011. (3) All online submissions will receive an automatic email acknowledgment. (4) Passing mark is 60%. No mark will be deducted for incorrect answers. (5) The SMJ editorial office will submit the list of successful candidates to the Singapore Medical Council.

Deadline for submission: (November 2010 SMJ 3B CME programme): 12 noon, 31 December 2010.