

## CME Article

# Common congenital hand conditions

Chong A K S

## ABSTRACT

**Congenital hand deformities are common but most of these conditions are minor. Polydactyly and syndactyly are the commonest congenital hand conditions for which treatment is sought. The presence of congenital hand deformities has a significant psychological impact on both the parents and child, and in severe cases, can significantly affect limb function. This article reviews the more common hand conditions so that non-specialist physicians can diagnose them and understand their management principles.**

**Keywords:** congenital hand deformity, polydactyly, syndactyly, trigger thumb

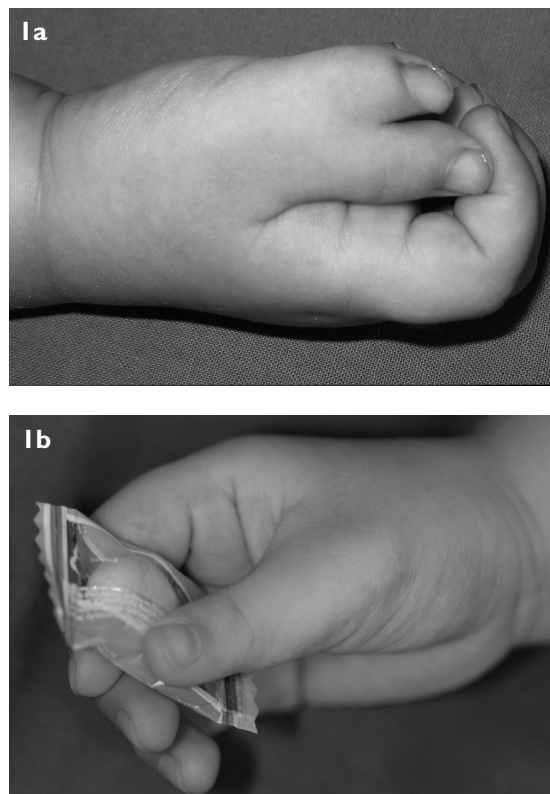
*Singapore Med J 2010;51(12):965-971*

## INTRODUCTION

Congenital hand conditions are common, and estimated to occur in at least 2.3 per 1,000 of total births.<sup>(1)</sup> Many of these conditions are relatively minor and do not affect function. However, they may be noticed by the parents and others who may seek advice about them. Some congenital anomalies are severe and affect function. In addition, the appearances of the deformities have significant psychological impact on both the parents and child. This pictorial essay aims to demonstrate the more common congenital hand conditions, providing key features in their recognition and general management. A widely used classification system for these deformities has been developed by the International Federation for Societies for Surgery of the Hand.<sup>(2)</sup> A more comprehensive review is available should the reader require additional information.<sup>(3)</sup>

## PATHOGENESIS AND CAUSATION

The causes of congenital hand anomalies are very varied. They may occur sporadically or may be the result of various inherited genetic anomalies. Environmental factors, diet, infections and other causes are much less common. The hand develops at between four to eight weeks of intrauterine life during embryogenesis, and most anomalies have already developed by the time the pregnancy is diagnosed. Checking for a history of congenital anomalies in the family of an affected child is helpful, and a child with a congenital hand anomaly



**Fig. 1** Thumb duplication is the commonest form of polydactyly in Asians. Photographs show (a) the two duplicates which are invariably each smaller in size than a normal contralateral thumb; and (b) the same patient using the reconstructed thumb, which is the dominant side.

should be screened for other associated systemic anomalies, an example of which is VACTERL syndrome.

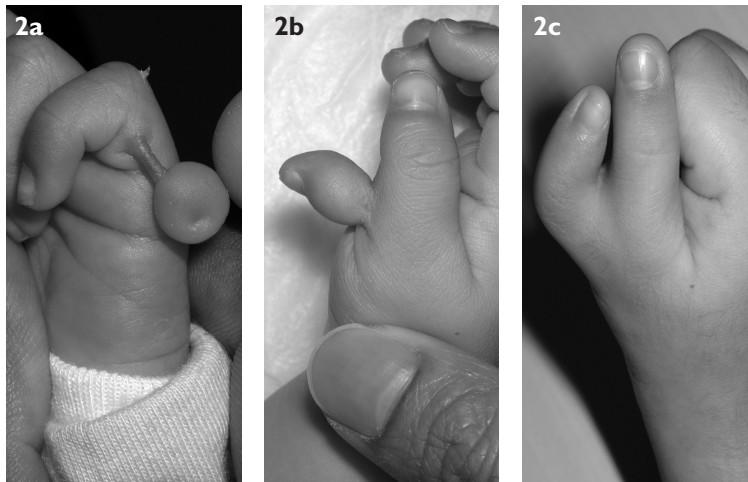
## POLYDACTYLY

An extra digit or polydactyly is one of the more common congenital hand conditions encountered in clinical practice.<sup>(4)</sup> The commonest form of polydactyly is that of thumb duplication (Fig. 1). There are variations in the size and form of the duplicated digit (Fig. 2). It is more accurate to view thumb polydactyly as a “splitting” of a digit rather than a true digit. This is because the two duplicates are each almost invariably smaller than that of a normal thumb. The duplication can be as distal as the distal phalanx or as proximal as the metacarpal. In a considerable number of cases, the duplicate is a floppy one. Less common forms of duplication in Asians are post-axial or ulnar-sided polydactyly and central polydactyly. In thumb polydactyly, reconstruction is usually offered. Besides the obvious cosmetic improvement, surgery also

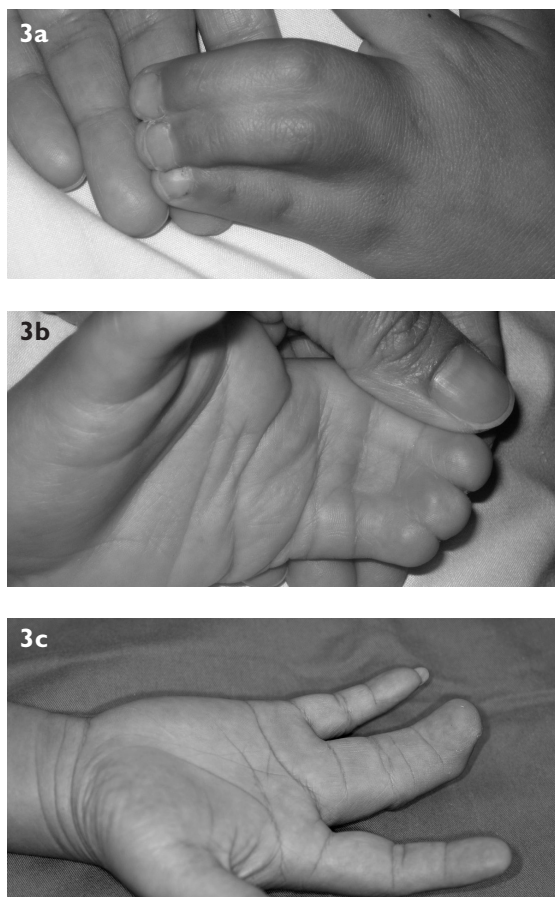
Department of Hand and Reconstructive Microsurgery, National University Hospital, IE Kent Ridge Road, NUHS Tower Block, Level 11, Singapore 119228

Chong AKS, MBBS, MMed, FAMS Consultant

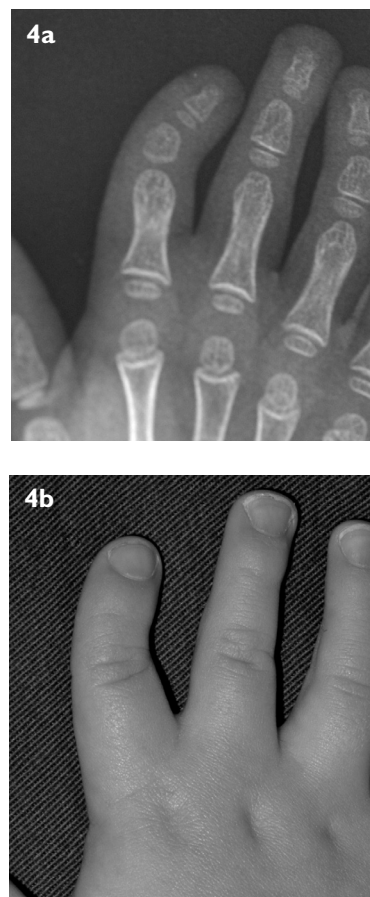
**Correspondence to:** Dr Alphonsus KS Chong  
Tel: (65) 6772 5549  
Fax: (65) 6773 2558  
Email: cfscks@nus.edu.sg



**Fig. 2** Variants of polydactyly. Photographs show (a) post-axial (ulnar-sided) polydactyly; (b) a form of thumb duplication with a soft tissue stalk attached to the main duplicate; and (c) another example of a typical form of thumb duplication.



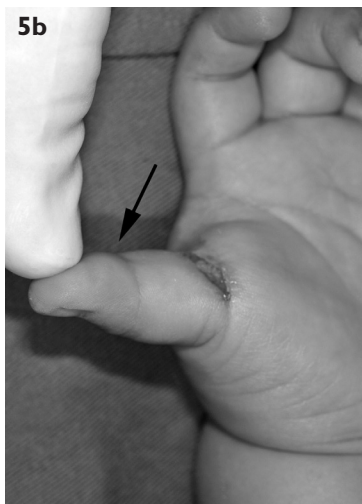
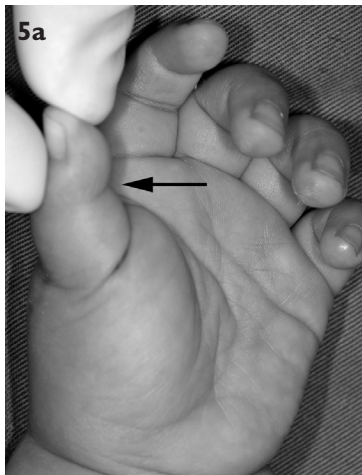
**Fig. 3** Photographs show (a & b) an example of complete simple syndactyly, where the involvement is all the way from the web to the fingertips; and (c) an adult with untreated simple syndactyly, who has a full range of motion of the two digits without deformity and was able to work as a driver.



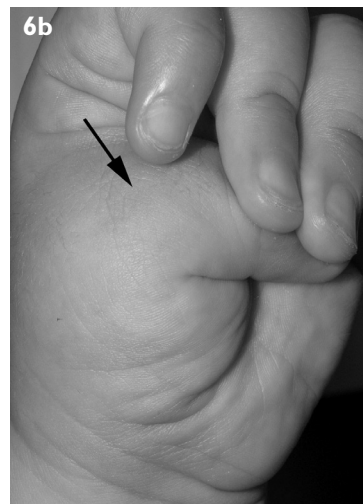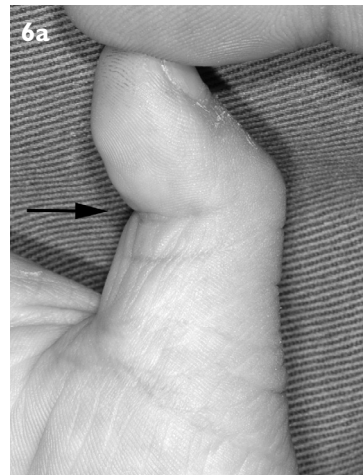**Fig. 4** (a) Radiograph and (b) clinical photograph show clinodactyly affecting the index finger. Notice the ulnar deviation of the finger and the trapezoidal shape of the middle phalanx. While the little finger is most commonly affected, other fingers can be involved too.

places the retained digit in a more functional position, and the reconstruction aims to enhance the stability of an often unstable metacarpophalangeal joint. At the time of diagnosis, it is useful to reassure the parents that the

deformity is not caused by anything done or not done by the parents. This applies for most deformities, and helps assuage any anxiety or possible guilt on the part of the parents. In general, surgery is done after six months, when



**Fig. 5** Trigger release. (a) Photograph shows the interphalangeal joint of the thumb (arrow) locked in a flexed position preoperatively. Surgical release of the AI pulley of the flexor tendon was performed after a failed trial of conservative treatment. (b) The flexor tendon sheath is approached through a cosmetic skin crease incision at the base of the thumb. Note that the interphalangeal joint of the thumb can now be fully extended after the surgical release (arrow).



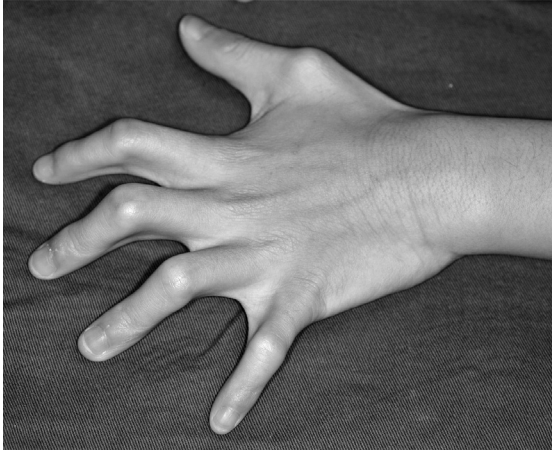**Fig. 6** Trigger and clasped thumb. (a) The characteristic position of the trigger thumb is a flexed position of the thumb interphalangeal joint (arrow). The metacarpophalangeal joint of the affected thumb is normal and can be fully extended. (b) In the clasped thumb, the digit is held "clasped" in the palm, hence the name. The metacarpophalangeal joint is held flexed (arrow), and the interphalangeal joint is not affected. However, the thumb, including the metacarpophalangeal joint, can usually be passively extended.

general anaesthesia is safer and the child's structures are better developed. While there is no real upper limit to surgery, most surgeons would prefer to do reconstruction sometime between six months and two years of age.

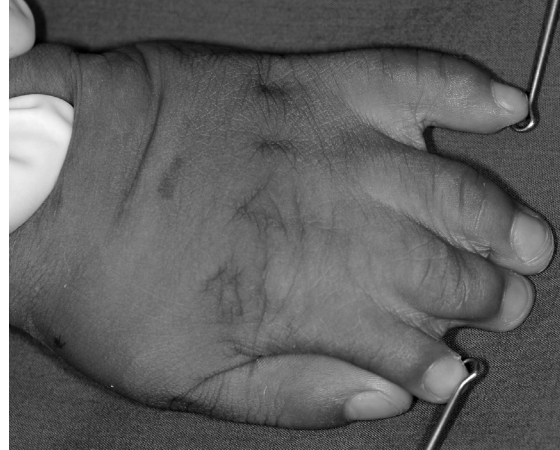### SYNDACTYLY

Syndactyly refers to an abnormal linkage between adjacent digits (Fig. 3). It may occur on one or both sides. Syndactyly occurs most commonly between the middle and ring fingers. In milder cases, this involves only the skin and soft tissue, and is called simple syndactyly. In more severe cases, there is a bridging between the bones and nails of the adjacent digits. This is called complex syndactyly. The condition results from a failure of digital separation from apoptosis during embryogenesis. Syndactyly is also classified according to the extent of involvement. In

complete syndactyly, the linkage spans from the web space to the fingertips. In incomplete syndactyly, the linkage stops at a point proximal to the fingertip. This deformity may occur sporadically, in families, or in association with a syndrome. Other deformities that may be found in cases of syndactyly include webbing of the toes, brachydactyly, spinal and cardiac abnormalities. Surgery to separate the digits aims to produce a hand with as many stable and functionally independent fingers as possible. Separation is done earlier if the ring and little fingers or the index finger and thumb are involved, as the differential longitudinal growth rates between the digits will lead to bone and joint deformity if left untreated. Staged procedures are required in multi-digit syndactyly if a finger is to be separated from the adjoining fingers on both sides in order to avoid compromising the vascularity of the fingers.



**Fig. 7** Camptodactyly. Note the flexion deformity of the fingers. In a typical case, the little finger is affected. However, other fingers or multiple fingers can also be affected.



**Fig. 8** Photograph shows one form of symbrachydactyly. Note the short index, middle, ring and small fingers with incomplete syndactyly between them.

### CLINODACTYLY

Clinodactyly describes an angulation of the finger in the radioulnar or coronal plane (Fig. 4). Angulations of less than ten degrees are generally considered the upper limit of normal variation. The little finger, particularly the middle phalanx, which may be triangular or trapezoidal in shape, is most commonly involved, with an angulation at the distal interphalangeal joint. This deformity is usually bilateral. It is quite common in otherwise normal children and rarely causes any functional limitations. All that is usually required is reassurance to the child and parents that the deformity will not worsen.

Familial clinodactyly is regarded as an autosomal dominant trait with variable expressibility and incomplete penetrance, and is generally not associated with other systemic abnormalities. Clinodactyly can also be found in several genetic disorders, such as Down syndrome, Apert syndrome and Rubinstein-Taybi syndrome. In severe deformities, surgery may be performed to improve the appearance.

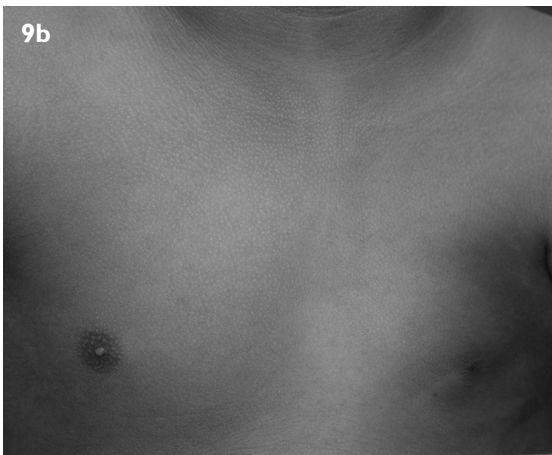
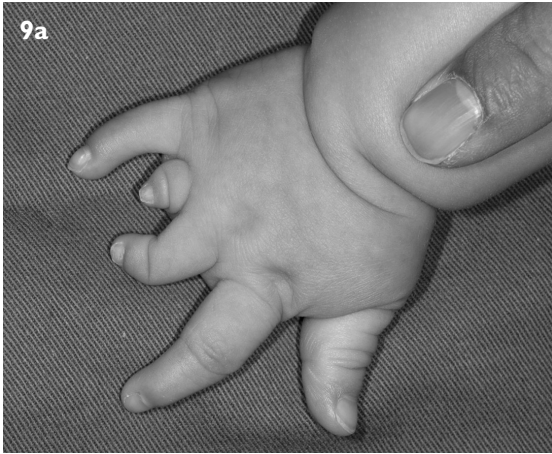### PAEDIATRIC TRIGGER THUMB

This condition presents as a flexion deformity of the interphalangeal joint of the thumb (Fig. 5). It is more commonly unilateral. Unlike adult trigger thumbs, it does not usually present as triggering per se, but with a flexion deformity. One important differential diagnosis is that of a clasped thumb (Fig. 6). In the latter, the flexion deformity is at the level of the metacarpophalangeal joint and not the interphalangeal joint. The cause of the pathology in trigger thumb is a nodular swelling of the tendon preventing it from gliding into the A1 pulley of the flexor tendon sheath. Unlike in adults, trigger fingers (excluding thumb) are

uncommon in children. If they do occur, the pathology is often due to anomalies of the flexor tendon and not the usual fibrous metaplasia seen in adults. Some controversies exist regarding whether the condition is acquired or congenital. The balance of the evidence lies in favour of an acquired condition,<sup>(5)</sup> although there is a familial tendency in some cases. In more than 60% of cases, the condition will resolve spontaneously, but this requires about 48 months of waiting.<sup>(6)</sup> As an alternative, surgical release is highly effective and has limited morbidity.<sup>(7)</sup>

### CAMPTODACTYLY

Camptodactyly is a non-traumatic flexion contracture of the proximal interphalangeal joint (Fig. 7). It usually affects the small finger and can be bilateral. In some cases, multiple digits are involved. Two forms of camptodactyly have been described based on the time of onset: the first are those presenting in early childhood – termed the congenital form, and the other group presents in adolescence. The contracture may be fixed or passively correctable. The pathoanatomy in camptodactyly is controversial. It may be due to abnormal insertions of the lumbrical muscle, flexor digitorum superficialis tendon, deficient extensors, or a combination of the above. Mild cases with loss of extension of about 30 degrees only cause a cosmetic deficit and do not require treatment. The treatment for more severe cases is controversial. Long-term splinting has been advocated by some. This requires high compliance and long-term treatment. Surgery is usually done after failed conservative treatment. Exploration of the digit is done to find and release all offending structures and the joint, if necessary. However, the outcome of surgery is not always predictable.



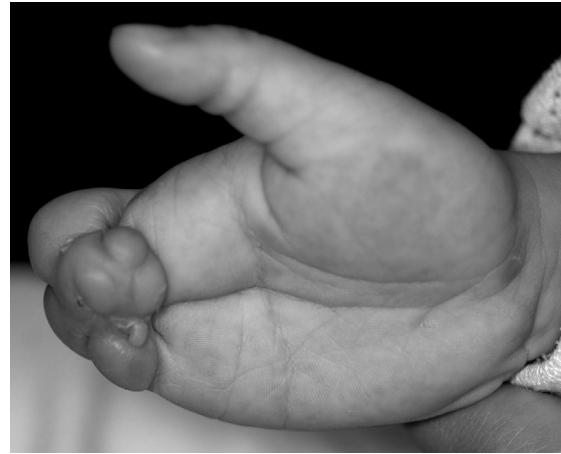**Fig. 9** Photographs show (a) another form of symbrachydactyly, where the middle, ring and small fingers are shortened and malformed; there is no syndactyly in this case; and (b) a patient with Poland's syndrome and symbrachydactyly showing deficient pectoralis major muscle on the left side.

### SYMBRACHYDACTYLY

Symbrachydactyly originally referred to an anomaly with both syndactyly and brachydactyly (short fingers) (Fig. 8). However, this term is now applied to a spectrum of hand malformations, ranging from those described above to severe deformities like congenital forearm amputations with rudimentary digits (Fig. 9). Symbrachydactyly is typically unilateral and sporadic in occurrence. These anomalies often occur in Poland's syndrome, where there is an associated pectoral muscle defect (Fig. 9). Treatment for the condition needs to be individualised, as the deformity varies considerably in severity. Syndactyly, which is usually incomplete and simple, can be divided as per conventional syndactyly.

### THUMB HYPOPLASIA

Thumb hypoplasia can occur in isolation, or more commonly with a deficiency of the radial side of the upper limb (radial club hand).<sup>(8)</sup> On occasion, thumb hypoplasia may present as a limited range of motion



**Fig. 10** Photograph shows a severe form of constriction ring syndrome with amputations and fusion of the distal ends of the digits.

at the interphalangeal joint. This is due to abnormal interconnections between the flexor pollicis longus and extensor pollicis longus tendon. The severity of hypoplasia ranges significantly. In the mildest form, there is a slight slimness of the thumb compared to the other side. However, the bones, joints and thenar muscles are well-formed, so the only deficiency is a mild cosmetic defect. In more severe cases, there is poor development of the thumb bones, joints and muscle, such that the thumb is small, unstable and lack appropriate motors for opposition. In the severest cases, the thumb can be vestigial on a soft tissue stalk or completely absent. In the mildest form, no treatment is necessary. For the more severe cases, reconstruction includes tendon transfers for opposition. In the severest cases, pollicisation of the index finger (i.e. transferring the index finger to the position of the thumb to allow opposition) is generally performed.

### CONSTRICTION RING SYNDROME

This condition is also known as the amniotic band syndrome or Streeter's disease. It is marked by constrictions or bands around digits or limbs. In the more severe cases, the part distal to the constriction may be amputated or oedematous, and acrosyndactyly is also seen. The aetiology of this condition is still controversial. One widely accepted theory is that it is caused by the constriction of the digits from amniotic bands, hence the name. Release of the constrictions is not urgently required unless there is evidence of vascular compromise distally, such as an oedematous or ischaemic digit. Other techniques of reconstruction, such as toe transfers or lengthening procedures, may be required if the amputations are significant.

**CONCLUSION**

Many congenital hand conditions are minor and require simple or no treatment. In the more severe cases, they offer extreme challenges to the hand surgeon for reconstruction. At either end of the spectrum, the condition can cause extreme distress to the patient and parents. Prompt recognition of the problem allows the physician to provide reassurance in minor cases, and prompt referral for specialist treatment, when required.

**REFERENCES**

1. Lamb DW, Wynne-Davies R. Incidence and genetics. In: Buck-Gramcko D, ed. *Congenital Malformations of the Hand and Forearm*. London: Churchill Livingstone, 1998: 21-7.
2. De Smet L. Classification for congenital anomalies of the hand: the IFSSH classification and the JSSH modification. *Genet Couns* 2002; 13:331-8.
3. Kozin SH. Upper-extremity congenital anomalies. *J Bone Joint Surg Am* 2003; 85-A:1564-76.
4. Cooney WP, Wolf J, Holtkamp K, Dobyns JH. Congenital duplication of the thumb. *Handchir Mikrochir Plast Chir* 2004; 36:126-36.
5. Kikuchi N and Ogino T. Incidence and development of trigger thumb in children. *J Hand Surg Am* 2006; 31:541-3.
6. Baek GH, Kim JH, Chung MS, et al. The natural history of pediatric trigger thumb. *J Bone Joint Surg Am* 2008; 90:980-5.
7. Tan AH, Lam KS, Lee EH. The treatment outcome of trigger thumb in children. *J Pediatr Orthop B* 2002; 11:256-9.
8. Tay SC, Moran SL, Shin AY, Cooney WP 3rd. The hypoplastic thumb. *J Am Acad Orthop Surg* 2006; 14:354-66.

**SINGAPORE MEDICAL COUNCIL CATEGORY 3B CME PROGRAMME**  
**Multiple Choice Questions (Code SMJ 201012B)**

	True	False
<b>Question 1.</b> Regarding congenital hand conditions in general:		
(a) Most are relatively minor.	<input type="checkbox"/>	<input type="checkbox"/>
(b) The commonest conditions for which treatment is sought are syndactyly and polydactyly.	<input type="checkbox"/>	<input type="checkbox"/>
(c) At the time of birth, newborns with congenital hand anomalies should be examined for other associated anomalies.	<input type="checkbox"/>	<input type="checkbox"/>
(d) Surgery for these conditions should be done as soon as possible.	<input type="checkbox"/>	<input type="checkbox"/>
<b>Question 2.</b> In polydactyly:		
(a) The most commonly affected digit is the thumb.	<input type="checkbox"/>	<input type="checkbox"/>
(b) Surgery is a simple excision of the unwanted digit.	<input type="checkbox"/>	<input type="checkbox"/>
(c) Most are due to an <i>in utero</i> infection.	<input type="checkbox"/>	<input type="checkbox"/>
(d) The duplicated thumb is always larger than the normal side.	<input type="checkbox"/>	<input type="checkbox"/>
<b>Question 3.</b> In syndactyly:		
(a) There is never involvement of the underlying bone and joint.	<input type="checkbox"/>	<input type="checkbox"/>
(b) Surgery is not required.	<input type="checkbox"/>	<input type="checkbox"/>
(c) It may be classified as complex or simple.	<input type="checkbox"/>	<input type="checkbox"/>
(d) The web reaches all the way to the fingertip in incomplete syndactyly.	<input type="checkbox"/>	<input type="checkbox"/>
<b>Question 4.</b> In trigger thumb:		
(a) Most cases require immediate surgical release.	<input type="checkbox"/>	<input type="checkbox"/>
(b) Patients present with “clicking” or “triggering” of the thumb.	<input type="checkbox"/>	<input type="checkbox"/>
(c) Parents usually notice a flexion deformity of the thumb.	<input type="checkbox"/>	<input type="checkbox"/>
(d) It is due to a nodular swelling of the flexor tendon.	<input type="checkbox"/>	<input type="checkbox"/>
<b>Question 5.</b> Which of the following statements are true:		
(a) Camptodactyly is a non-traumatic flexion contracture of the proximal interphalangeal joint.	<input type="checkbox"/>	<input type="checkbox"/>
(b) Symbrachydactyly is typically bilateral and hereditary.	<input type="checkbox"/>	<input type="checkbox"/>
(c) Thumb hypoplasia occurs as an isolated deformity.	<input type="checkbox"/>	<input type="checkbox"/>
(d) Clinodactyly describes an angulation of the finger in the radioulnar plane.	<input type="checkbox"/>	<input type="checkbox"/>

**Doctor's particulars:**

Name in full: \_\_\_\_\_

MCR number: \_\_\_\_\_ Specialty: \_\_\_\_\_

Email address: \_\_\_\_\_

**SUBMISSION INSTRUCTIONS:**(1) Log on at the SMJ website: <http://www.sma.org.sg/cme/smj> and select the appropriate set of questions. (2) Select your answers and provide your name, email address and MCR number. Click on “Submit answers” to submit.**RESULTS:**(1) Answers will be published in the SMJ February 2011 issue. (2) The MCR numbers of successful candidates will be posted online at [www.sma.org.sg/cme/smj](http://www.sma.org.sg/cme/smj) by 7 February 2011. (3) All online submissions will receive an automatic email acknowledgment. (4) Passing mark is 60%. No mark will be deducted for incorrect answers. (5) The SMJ editorial office will submit the list of successful candidates to the Singapore Medical Council.**Deadline for submission: (December 2010 SMJ 3B CME programme): 12 noon, 31 January 2011.**