

Hypokalaemic paralysis secondary to distal renal tubular acidosis as the presenting symptom of systemic lupus erythematosus

Gera C, Mohapatra D, Calton N

ABSTRACT

We report hypokalaemic quadriparesis presenting in a 43-year-old woman. Evaluation revealed hypokalaemic quadriparesis secondary to underlying distal renal tubular acidosis, also known as type I RTA. Four years after the diagnosis of RTA, the patient developed joint pain, and investigation revealed systemic lupus erythematosus with lupus nephritis. RTA is one of the very rare presentations of systemic lupus erythematosus. Thus, tubular dysfunction should be carefully assessed in patients with systemic lupus erythematosus. Similarly, patients with RTA should be evaluated for underlying lupus. Our patient was successfully treated with mycophenolate mofetil and steroids.

Keywords: hypokalemic paralysis, lupus nephritis, renal tubular dysfunction, systemic lupus erythematosus, type I RTA

Singapore Med J 2011;52(1):e1-e3

INTRODUCTION

Hypokalaemia that is severe enough to cause muscle paralysis is rarely seen and has been reported in 28%–53% of patients with type I renal tubular acidosis (RTA).⁽¹⁾ Type I RTA or distal renal tubular acidosis (dRTA) is a disorder of renal tubular acidification that is out of proportion to the reduction in glomerular filtration rate, and is characterised by hyperchloraemic metabolic acidosis with a normal serum anion gap. Other than the hereditary and idiopathic varieties, most cases of dRTA are secondary to systemic disorders such as Sjogren's syndrome, hyperglobulinaemia, chronic active hepatitis or lupus.⁽²⁾ Systemic lupus erythematosus (SLE) is an uncommon disease. Its renal involvement in the form of glomerulonephritis is common, but tubular dysfunction is rare. This unusual presentation of SLE was first presented by Fortenberry and Kenney in 1991,⁽³⁾ and infrequent cases have been reported in the literature ever since. We present the case of a woman who was admitted with acute onset hypokalaemic quadriparesis. Investigations revealed

underlying dRTA. Four years after the initial presentation, the patient was diagnosed with Class V lupus nephritis, which was successfully treated with mycophenolate mofetil (MMF).

CASE REPORT

A 43-year-old woman presented with pain in multiple joints. She complained of pain and swelling in both the small and large joints, along with inflammatory back pain. She experienced this pain almost throughout the day, but it was worse in the morning. The patient also had significant morning stiffness and daytime fatigue. There was no fever, burning in the urine, cough, abdominal pain or vomiting. The patient was diagnosed with RTA and received regular follow-up treatments at the nephrology department.

Four years before her current presentation, the patient had progressive weakness in all four limbs; it started in one limb, but progressed to all four limbs within a few hours. She had given a history of multiple episodes of vomiting eight hours prior to that admission, and her past medical record from 2005 revealed that she was conscious and oriented on admission. Her eye movements were normal and there was no facial asymmetry. However, the patient's neck flexion and extension were weak, and her muscle strength was also very poor (flicker 1/5) in all the muscle groups except for wrist flexor and extensor, where it was slightly better (grade 2/5). The patient's muscle strength was best on her left elbow flexor and extensor, where she was able to move them against gravity (grade 3/5). Deep tendon reflexes were intact and planter reflex was flexor bilateral. The rest of the physical examination was normal. Investigations revealed mild renal failure: blood urea 60 mg/dl, serum creatinine 1.4 mg/dl, hypokalaemia 1.8 mEq/L, hyperchloraemic metabolic acidosis (chloride 110 mEq/L, arterial blood pH 7.249), hypothyroidism (thyroid-stimulating hormone 10.3 U) and alkaline urine (urinary pH 8.0). Radiograph of the abdomen did not show any nephrocalcinosis. In view of the normal anion gap acidosis (12 mmol/L), alkaline urine (urinary pH 8.0), low serum potassium (1.8 mEq/L), absence of Faconi's syndrome and the

Department of
Medicine,
Christian Medical
College and Hospital,
Ludhiana 141008,
Punjab,
India

Gera C, MD
Associate professor

Department of
Pathology

Mohapatra D, MD
Associate Professor

Calton N, MD
Professor

Correspondence to:
Dr Chanchal Gera
Tel: (91) 09872 995171
Fax: (91) 16126 09958
Email: cgera@
rediffmail.com

Table I. Comparison of patient's haematological and biochemical parameters in 2005 and 2009.

Parameter	Patient's values (normal values)	
	Year 2005	Year 2009
Haemoglobin (gm/dL)	12.2 (12–14)	9.1 (12–14)
Total leucocyte count/DLC	187 × 10 ⁹ /L (4–11 × 10 ⁹ /L)	53 × 10 ⁹ /L (4–11 × 10 ⁹ /L)
Platelets	N90 × 10 ⁹ /L, L08 × 10 ⁹ /L	0.9 × 10 ⁹ /L (1.5–4.5 × 10 ⁹ /L)
ESR	26 (< 20)	113 (< 20)
Urine pH	8.0 (< 5)	Not done (< 5)
ANA	Not done (negative)	1:160 positive homogenous pattern
Anti-dsDNA (IU)	Not done (≤ 35)	199.46 (≤ 35)
C3 (mg/dl)	Not done (40–120)	42 (40–120)
C4 (mg/dl)	Not done (10–40)	04 (10–40)
ft3 (U)	2.7 (6–12)	Not done (6–12)
ft4 (U)	11.4 (12–22)	Not done (12–22)
TSH (U)	10.3 (0.5–5)	18.2 (0.5–5)
Urine ph	8.0 (< 5)	
Urinary protein (mg/day)	Not done (< 30)	1.14 (< 30)
Urinary glucose	Negative	-
Urinary sodium excretion (meq/day)	275 (40–220)	-
Urinary K excretion (meq/day)	87.5 (25–120)	-
Urinary chloride excretion (meq/day)	338.7 (110–150)	-
Urinary calcium excretion (mg/day)	205 (50–150)	-
Urinary phosphate excretion (mg/day)	405 (400–1,300)	-
Urinary uric acid excretion (mg/day)	517 (250–750)	-
Urinary creatinine excretion (mg/day)	800 (0.5–1).	-
Arterial blood gas analysis	pH 7.302, pO ₂ 100, pCO ₂ 30.8, HCO ₃ 14.8, base excess -10.2, O ₂ sat 97.1	-

DLC: differential leukocyte count; ESR: erythrocyte sedimentation rate; ANA: antinuclear antibody; Anti-dsDNA: anti-double-stranded DNA antibodies; C3: complement 3; C4: complement 4; ft3: free triiodothyronine; ft4: free thyroxine; TSH: thyroid stimulating hormone

positive urinary anion gap (24 mmol/L), the diagnosis of dRTA was made. Although nephrocalcinosis was absent in our patient, type 2 RTA was excluded, as her 24-hour urinary excretion of phosphate and uric acid was normal with no glycosuria. The patient was started on potassium and bicarbonate supplements, and her biochemical parameters were corrected: blood urea 24 mg/dl, serum creatinine 1.0 mg/dl, potassium 3.9 mEq/L, chloride 95 mEq/L and arterial blood pH 7.332. She had continued on the supplements and had been asymptomatic on regular follow-ups.

In 2009, when the patient presented with polyarthritis, investigations revealed high titres of antinuclear antibody and dsDNA (antibodies to double-stranded DNA) (Table I). She had significant proteinuria. Histopathology of renal tissue revealed sclerosis in ≥ 50% of the glomeruli, while the rest exhibited mesangial widening with thickened basement membrane (Fig. 1). Segmental endocapillary proliferation was present in a few glomeruli, and the tubules also showed focal atrophy with tubulitis (Fig. 2). Lymphocytic and plasma cell infiltration was present in the interstitium, and a few vessels showed evidence of vasculitis. Direct immunofluorescence showed IgG (2+), IgM (3+), IgA

(3+), C3 (3+) and C1q (3+), which were consistent with Class V lupus nephritis. The patient was treated with prednisolone (1 mg/kg) with MMF, and her proteinuria diminished markedly. After six months of follow-up, her proteinuria diminished substantially (420 mg/day). The patient has been receiving follow-up treatment every month, and is on mycophenolate and a tapering dose of steroids.

DISCUSSION

Our patient initially presented with generalised weakness, and was diagnosed with dRTA on evaluation. Four years after the diagnosis of RTA, her final diagnosis was SLE with Class V lupus nephritis and hypothyroidism. Generalised weakness is a very subjective feeling and is an uncommon objective finding in outpatients and emergencies. There is a large differential diagnosis for muscle weakness, but only a few medical conditions, such as stroke, post-seizure paralysis, myasthenia gravis, cataplexy, multiple sclerosis, polymyositis, dermatomyositis, diphtheria, botulism, porphyria, alcohol or opiate and electrolyte disorders, develop rapid onset generalised muscle weakness. The normal resting potential of myofibres is about -85 mV at a

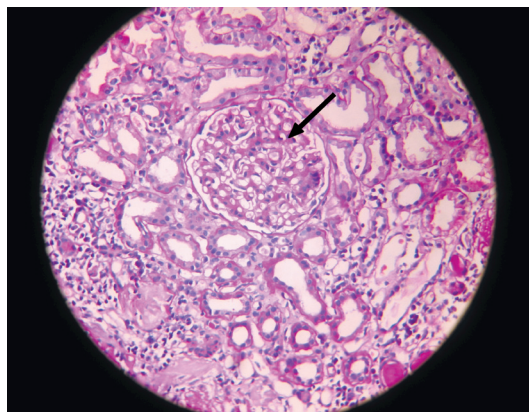


Fig. 1 Photomicrograph shows a wire loop lesion in the glomerulus (arrow) (Haematoxylin & eosin, $\times 400$).

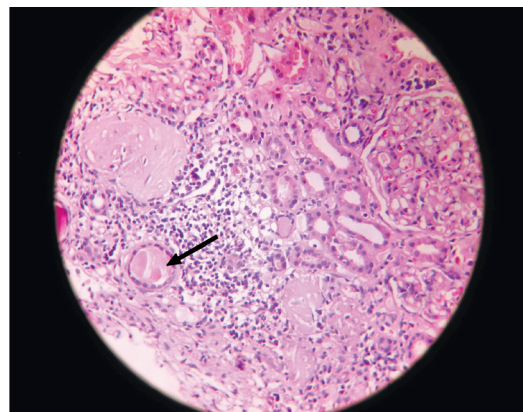


Fig. 2 Photomicrograph shows a tubular cast with tubulitis (arrow) (Haematoxylin & eosin, $\times 400$).

normal extracellular K^+ concentration ($[K^+]_o$) of 4 mM. Hyperpolarisation occurs with decreased extracellular potassium, which causes muscle inexcitability and thus, weakness.⁽⁴⁾

In renal failure, the underlying cellular mechanisms of H^+ secretion are preserved and the kidney responds normally to a systemic acid-load. However, in RTA, the kidney is not able to adequately excrete an acid (H^+) load and loses its normal acid-base balance. dRTA is a disorder of the distal renal tubules, which is characterised by hyperchloraemic metabolic acidosis, a normal serum anion gap, a urinary $pH \geq 5.5$, hypokalaemia, a positive urinary anion gap, nephrolithiasis and daily replacement needs of bicarbonate ≤ 4 mmol/kg. dRTA is the final common pathway for hypokalaemic paralysis in a variety of diseases.⁽⁵⁾ On initial presentation, our patient was thought to have polyarthralgias (i.e. Sjogren's syndrome), chronic metabolic acidosis-related osteomalacia, hypokalaemia-associated arthralgias, hypothyroidism or lupus. However, she was diagnosed with dRTA on the basis of hyperchloraemic metabolic acidosis, hypokalaemia with a positive urinary anion gap and the absence of Fanconi's syndrome. Our case is considered to be an acquired form of dRTA with hypercalciuria without nephrocalcinosis and predominant tubular involvement in SLE. Further evaluation of the patient revealed SLE with advanced lupus nephritis. Previous studies have also shown the association of SLE with various tubular defects,⁽⁶⁾ dRTA being the most common type of tubular involvement in SLE, although type 4 RTA has also been recently reported.⁽⁷⁾ Tubular dysfunction is well established in SLE and coincides with active proliferative glomerulonephritis,⁽⁸⁾ although patients usually show manifestations of lupus rather than features of RTA. The exact mechanism of tubular damage is not known. Pasternack and Linder found the deposition of immunoglobulin with complement as well as immunoglobulin-producing mononuclear cells

around the tubuli, which was highly suggestive of an immunological process affecting the tubuli, eventually leading to the destruction of some of them.⁽⁹⁾ We treated our patient with MMF, an immunosuppressant drug that is used for the induction and maintenance of remission of lupus nephritis in SLE. There is growing evidence that MMF, when combined with corticosteroid, is an effective induction treatment for severe proliferative lupus nephritis, and is associated with fewer adverse effects compared to cyclophosphamide.⁽¹⁰⁾ To conclude, tubular function should be assessed carefully in lupus patients and a workup for the presence of SLE should be done in all RTA cases.

REFERENCES

- Hattori N, Hino M, Ishihara T, et al. Hypokalemic paralysis associated with distal renal tubular acidosis. *Intern Med* 1992; 31:662-5.
- Asplin JR, Coe FL. Tubular disorders. In: Kasper DL, Braunwald E, Fauci AS, et al, eds. *Harrison's Principles of Internal Medicine*. 16th ed. New York: McGraw-Hill, 2005: 1698-9.
- Fortenberry JD, Kenney RD. Distal renal tubular acidosis as the initial manifestation of systemic lupus erythematosus in an adolescent. *J Adolesc Health* 1991; 12:148-51.
- Jurkat-Rott K, Weber MA, Fauler M, et al. K^+ -dependent paradoxical membrane depolarization and Na^+ overload, major and reversible contributors to weakness by ion channel leaks. *Proc Natl Acad Sci U S A*. 2009; 106:4036-41.
- Ahlawat SK, Sachdev A. Hypokalaemic paralysis. *Postgrad Med J* 1999; 75:193-7.
- Kozeny GA, Barr W, Bansal VK et al. Occurrence of renal tubular dysfunction in lupus nephritis. *Arch Intern Med* 1987; 147:891-5.
- Li SL, Liou LB, Fang JT, Tsai WP. Symptomatic renal tubular acidosis (RTA) in patients with systemic lupus erythematosus: an analysis of six cases with new association of type 4 RTA. *Rheumatology (Oxford)* 2005; 44:1176-80.
- ter Borg EJ, de Jong PE, Meijer SS, Kallenberg CG. Tubular dysfunction in proliferative lupus nephritis. *Am J Nephrol* 1991; 11:16-22.
- Pasternack A, Linder E. Renal tubular acidosis: an immunopathological study on four patients. *Clin Exp Immunol* 1970; 7:115-23.
- Tse KC, Tang CS, Lio WI, Lam MF, Chan TM. Quality of life comparison between corticosteroid- and-mycophenolate mofetil and corticosteroid- and-oral cyclophosphamide in the treatment of severe lupus nephritis. *Lupus* 2006; 15:371-9.