

CME Article

Clinics in diagnostic imaging (I33)

Win T, Tang P H, Lim T Y K

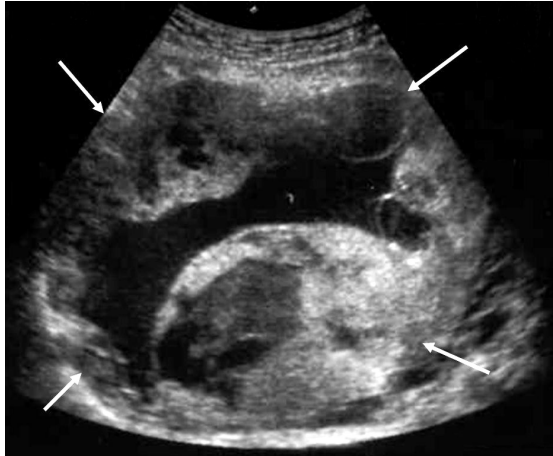


Fig. 1 Transabdominal ultrasonography image of the pelvis shows a mass (white arrows). The uterus and ovaries (not shown) were normal.

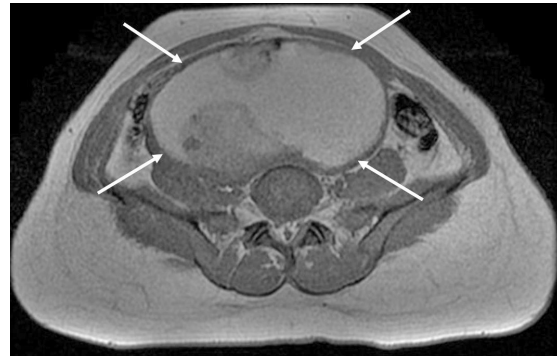


Fig. 3 Contrast-enhanced axial T1-W MR image of the pelvis, performed through the pelvic mass (white arrows), superior to the level of the anteverted uterus.

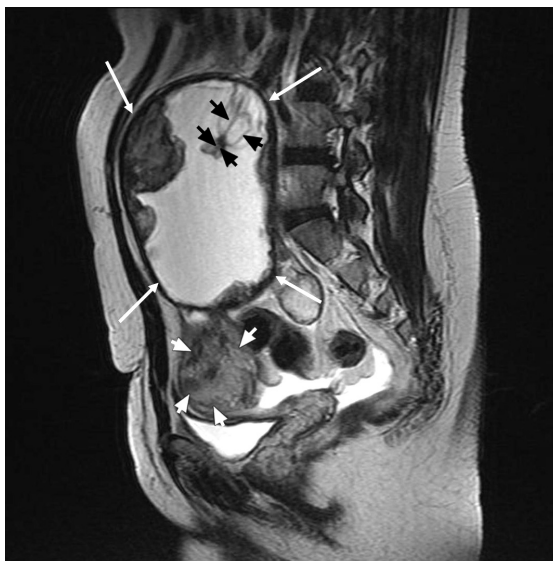

Fig. 2 Sagittal T2-W MR image of the pelvis shows a mass (white arrows) containing solid internal components (black arrowheads). Part of the normal left uterine fundus (white arrowheads) is visible above the urinary bladder.

Department of Diagnostic and Interventional Imaging, KK Women's and Children's Hospital, 100 Bukit Timah Road, Singapore 229899

Win T, MBBS, MMed, FRCR Registrar

Tang PH, MBBS, FRCR, MMed Consultant

Department of Gynaecological Oncology

Lim TYK, MBBS, MRCOG Consultant

Correspondence to: Dr Phua Hwee Tang
Tel: (65) 6394 2284
Fax: (65) 6394 2258
Email: phuahwee@yahoo.com

CLINICAL PRESENTATION

A 29-year-old Indonesian woman presented at our hospital with abdominal pain. She had delivered her second child seven months ago in Indonesia. It was a full-term pregnancy and the baby was born via Caesarean section. However, the patient developed intermittent severe lower abdominal pain and sought treatment at our hospital. She had no other past medical history of note and no history of pelvic infection. Her first child was delivered via normal vaginal delivery nine years ago. On examination, the

patient was comfortable and her vital signs were stable, with a blood pressure of 116/64 and a pulse rate of 80 per minute. She had a tender, firm pelvic-abdominal mass that extended to the umbilicus, and did not appear pale. Her beta-human chorionic gonadotropin (HCG) was not elevated.

What is the structure (white arrows) on ultrasonography (Fig. 1) and on magnetic resonance (MR) imaging (Figs. 2 & 3) of the pelvis? What is the structure demarcated by black arrowheads in Fig. 2? What is the diagnosis?

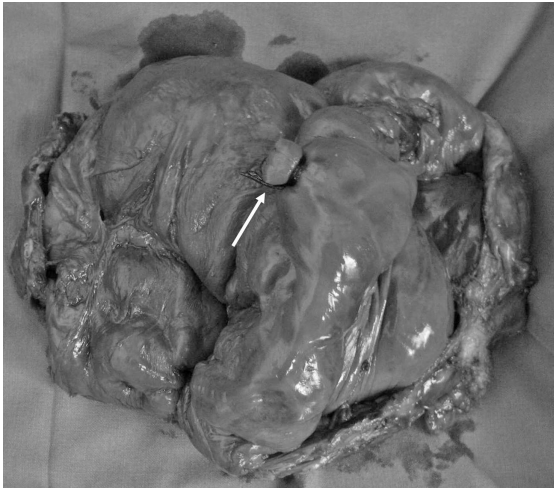

Fig. 4 Photograph shows the excised mass, cut open to reveal the umbilical stump (white arrow) that was visible on MR imaging.

IMAGING INTERPRETATION

Ultrasonography image (Fig. 1) shows a cystic mass in the pelvis (white arrows) corresponding to the palpable mass in question, with solid areas at its periphery. Sagittal T2-weighted MR image (Fig. 2) shows a large, well-defined complex cystic mass measuring 14.9 cm × 7.6 cm × 12.5 cm (white arrows) with lobulated soft tissue nodules at its periphery, occupying the lower abdomen and pelvis, just adjacent and superior to the anteverted uterus (white arrowheads). A tubular structure (black arrowheads) arising from the posterior wall of this cystic structure has a waist 1 cm from its free end, which is compatible with a ligature applied to the umbilical cord during delivery. The contents within the cyst are of high signal on both T1- (Fig. 3) and T2-weighted sequences, indicating the presence of blood products. Post contrast sequences (not shown) reveal the enhancement of the cyst wall but no enhancement of the peripheral nodules.

DIAGNOSIS

Retained placenta from an intra-abdominal pregnancy.

CLINICAL COURSE

At laparotomy, a large, blood-filled sac measuring 20 cm in diameter and containing placental cotyledons was obtained. The omentum and small bowel were wrapped around the sac, and it was adherent to the uterus and sigmoid colon. Placental cotyledons and a ligated umbilical stump could be identified within the sac (Fig. 4). Adhesiolysis was carried out, and the mass with both ovaries (inseparable from it) were removed en bloc. The patient had an uneventful postoperative course and was discharged five days after the operation.

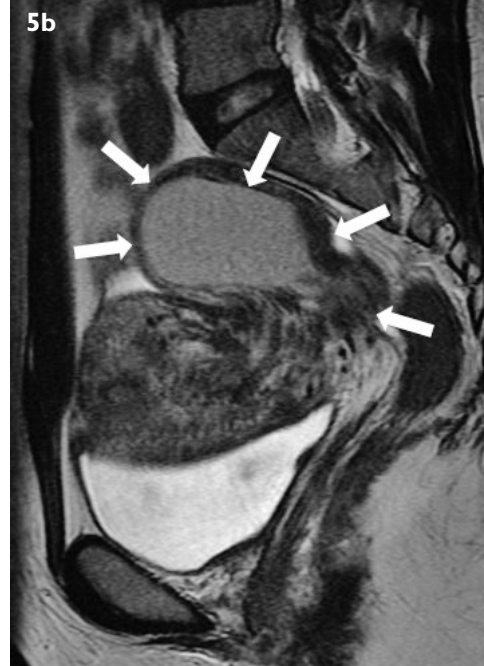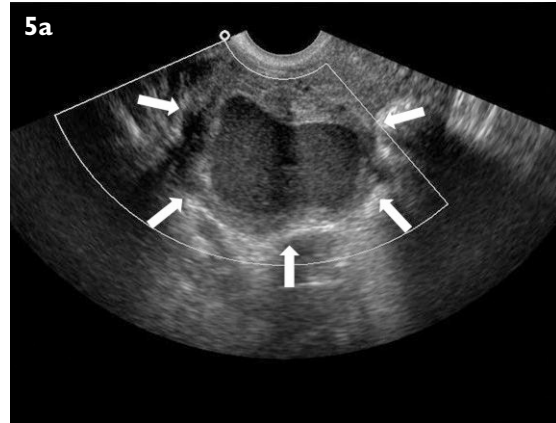


Fig. 5 (a) Transvaginal pelvic ultrasonography image of a 32-year-old woman with menorrhagia shows a 6.4 cm × 5.8 cm × 3.5 cm lobulated cystic right adnexal mass (white arrows) with a thick solid-looking wall that is avascular on colour Doppler. (b) Sagittal T2-W MR image of the pelvis shows that the mass seen on ultrasonography arises from the posterior uterus and contains a central cystic area (white arrows) compatible with a degenerated fibroid. The patient underwent myomectomy, and a leiomyoma with degenerative changes was confirmed on histology.

Final histology indicated an extrauterine pregnancy. The chorionic villi had also implanted onto the ovarian tissue and the placenta was infarcted. The patient's antenatal clinical notes were not available for review, as she had delivered in her own country. She claimed that the intra-abdominal pregnancy was only diagnosed during the Caesarean section when she was not able to deliver vaginally. The placenta could not be removed then as it was adherent to the bowel. No antenatal imaging was available.

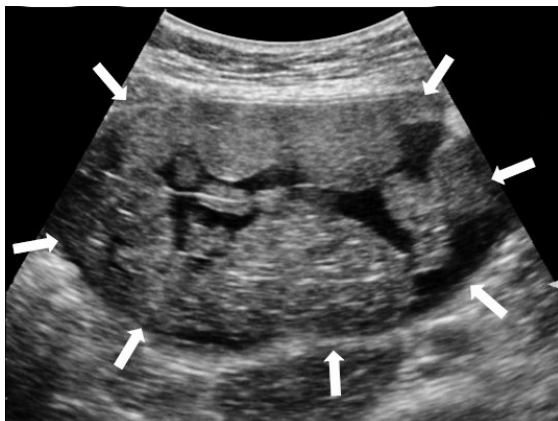

Fig. 6 Transabdominal pelvic ultrasonography image of a 50-year-old woman with right iliac fossa pain shows a 12.6 cm × 11.7 cm × 7.8 cm well-defined cystic mass in the right lower abdomen, containing multiple round, solid-looking hypoechoic nodules within it (white arrows). The patient subsequently underwent total hysterectomy and bilateral salpingo-oophorectomy, and the mass was found to be a right ovarian cystic teratoma.

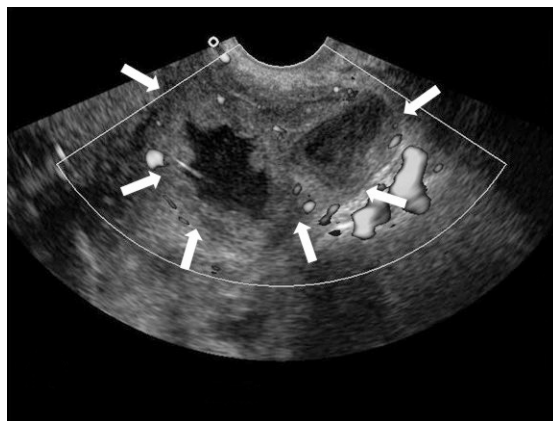


Fig. 8 Transvaginal pelvic ultrasonography image of a febrile 49-year-old woman with raised total white cell count shows a 6.8 cm × 4.4 cm × 4.2 cm lobulated complex cystic structure with a thick wall (white arrows) in the right adnexa, compatible with an abscess. Pus had been aspirated from it under ultrasonography guidance. The patient later underwent elective total hysterectomy and bilateral oophorectomy for uterine fibroids, and histology revealed chronic right salpingitis.

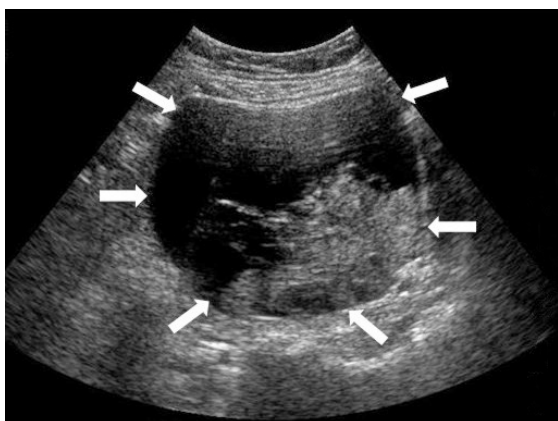


Fig. 7 Transabdominal pelvic ultrasonography image of a 61-year-old woman with cervical carcinoma shows a complex solid-cystic 9.4 cm × 8.1 cm left adnexal mass (white arrows). Blood flow was visible within the solid hypoechoic component on colour Doppler. The patient underwent left salpingo-oophorectomy and was found to have concurrent endometrioid cystadenocarcinoma of the left ovary. Her cervical carcinoma was treated with radiotherapy and chemotherapy.

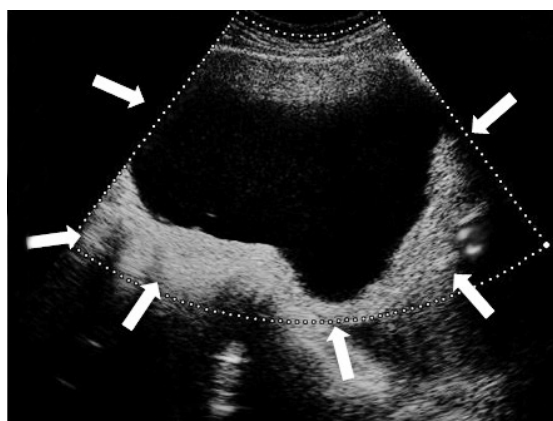


Fig. 9 Transabdominal pelvic ultrasonography image of a 26-year-old woman with lower abdominal pain shows a 15.4 cm × 12.9 cm × 12.0 cm solid-cystic mass (white arrows) containing thin septations. No flow was seen within it on colour Doppler, and histology revealed an infarcted left ovarian cyst lined internally by clots.

DISCUSSION

Intra-abdominal pregnancy is a rare obstetric condition, with an incidence of 1 in 10,000 births.⁽¹⁾ The placenta is often attached to multiple sites, including the bowel, omentum, uterine cul-de-sac and pelvic sidewall. The major cause of maternal mortality in these cases is intraperitoneal bleeding after placental removal. The risk factors include previous pelvic infection, congenital maternal anomalies, endometriosis and previous ectopic pregnancy. An ectopic pregnancy is a gestation outside the confines of the uterine body and includes cervical, cornual, tubal, ovarian and abdominal pregnancies⁽²⁾

as well as gestations in unusual sites such as caesarean scars,⁽³⁾ whereas an intra-abdominal pregnancy refers to an intraperitoneal ectopic gestation that is separate from the uterus and tubes. Ovarian ectopic may be difficult to distinguish from an intra-abdominal pregnancy if the gestation is large and implanted on multiple sites, including the ovary.

The signs and symptoms of advanced abdominal pregnancies are nonspecific. The symptoms are related to the site of implantation of the placenta, whether uterus, bowel or bladder. The most frequently reported symptom is abdominal pain, followed by nausea and vomiting,

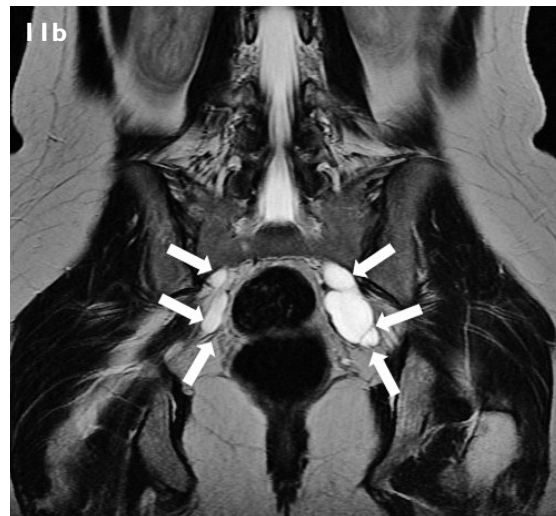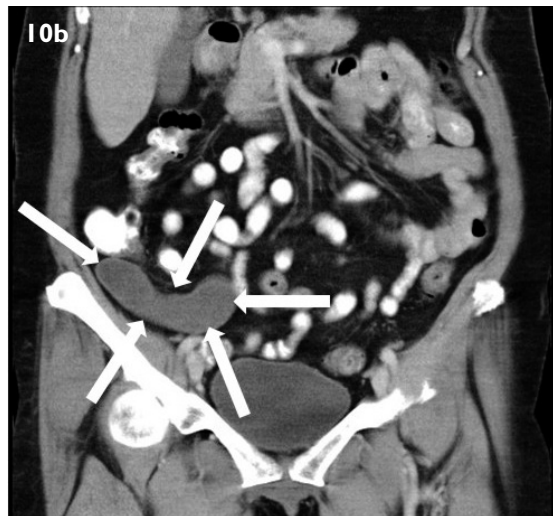
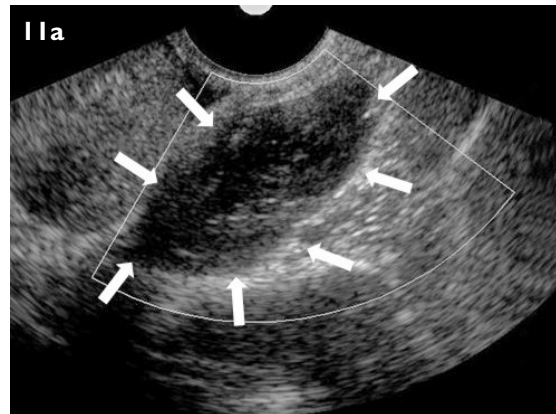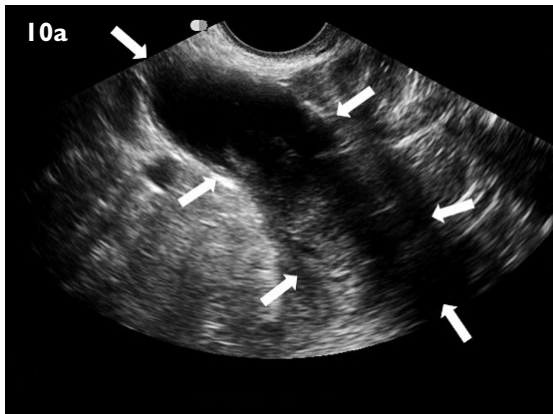


Fig. 10 (a) Transvaginal pelvic ultrasonography image of a 56-year-old woman shows a 6.2 cm × 3.2 cm × 2.6 cm tubular cystic structure in the right iliac fossa (white arrows), with a solid component seen within one end. It was avascular on colour Doppler. (b) CT performed later the same day showed this (white arrows) to be connected to the base of the caecum. Mucinous cystadenoma of the vermiform appendix was found on histology.

Fig. 11 (a) Transvaginal pelvic ultrasonography image of a 28-year-old woman shows a 5.2 cm × 2.2 cm × 1.7 cm elongated tubular structure (white arrows) in the left adnexa, with another smaller but similar structure in the right adnexa (not shown). (b) Coronal T2-W MR image of the pelvis shows perineural cysts (white arrows).

painful foetal movements and urinary frequency. There may also be abdominal tenderness, an abnormal foetal lie or a displaced uterine cervix.

Diagnosis is difficult and sometimes may only be made at delivery. Ultrasonography is the most important tool used for the diagnosis of an ectopic pregnancy. The sonographic features of an abdominal pregnancy include a foetus, placenta or gestational sac outside the uterus, the lack of myometrium between the foetus and the urinary bladder or anterior abdominal wall, oligohydramnios as well as foetal malpresentation such as transverse lie.⁽⁴⁾ MR imaging is useful for problematic cases. The location of an ectopic pregnancy and its relationship to the surrounding structures can be clearly shown on MR imaging even when it is obscured by bowel on ultrasonography.

Due to the rarity of this condition, its management is still controversial, particularly for the placenta. Foetal

viability, the gestational age of the foetus at presentation and availability of adequate neonatal facilities are factors that have to be considered. If the foetus is not viable at presentation, surgical intervention is generally indicated, as there is risk of infection and disseminated intravascular coagulation.⁽⁵⁾

In the past, if the foetus was alive, some would advocate laparotomy regardless of the gestational age or foetal condition because of the unpredictability of placental separation and massive haemorrhage. More recently, some authors have suggested early operative intervention if the foetus is alive and less than 24 weeks old, to reduce the risk of massive haemorrhage. For the foetus that is older than 24 weeks, some have recommended that the pregnancy be allowed to progress with close monitoring of the patient in a hospital with good neonatal support. In allowing the pregnancy to continue, the benefit of foetal development

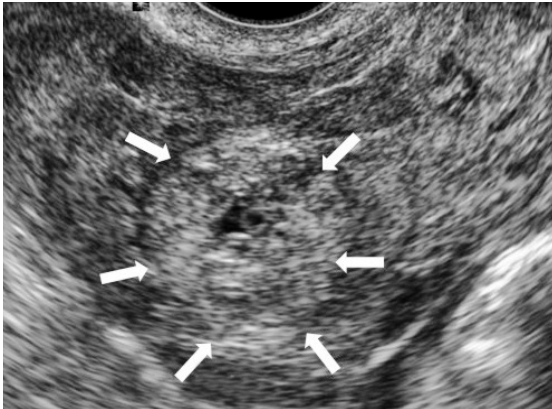


Fig. 12 Transvaginal pelvic ultrasonography image of a 25-year-old pregnant woman who presented with acute retention of urine shows a 2.7 cm × 2.7 cm × 2.5 cm echogenic mass in the right adnexa containing a 0.2 cm yolk sac (white arrows), consistent with an ectopic pregnancy. Hypochoic material surrounding it with echogenic free pelvic fluid suggested a ruptured ectopic pregnancy. No intrauterine gestation was seen. A ruptured right ovarian ectopic with haemoperitoneum was seen at surgery and a right ovarian ectopic pregnancy was confirmed on histology.

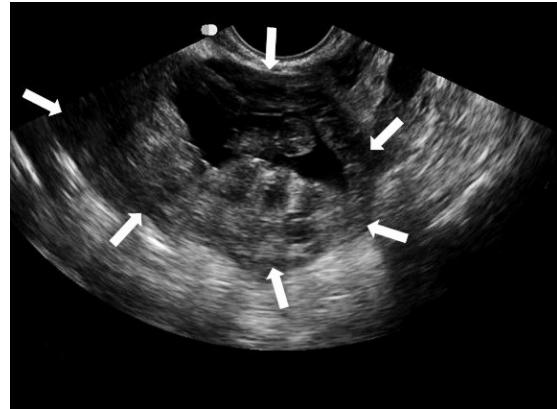


Fig. 13 Transvaginal pelvic ultrasonography image of a 28-year-old pregnant woman with left abdominal pain shows a nine-week old fetus surrounded by placenta (white arrows), the entire mass measuring 8.0 cm × 7.3 cm × 4.1 cm, situated between the urinary bladder and rectum. No heartbeat was visualised in the foetus, although flow was demonstrated within the placenta on colour Doppler. A 15-cm ruptured left tubal ectopic pregnancy with haemoperitoneum was found at surgery and histology confirmed a left tubal ectopic.

has to be balanced against the maternal risk of massive haemorrhage.

The main cause of maternal mortality is due to massive intraperitoneal haemorrhage from separation of the abnormally situated placenta from its attachments. The management of the placenta following the delivery of the foetus is still a matter of debate. Removal of the whole placenta is advocated if the blood supply can be identified and ligation of these vessels can be performed. If complete removal is not possible, the placenta should be left behind to avoid catastrophic haemorrhage and shock.⁽⁶⁾ Partial removal of the placenta is of little benefit and is very dangerous.⁽⁷⁾ Till today, there is still no clear-cut consensus on the management of retained placentas from intra-abdominal pregnancy.⁽⁸⁾ In fact, more recent articles have suggested selective embolisation of the placental vessels as an alternative to surgery, or to minimise blood loss from surgery.⁽⁹⁾

Methotrexate administration has been used for treatment of the retained placenta after removal of the foetus. However, it is not routinely practised, as rapid degradation of the intra-abdominal placental tissue can result in a large amount of necrotic tissue that favours bacterial growth and sepsis.⁽⁵⁾ If the placenta is not removed, placental involution can be followed up with ultrasonography, which can document the reduction of placental volume and corresponding reduced vascularity. Serial beta-HCG values that display a decreasing trend is also helpful in monitoring placental activity and involution.⁽¹⁰⁾ Complications of a placenta left *in situ* may include ileus, peritonitis and abscess formation, all of

which may contribute to prolonged hospitalisation.

Pelvic masses in a female patient most commonly arise from the female genitalia. Other less common causes include masses from bowel (appendiceal mucocoele, mesenteric and enteric duplication cysts), the urinary system (ureterocoele), nerves (neurofibromas, perineural cysts) or vessels (aneurysms). Uterine fibroids are common pelvic masses and can have cystic components when they undergo degeneration (Fig. 5). They are readily recognised in view of their intrauterine location and well-defined borders. Adenomyosis can also result in an asymmetrically enlarged uterus containing myometrial cysts, and the diagnosis is likewise made on the intrauterine location. Another common cause of a cystic-solid mass would be an ovarian cyst. These can be functional cysts such as a haemorrhagic corpus luteum or ovarian tumours. Endometriosis is a common cause of ovarian cysts containing avascular solid components (clots). Benign teratomas (Fig. 6) and malignant ovarian tumours (Fig. 7) can also present as cystic-solid masses. Pelvic inflammatory disease can give rise to complex cystic-solid tubo-ovarian abscesses (Fig. 8) and appendicitis. Diverticulitis can be complicated by abscesses, but the patient would be expected to be ill in such cases. A torsed ovary can also appear as a complex mass on ultrasonography, and the clinical symptom of pain (particularly in a young patient) and the lack of flow within the mass on colour Doppler may help in the diagnosis (Fig. 9).

Solid-cystic pelvic masses not originating from the female genitalia should be suspected in the presence of a normal uterus and ovaries. Masses which are in close

contact or inseparable from the bowel may arise from the bowel, although this may be difficult to visualise on ultrasonography and better appreciated on computed tomography (Fig. 10). If the mass has a tubular configuration and is closely related to the pelvic side or can be followed to the presacral region, neuroenteric cysts or a vascular aetiology should be considered (Fig. 11).

A cystic-solid pelvic mass in a post-partum patient after Caesarean section includes degenerated fibroid, retained products of conception or an abscess. In our patient, the diagnosis was readily made in view of the history of a retained placenta and with the ligated umbilical cord visible on MR imaging. As the patient had delivered outside the country, the antenatal and delivery notes were not available for review. It is assumed that if an antenatal first trimester ultrasonography had been performed, it would have demonstrated a gestational sac (Fig. 12), or even a foetus and placenta outside the uterus (Fig. 13). According to the patient, the diagnosis of an intra-abdominal pregnancy was not made antenatally but only at the point of delivery. She was treated conservatively after delivery of the baby and the placenta was left *in situ* for about seven months. However, she developed severe intermittent abdominal pain and elected to have the retained placenta removed surgically. The patient has since made an uneventful recovery. Her normal beta-HCG value would be compatible with the infarcted placental tissue seen on histology.

ABSTRACT

A 29-year-old Indonesian woman presented with abdominal pain seven months after an intra-abdominal pregnancy. Ultrasonography revealed a cystic mass in the pelvis and magnetic resonance imaging showed an umbilical stump within it, indicating a retained placenta. This was removed

surgically, and on histology, an infarcted placenta was confirmed.

Keywords: intra-abdominal pregnancy, magnetic resonance imaging, retained placenta

Singapore Med J 2011;52(1):53-59

ACKNOWLEDGEMENT

The images for Fig. 11 are reproduced with the permission of Dr Ong Chiou Li, Senior Consultant, Department of Diagnostic Imaging, KK Women's and Children's Hospital, Singapore.

REFERENCES

1. Atrash HK, Friede A, Houe CJ. Abdominal pregnancy in the United States: frequency and maternal mortality. *Obstet Gynecol* 1987; 69(3 Pt 1):333-7.
2. Dialani V, Levine D. Ectopic pregnancy: a review. *Ultrasound Q* 2004; 20:105-17.
3. Doubilet PM, Benson CB, Frates MC, Ginsburg E. Sonographically guided minimally invasive treatment of unusual ectopic pregnancies. *J Ultrasound Med* 2004; 23:359-70.
4. Allibone GW, Fagan CJ, Porter SC. The sonographic features of intra-abdominal pregnancy. *J Clin Ultrasound* 1981; 9:383-7.
5. Kun KY, Wong PY, Ho MW, Tai CM, Ng TK. Abdominal pregnancy presenting as a missed abortion at 16 weeks' gestation. *Hong Kong Med J* 2000; 6:425-7.
6. Varma R, Mascarenhas L, James D. Successful outcome of advanced abdominal pregnancy with exclusive omental insertion. *Ultrasound Obstet Gynaecol* 2003; 21:192-4.
7. Bajo JM, Garcia-Frutos A, Huertas MA. Sonographic follow-up of a placenta left in situ after delivery of the fetus in an abdominal pregnancy. *Ultrasound Obstet Gynecol* 1996; 7:285-8.
8. Ramachandran K, Kirk P. Massive hemorrhage in a previously undiagnosed abdominal pregnancy presenting for elective Cesarean delivery. *Can J Anaesth* 2004; 51:57-61.
9. Veerareddy S, Sriemevan A, Cockburn JF, Overton TG. Non-surgical management of a mid-trimester abdominal pregnancy. *BJOG* 2004; 111:281-3.
10. Valenzano M, Nicoletti L, Odicino F, et al. Five-Year follow-up of placental involution after abdominal pregnancy. *J Clin Ultrasound* 2003; 31:39-43.

SINGAPORE MEDICAL COUNCIL CATEGORY 3B CME PROGRAMME
Multiple Choice Questions (Code SMJ 201101B)

	True	False
Question 1. Regarding intra-abdominal pregnancy:		
(a) It is a form of ectopic pregnancy.	<input type="checkbox"/>	<input type="checkbox"/>
(b) It can implant onto omentum.	<input type="checkbox"/>	<input type="checkbox"/>
(c) It should be managed with normal vaginal delivery.	<input type="checkbox"/>	<input type="checkbox"/>
(d) It poses a high risk to the mother.	<input type="checkbox"/>	<input type="checkbox"/>
Question 2. Risk factors for intra-abdominal pregnancy include:		
(a) Congenital uterine anomalies.	<input type="checkbox"/>	<input type="checkbox"/>
(b) Previous pelvic inflammatory disease.	<input type="checkbox"/>	<input type="checkbox"/>
(c) Previous ectopic pregnancy.	<input type="checkbox"/>	<input type="checkbox"/>
(d) Endometriosis.	<input type="checkbox"/>	<input type="checkbox"/>
Question 3. Ultrasonography findings of an intra-abdominal pregnancy include:		
(a) Gestational sac outside the uterus.	<input type="checkbox"/>	<input type="checkbox"/>
(b) Placenta within the endometrial cavity.	<input type="checkbox"/>	<input type="checkbox"/>
(c) Lack of myometrium between foetus and urinary bladder.	<input type="checkbox"/>	<input type="checkbox"/>
(d) Transverse lie of foetus.	<input type="checkbox"/>	<input type="checkbox"/>
Question 4. Recommended management of a placenta from an intra-abdominal pregnancy are:		
(a) Complete removal during delivery.	<input type="checkbox"/>	<input type="checkbox"/>
(b) Partial removal during delivery.	<input type="checkbox"/>	<input type="checkbox"/>
(c) Methotrexate administration.	<input type="checkbox"/>	<input type="checkbox"/>
(d) Conservative management.	<input type="checkbox"/>	<input type="checkbox"/>
Question 5. The differential diagnoses of a solid-cystic pelvic mass in a post-partum woman are:		
(a) Bronchogenic cyst.	<input type="checkbox"/>	<input type="checkbox"/>
(b) Tubo-ovarian abscess.	<input type="checkbox"/>	<input type="checkbox"/>
(c) Degenerated fibroid.	<input type="checkbox"/>	<input type="checkbox"/>
(d) Retained products of conception.	<input type="checkbox"/>	<input type="checkbox"/>

Doctor's particulars:

Name in full: _____

MCR number: _____ Specialty: _____

Email address: _____

SUBMISSION INSTRUCTIONS:

(1) Log on at the SMJ website: <http://www.sma.org.sg/cme/smj> and select the appropriate set of questions. (2) Select your answers and provide your name, email address and MCR number. Click on "Submit answers" to submit.

RESULTS:

(1) Answers will be published in the SMJ March 2011 issue. (2) The MCR numbers of successful candidates will be posted online at www.sma.org.sg/cme/smj by 7 March 2011. (3) All online submissions will receive an automatic email acknowledgment. (4) Passing mark is 60%. No mark will be deducted for incorrect answers. (5) The SMJ editorial office will submit the list of successful candidates to the Singapore Medical Council.

Deadline for submission: (January 2011 SMJ 3B CME programme): 12 noon, 28 February 2011.