

# Percutaneous ablative treatment of metastatic bone tumours: visual analogue scale scores in a short-term series

Masala S, Guglielmi G, Petrella M C, Mastrangeli R, Meschini A, Anselmetti G C, Bartolucci D A, Mammucari M, Manenti G, Simonetti G

## ABSTRACT

**Introduction:** The aim of this study was to examine the role of palliative percutaneous secondary lesions bone treatment by comparing the visual analogue scale (VAS) scores of cryoablation plus vertebroplasty versus radiofrequency (RF) plus vertebroplasty so as to determine their feasibility, reliability and efficacy in a short-term series.

**Methods:** Combined RF thermal ablation plus osteoplasty or cryoablation plus osteoplasty was performed in osteolytic secondary bone localisations in 30 consecutive patients who were suffering from pain refractory to conservative therapies. We evaluated pain with the VAS during the preoperative period and at four hours, 24 hours, one week, one month, three months and six months post procedure.

**Results:** There were no statistically significant differences in the VAS score between patients treated with cryoablation plus osteoplasty and those treated with RF ablation plus osteoplasty at one week (p-value is 0.34), one month (p-value is 1), three months (p-value is 0.68) and six months (p-value is 0.65) post procedure. Patients treated with cryoablation plus vertebroplasty have less pain at four hours (p-value less than 0.001) and 24 hours (p-value less than 0.001) than patients treated with RF ablation plus vertebroplasty.

**Conclusion:** Both RF ablation and cryoablation are optimal techniques in the treatment of painful bone metastatic cancer. Cryoablation achieves less treatment-related pain during the early period of follow-up and better volume control by real-time depiction of ablation margins.

**Keywords:** bone metastases, cryoablation, percutaneous therapies, radiofrequency, vertebroplasty

Singapore Med J 2011; 52(3): 182-189

## INTRODUCTION

Metastatic cancer is the most common malignant disease of the bone. Skeletal metastases are the primary findings in breast, lung and prostate malignancies, followed by melanoma, renal, gastrointestinal and thyroid cancers, lymphoma and myeloma.<sup>(1,2)</sup> The most common site of localisation is the spinal column.<sup>(3)</sup> Vertebral metastases induce pain, impair the quality of life and results in complications of vertebral localisation, such as pathological fractures, spine instability and neurological damage.<sup>(4,5)</sup>

Patients with metastatic lesions are often in advanced stages of the disease at the time of diagnosis; the treatment purpose is, therefore, to palliate pain and prevent complications by reducing the length of hospital stay and by improving performance status. Standard treatments include local (radiation and surgery) and systemic therapies (chemotherapy, hormonal therapy, bisphosphonates and analgesics).<sup>(6)</sup> Radiation therapy (RT) is a therapeutic strategy, but up to 20%–30% of patients do not respond to treatment, with no further treatment eventuality.<sup>(7-11)</sup>

Patients with recurrent pain at a previously irradiated site cannot be exposed to subsequent radiation dose due to the dose limits of healthy organs. Surgical resection is almost never possible in patients with advanced disease and poor functional status. Systemic therapies may not be beneficial for reduced therapeutic response or toxicity. Many patients develop intolerable side effects in order to achieve adequate pain control with analgesics. Long-term results of common pain treatments are not satisfactory. Due to the short life expectancy and poor quality of life in these patients, a minimally invasive approach is required. In the last few years, some new therapeutic strategies to offer a curative option have been considered. These techniques are based on image guidance to direct devices into metastatic tissue in order to ablate lesions without causing damage to healthy tissue, along with other procedures like alcohol,<sup>(12,13)</sup> laser,<sup>(14,15)</sup> methylmethacrylate<sup>(16-21)</sup> cryoablation<sup>(22-24)</sup> and radiofrequency (RF).<sup>(25-29)</sup>

The aim of our study was to examine the symptomatic

Department of Diagnostic Imaging and Interventional Radiology, Molecular Imaging and Radiotherapy, Policlinico Universitario Tor Vergata, Roma 00133, Italy

Masala S, MD

Petrella MC, MD

Mastrangeli R, MD

Meschini A, MD

Bartolucci DA, MD

Mammucari M, MD

Manenti G, MD

Simonetti G, MD

Department of Radiology, University of Foggia, Vial Luigi Pinto 1, Foggia 71100, Italy

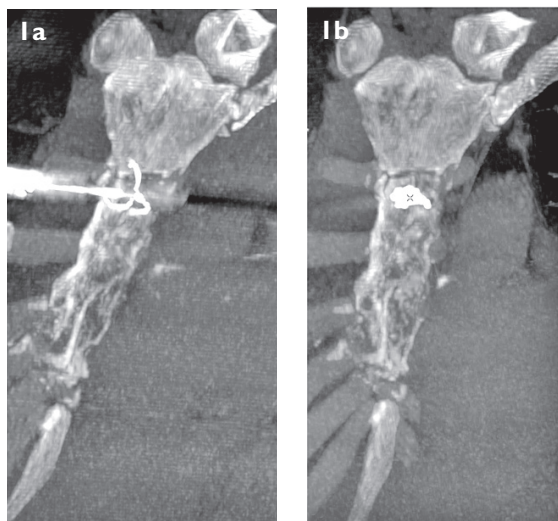
Department of Radiology, Scientific Institute Hospital "Casa Sollievo della Sofferenza", Viale Cappuccini 1, San Giovanni Rotondo 71013, Italy

Guglielmi G, MD

Department of Diagnostic Imaging and Interventional Radiology, Candiolo 10060, Torino, Italy

Anselmetti GC, MD

**Correspondence to:** Prof Giuseppe Guglielmi  
Tel: (39) 0881 733866  
Fax: (39) 0881 733866  
Email: g.guglielmi@unifg.it



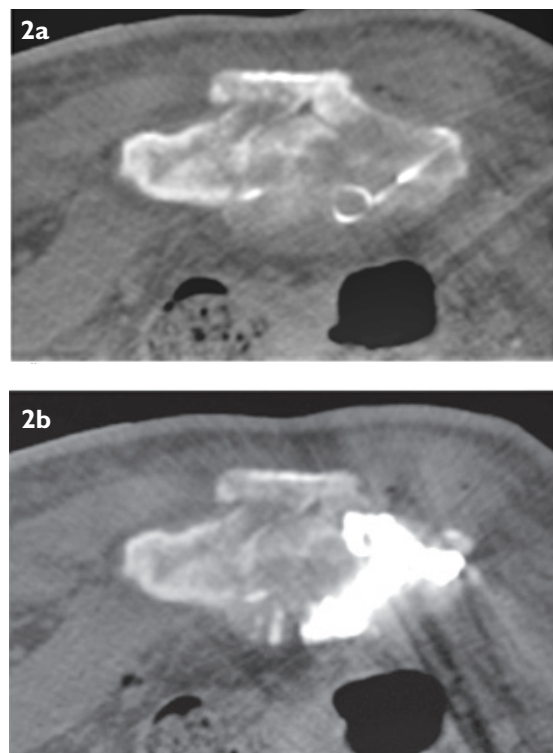
**Fig. 1** (a) MIP reconstruction of the sternum shows the radiofrequency needle positioned in the centre of the lesion in the sternal body. (b) MIP reconstruction after radiofrequency thermal ablation procedure shows no complications.

role of percutaneous metastatic bone lesion treatment by comparing the Visual Analogue Scale (VAS) scores of combined cryoablation plus vertebroplasty and RF plus vertebroplasty procedures in terms of their efficacy, feasibility and repeatability in a short-term series.

## METHODS

We retrospectively analysed 30 consecutive patients suffering from metastatic bone disease refractory to conservative pain treatments. These patients were referred to our institution from December 2006 to December 2007. Institutional review board approval and informed consent were obtained for the study. The inclusion criterion was one or more bone metastatic lesions that were localised in one or more osseous segments, with pain originating from these metastatic lesions. The exclusion criteria for the combined procedures included good response to medical treatment, untreatable coagulopathy, systemic or local infections (osteomyelitis, spondylodiscitis), the presence of radicular symptoms or neurologic deficits, spinal stenosis and noncorrelating pain.

All lesions were considered resectable from an anatomic point of view, but surgical treatment was advised due to high surgical risk, as assessed by the oncologist surgeon and anaesthesiology board, or when patients refused surgery. All patients were managed in cooperation with the hospital medical and oncology staff. Combined RF thermal ablation followed by osteoplasty or cryoablation followed by osteoplasty was applied in metastatic osteolytic lesions. Plain radiography, computed tomography (CT) and/or magnetic resonance (MR) imaging and positron emission tomography (PET)

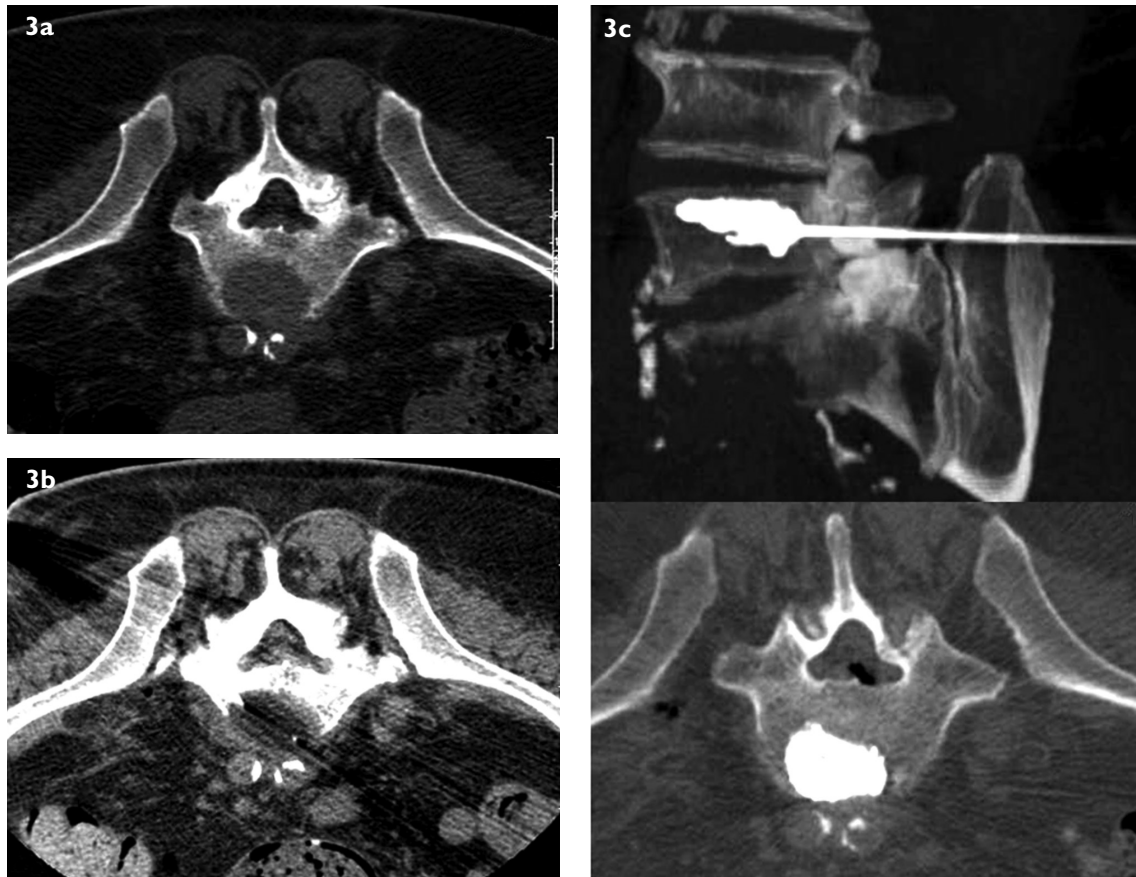


**Fig. 2** Axial CT image (a) at the level of the sacrum shows the tip of the radiofrequency electrode positioned at the centre of the osteolytic lesion; (b) at the same level after the injection of polymethylmethacrylate shows no complications.

fusion imaging were performed as part of pre-procedural planning. Tumour diagnosis was pathologically established in all cases by CT-guided cytoaspiration, and biopsies were performed with a co-axial needle (Ecoject, HS Hospital Service, Cavezzo, Italy).

The VAS score was obtained from patients through a questionnaire (via direct interview) that rated pain from a scale of 0–10 to indicate the intensity of pain<sup>(30–32)</sup> before the procedure, during the procedure, at four hours, 24 hours and one month post procedure. Another VAS score was obtained through a telephonic interview at one week, three months and six months post procedure. This data was recorded together with each patient's clinical information.

All percutaneous procedures were performed in a CT room. A CT image with contrast media was obtained to assess lesion vascularisation in order to plan probe positioning. 5–15 cc of 1% lidocaine local anaesthesia was administered along the probe path to the periosteum, and a skin incision was made to access the lesion sites. Antibiotic coverage was started three hours prior to the procedure and continued until the third postoperative day. During the procedure, the patients were monitored via a non-invasive approach, and post-procedural pain was treated with non-steroidal anti-inflammatory drugs (NSAIDs) or opioids, as required.



**Fig. 3** Axial CT image (a) at the level of L5 shows an osteolytic lesion on the anterior part of the vertebral body; (b) using a transiliac approach performed to reach the neoplastic lesion shows the ipodense area at the centre of the lesion, which iceball allows a direct visualisation of the ablation margins. (c) 3D CT reconstruction (upper) and axial CT (lower) images of the postprocedural control show the correct placement of polymethylmethacrylate into the lesion ablated.

The RF system circuitry used was composed of the following: a 100 W to 480 kHz computerised generator (Invatec, Concesio, Brescia, Italy), activating power output, impedance value and procedure time; an expandable 2.5-mm thick electrode; two to four 8 cm × 16.5 cm grounding pads around the entry site that were connected to the RF generator. The patient was prepped in the prone, lateral or supine decubitus position in order to reduce the distance the electrode would have to travel to reach the tumour. Insertion was carried out under CT guidance. After confining the correct entry site, an incision was made on the patient's skin. A coaxial cannula was percutaneously shifted to the tumour. An 11- to 13-Gauge bone biopsy needle was then coaxially introduced and retracted into the secondary bone lesion. After CT visualisation of the operating cannula position, a 19-Gauge electrode needle (MIRAS-RC, Invatec, Concesio, Brescia, Brescia, Italy) and a thermocouple were introduced coaxially through the inserted cannula into the central core of the osteolytic lesion.

MIRAS-RC is an electrode with an extractable antenna coil, which is deployed perpendicular to the

shaft. After unsheathing the spiral electrode tine, which opened to a maximum diameter of 9 mm and a length of 10 mm into the soft metastasis, the needle probe was connected to the RF generator. The tip was positioned in the centre of the tumour so that the deployed array would reach the farthest margin of the tumour. Each placement was confirmed by a 3-dimensional CT reconstruction.

The RF generator was then started, and power was gradually increased until the impedance reached values that blocked further energy delivery (200 Ohms). Depending on the shape and dimension of the tumour, one or more thermal lesions were created along the electrode insertion path using a pull-back technique. The amount of power delivered, duration of procedure and impedance values were recorded. CT was performed after each RF thermal ablation procedure so as to identify treatment-related complications. In all cases, CT imaging targeted gas microbubble formation into the treated area, representing tumour necrosis from water evaporation (Figs. 1 & 2).

A double approach was performed at each tumour site, depending on the dimensions of the lesion. The

**Table I. Case summary of the patients (n = 30).**

Patient no.	Interventional treatment	Age (yrs)	Gender	Primary tumour	No. of lesion	Localisation/size (mm)	Post-procedural analgesic therapy <sup>†</sup>
1	RF + OP	84	F	Breast	1	D10/22	None
2	CRYO + OP	68	M	Mieloma	1	L3/18	None
3	RF + OP	66	F	Breast	1	Sterni/20	Nsaids
4	RF + OP	79	F	Breast	1	Ilium/33	None
5	CRYO + OP	76	F	Breast	3	Femur/37; tibia/42; ilium/16	NSAIDs
6	CRYO + OP	75	F	Breast	1	Ilium/40	None
7	RF + OP	80	F	Lung	1	L3/15	None
8	CRYO + OP	88	M	Lung	1	D7/32	None
9	CRYO + OP	84	M	Liver	1	Femur/28	None
10	RF + OP	82	M	Prostate	1	L5/20	None
11	RF + OP	76	M	Prostate	2	L4/23; L5/25	None
12	CRYO + OP	82	M	Prostate	1	D10/17	None
13	CRYO + OP	82	M	Prostate	1	Sacrum/70	None
14	RF + OP	74	F	Colon	1	Sacrum/35	None
15*	RF + OP	76	F	Breast	1	D9/20	None
16	RF + OP	77	F	Breast	1	L3/21	None
17	RF + OP	65	M	Prostate	2	L5/18; sacrum/22	None
18	CRYO + OP	71	M	Prostate	1	Ilium/28	None
19	CRYO + OP	69	F	Breast	2	D10/17; D12/23	NSAIDs
20	CRYO + OP	71	F	Colon	1	L4/22	None
21	RF + OP	61	M	Colon	1	L5/18	None
22	CRYO + OP	74	M	Lung	1	Femur/30	None
23	RF + OP	82	F	Lung	1	Tibia/25	None
24	RF + OP	75	F	Breast	1	D12/20	None
25	CRYO + OP	63	M	Myeloma	3	D12/19; L2/21; L4/20	None
26	CRYO + OP	76	M	Gastric	1	Sacrum/23	None
27	RF + OP	84	F	Breast	1	Sacrum/20	NSAIDs
28	CRYO + OP	75	F	Breast	1	D10/19	Narcotics
29	CRYO + OP	89	F	Breast	1	D11/17	None
30	RF + OP	89	F	Lung	1	L5/19	None

\* Patient 15 had radiculopathy, while the rest of the patients had no complications.

<sup>†</sup> All patients were administered with narcotics as part of the pre-procedure analgesic therapy.

RF + OP: radiofrequency ablation plus osteoplasty; CRYO + OP: cryoablation plus osteoplasty; NSAIDs: non-steroidal anti-inflammatory drugs

13-Gauge biopsy needle positioning was followed by coaxial cryoprobe insertion. The biopsy needles were then slightly retracted to obtain a better tip exposition of the freezing cryoprobes. We used two types of 17-Gauge devices: IceRod and IceSeed (Galil Medical, Yokneam, Israel). IceRod, a double-chambered gas expansion probe, allows wider iceball formation (16 mm × 41 mm ellipsoid at -40°C) compared to IceSeed, which has a single gas expansion chamber on the exposed tip (10.5 mm × 19 mm ellipsoid formation at -40°C).

The number and type of cryoprobes were preliminarily selected according to lesion characteristics (volume and shape) in order to provide adequate lesion coverage. In lesions ≤ 3 cm, only one cryoprobe was used, while 2–5 devices were employed for bigger masses. Two freezing-thawing cycles were usually performed, both cycles with a ten-minute freezing time and a six-minute active thawing time. Lesions > 7 cm in diameter were treated with three freezing-thawing cycles, using passive thawing in order to achieve bigger iceballs.

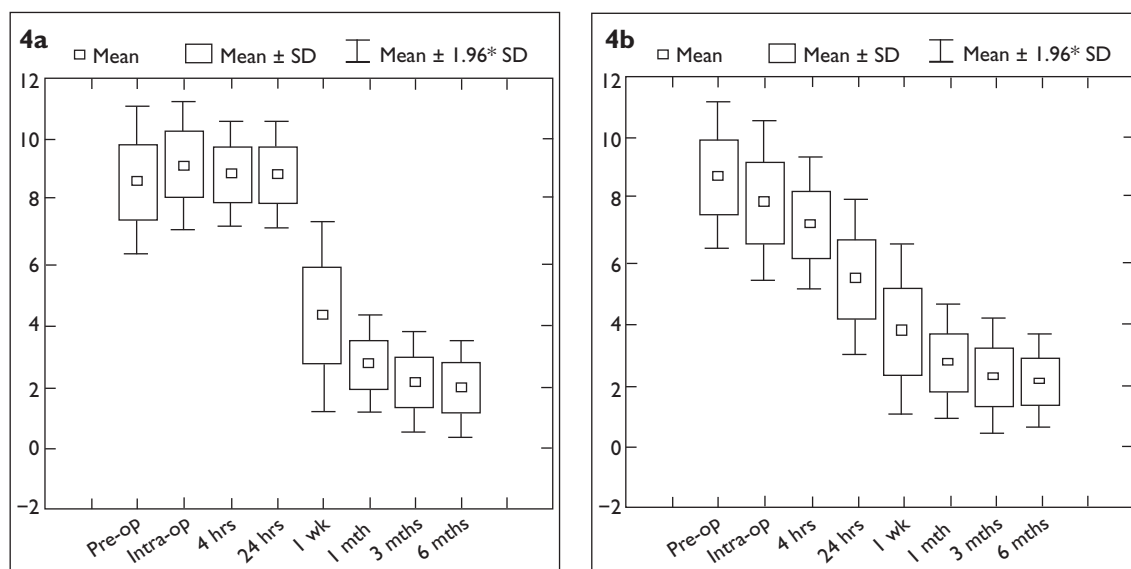
During each cryoablation cycle, iceball volume CT monitoring inside the lesion was obtained as hypodense areas arising from the probe tips and enveloping the neoplastic tissue (Fig 3). Freezing effect spreads along the needle and can produce its effect on healthy superficial tissues. Hot, wet gauze pads were positioned near the cutaneous needle insertion site to avoid skin burns. After the ablation of the lesion with RF or cryoablation procedure, a combination of liquid monomer and powder cement polymer was prepared and amalgamated to obtain a polymethylmethacrylate (Avatex Cardinal Health, McGaw Park, IL, USA) paste with doughy viscosity. It was then charged into a dedicated device and injected through the bone needle into the cavity created from the ablated lesion under CT guidance (Figs. 1–3).

A dedicated software, Statistica 7 (StatSoft Inc, Tulsa, OK, USA) was used for statistical analysis. The Shapiro-Wilk's W-test was used to establish the normal distribution of the baseline characteristics of the population and the VAS data. To verify the non-normal

**Table II. Comparison of baseline characteristics between patients treated with RF ablation plus vertebroplasty and patients treated with cryoablation plus vertebroplasty.**

	Mean $\pm$ SD		p-value
	RF + OP (n = 15/17 lesions)	CRYO + OP (n = 15/20 lesions)	
Age (yrs)	76.60 $\pm$ 7.70	76.20 $\pm$ 7.50	0.65
Gender (M:F)	4:11	9:6	0.07
Lesion size (cm)	2.19 $\pm$ 0.54	2.78 $\pm$ 1.38	0.46
Preoperative VAS	8.60 $\pm$ 1.23	8.70 $\pm$ 1.16	0.88
Intraoperative VAS	9.20 $\pm$ 1.10	8.00 $\pm$ 1.30	0.01
Postoperative VAS			
4 hrs	8.80 $\pm$ 0.90	7.20 $\pm$ 1.00	< 0.001
24 hrs	8.80 $\pm$ 0.90	5.40 $\pm$ 1.30	< 0.001
1 wk	4.30 $\pm$ 1.60	3.80 $\pm$ 1.40	0.34
1 mth	2.70 $\pm$ 0.80	2.70 $\pm$ 0.90	1.00
3 mths	2.10 $\pm$ 0.80	2.30 $\pm$ 0.90	0.68
6 mths	1.90 $\pm$ 0.80	2.10 $\pm$ 0.80	0.65

SD: standard deviation; RF + OP: radiofrequency ablation plus osteoplasty; CRYO + OP: cryoablation plus osteoplasty; VAS: visual analogue scale



**Fig. 4** Graphs show the trend of pain in patients treated with (a) RF ablation, where an improvement was observed only at one week post procedure; (b) cryoablation, where a decrease in pain was observed during the intraprocedural period, as evaluated using the visual analogue scale.

distribution of the data, the Mann-Whitney U test was used to compare the values between patients treated with cryoablation and those treated with RF ablation. A p-value < 0.05 was considered to be statistically significant.

## RESULTS

There were 30 patients with bone metastatic disease, of which 13 were male and 17 were female (Table I). Two patients had three lesions, three had two lesions and 25 had one lesion, giving a total of 37 lesions. 15 patients, with a total of 20 lesions, were treated with RF ablation followed by osteoplasty. Another 15 patients, with a total of 17 lesions, were treated with cryoablation followed by osteoplasty. The mean age of the patients was 76.4  $\pm$  7.5

(range 61–89) years, and the mean diameter of the lesions was 25  $\pm$  11 (range 15–70) mm.

There were no statistically significant differences between patients treated with RF ablation plus osteoplasty and those treated with cryoablation plus osteoplasty with regard to age (76.6  $\pm$  7.7 vs. 76.2  $\pm$  7.5,  $p = 0.65$ ), gender (M/F: 4/11 vs. 9/6,  $p = 0.07$ ) and bone metastatic lesion size (2.19  $\pm$  0.54 vs. 2.78  $\pm$  1.38,  $p = 0.46$ ) (Table II). The metastases treated with cryoablation plus vertebroplasty originated from breast ( $n = 5$ ), prostate ( $n = 3$ ), lung ( $n = 2$ ), myeloma ( $n = 2$ ), liver ( $n = 1$ ), gastric ( $n = 1$ ) and colon ( $n = 1$ ) cancers; the ones treated with RF ablation originated from breast ( $n = 7$ ), lung ( $n = 3$ ), prostate ( $n = 3$ ) and colon ( $n = 2$ ) cancers. The bone lesions in patients

treated with RF ablation plus osteoplasty were localised in the dorsal column (n = 3), lumbar column (n = 7), sacrum (n = 2), sterni (n = 1), ilium (n = 1) and tibia (n = 1); in the cryoablation group, while metastases were localised in the dorsal column (n = 6), lumbar column (n = 2), sacrum (n = 2), femur (n = 3) and ilium (n = 2).

There were no statistically significant differences in the preoperative VAS response between patients treated with cryoablation plus osteoplasty and those treated with RF ablation plus osteoplasty ( $8.7 \pm 1.16$  vs.  $8.6 \pm 1.23$ ,  $p = 0.88$ ) (Fig. 4). Intra-procedural evaluation of pain revealed that the mean VAS scores were lower in patients treated with cryoablation plus osteoplasty than in those treated with RF plus osteoplasty ( $8.0 \pm 1.3$  vs.  $9.2 \pm 1.1$ ,  $p = 0.01$ ). Similar results were observed in the VAS responses at four hours ( $7.2 \pm 1$  vs.  $8.8 \pm 0.9$ ,  $p < 0.001$ ) and 24 hours ( $5.4 \pm 1.3$  vs.  $8.8 \pm 0.9$ ,  $p < 0.001$ ) post procedure (Table II). No significant differences were observed between patients treated with the combined procedure of cryoablation plus osteoplasty and those treated with RF plus osteoplasty at one week ( $3.8 \pm 1.4$  vs.  $4.3 \pm 1.6$ ,  $p = 0.34$ ), one month ( $2.7 \pm 0.9$  vs.  $2.7 \pm 0.8$ ,  $p = 1$ ), three months ( $2.3 \pm 0.9$  vs.  $2.1 \pm 0.8$ ,  $p = 0.68$ ) and six months ( $2.1 \pm 0.8$  vs.  $1.9 \pm 0.8$ ,  $p = 0.65$ ) follow-up (Table II, Fig. 4).

Out of 30 patients, 29 (97%) suspended their narcotic therapy after the combined interventional procedure and during the follow-up period, while one (3%) patient continued his therapy for pain refractory. In four (13%) patients, the residual pain was controlled with NSAIDs, while 25 (83%) patients completely suspended their analgesic therapy. During RF procedure, six patients experienced acute to moderate pain and were treated with NSAIDs or opioids, which were administered for up to 24 hours; in two patients, ketoralac (60 mg) and tramadol (200 mg) were administered via an elastomeric pump for more than 24 hours. The most common complication was localised pain at the needle entry sites in the first 72 hours after the procedure, usually caused by local bruising (during RF ablation), which was resolved with mild analgesics. Only one (3%) patient experienced mild radiculopathy after the RF treatment. No further periprocedural and long-term complications were observed, and no evidence of tumour cell seeding was noted. During the follow-up period, two (6%) patients died due to reasons unrelated to the procedure.

## DISCUSSION

Bone metastases pain has no correlation with site, extent and histological type of the primary tumour. The physiopathological mechanism of pain is based

on the release of chemical agents by overturned bone and tumour cells, resulting in stimulation of endosteal nerves, inhibition of osteoblastic activity, periosteal stretching, pathological fractures, as well as infiltration and compression of nerve and surrounding tissues.<sup>(5,33,34)</sup> Patients with metastatic tumour generally have short life expectancy and poor quality of life. Treatment is aimed at palliation and improvement of the performance status. The input of image-guided percutaneous ablation therapies with different ablative materials and techniques offers an alternative option for patients who are intolerant or unresponsive to standard treatments such as like radiotherapy and pharmacotherapy, yielding the benefit of miniminvasivity as well as prompt results, low adverse effects and shorter hospitalisation stay.

Bone metastasis alcohol ablation was the first successful technique used.<sup>(14,36,37)</sup> It was later replaced by RF ablation, as the latter offers better pain control, greater versatility and less adverse effects.<sup>(27)</sup> RF ablation involves the application of alternating electric current in the RF range through an electrode placed in the tumour, generating ionising friction to produce a local thermal injury as coagulation necrosis at a temperature of 60°–100°C. Cryoablation technique uses argon gas as cryogen to freeze a tissue (up to –180° C), resulting in protein denaturation, cell membrane rupture and eventual cell death. Unlike radiation therapy, the ability of these percutaneous procedures to induce cell killing is not dependent on the genetic characteristics of individual cells but on the exposure of the whole tumour to the lethal necrosing process.<sup>(38)</sup>

The ablation of tumoural tissue in both RF ablation and cryoablation may be complemented by cement injection with optimal results, as reported in previous studies<sup>(39,41)</sup> and in our experience.<sup>(42,44)</sup> The advantages of the ablation-cementoplasty combined protocol are the optimisation of cement distribution into the ablated tissue and bone stabilisation in a single session. Ablative cavitation of the osteolytic lesion promotes cement distribution, especially in infiltrative tumours that are extended to nearby tissues, by engulfing extraosseous extension itself, thus enhancing the efficacy of the ablative technique. Osseous instability is one of the causes of pain, and in spinal localisation, where radiation therapy alone worsens the condition, it increases the risk of fracture. Cement injection provides immediate post-procedural relief, and in some cases, prevents the patient from future fractures.

From our experience, both RF ablation and cryoablation have proven to be safe and effective procedures, with no evidence of long-term complications but only mild, short-term ones. We observed only two

cases of haematoma at the site of injection and one case of radiculopathy in a patient treated on a dorsal vertebra, moreover returned after a few days. The results of the combined procedures with RF ablation plus cementoplasty or cryoablation plus cementoplasty demonstrate a significant reduction in pain, as evaluated by the VAS, with no difference between the two procedures at long-term follow-up (up to six months). However, major pain reduction was observed in patients treated with cryoablation compared to those treated with RF ablation within 24 hours post procedure. This may be due to the partially freezing analgesia obtained at low temperatures as well as the minimally aggressive effects on tissues surrounding the tumoral lesion in contrast to the high temperatures used in RF ablation, resulting in thermal injury to the adjacent tissues. Percutaneous RF ablation has been reported to be an effective palliative treatment for spine metastases, but it was limited by potential damages to adjacent neural tissue due to the high temperatures generated. Therefore, some have claimed that posterior wall wracking lesions with soft tissue involvement are not suitable for percutaneous treatment.<sup>(25)</sup>

Some published studies and guidelines have contraindicated bone lesion vertebroplasty in cases of posterior wall cortical disruption and/or large epidural extension, pathological vertebral fractures with retropulsion of the fragments within neural foramina, tumour spread within the epidural space, tumour involvement or missing integrity of the pedicles or joint facets, while an intact posterior wall provides at least partial insulation of the spinal canal from high temperatures.<sup>(7-9)</sup>

Buy et al as well as Georgy and Wong have suggested the use of saline solution to create a targeted focused ablation with relatively low temperatures (40–70°C).<sup>(29,41)</sup> We resolved this problem by performing ablation of the metastatic lesion to create a cavity in which the cement could spread itself, and also with the use of a remote temperature sensor positioned near the active electrode tip and/or the spinal canal, which offered a safe protection margin. In particular, we used thermocouples for the RF procedure and thermosensors for cryoablation.

As shown in our study, cryoablation is minimally aggressive on tissues surrounding the tumoral lesion, and the ablation margins can be effectively monitored during the procedure using direct CT iceball visualisation, while in RF ablation procedure, the monitoring can be done by visualisation of gas bubbles generated in the tumoural necrotic tissue. The depiction of ablation margins is

very important in order to establish precisely the soft-tissue/bone interface where the mechanisms involved in pain pathogenesis occur. Moreover, direct visualisation of the entire ablation volume is the aim of an extensive destruction of the lesion prongs. In our study, patients who were treated with cryoablation experienced partially freezing analgesia, achieving ablation without general anaesthesia or conscious sedation, and they were monitored through a non-invasive approach. These patients did not require analgesic administration, while four patients who underwent RF ablation required analgesics for 72 hours post procedure.

There are some limitations to our study. This was a retrospective, non-randomised study. The sample size was small, with a heterogeneous primary tumour type and site of treatment. The follow-up period was also inadequate to define long-term outcomes through the observation of long-term survivors. Future randomised, prospective multi-centre trials comparing percutaneous ablation and other traditional treatments should be conducted to compare the outcomes of these alternative therapies. In conclusion, both RF ablation and cryoablation, in combination with the cementoplasty, are beneficial techniques for the treatment of painful bone metastatic cancer.

## REFERENCES

1. Wong DA, Fornasier VL, MacNab I. Spinal metastases: the obvious, the occult, and the impostors. *Spine* 1990; 15:1-4.
2. Hage WD, Aboulafia AJ, Aboulafia DM et al. Incidence, location and diagnostic evaluation of metastatic bone disease. *Orthop Clin North Am* 2000; 31:515-28.
3. Bohm P, Huber J. The surgical treatment of bony metastases of the spine and limbs. *J Bone Joint Surg Br* 2002; 84:521-9.
4. Nielsen OS, Munro AJ, Tannock IF. Bone metastases: pathophysiology and management policy. *J Clin Oncol* 1991; 9:509-24.
5. Mercadante S. Malignant bone pain: pathophysiology and treatment. *Pain* 1997; 69:1-18.
6. Janjan N. Bone metastases: approaches to management. *Semin Oncol* 2001; 28:28-34.
7. Poulsen HS, Nielsen OS, Klee M, Rorth M. Palliative irradiation of bone metastases. *Cancer Treat Rev* 1989; 16:41-8.
8. Massie MJ, Holland JC. The cancer patient with pain: psychiatric complications and their management. *J Pain Symptom Manage* 1992; 7:99-109.
9. Spiegel D, Sands S, Koopman C. Pain and depression in patients with cancer. *Cancer* 1994; 74:2570-8.
10. Jeremic B, Shibamoto Y, Acimovic L, et al. A randomized trial of three single-dose radiation therapy regimens in the treatment of metastatic bone pain. *Int J Radiat Oncol Biol Phys* 1998; 42:161-7.
11. Gaze MN, Kelly CG, Kerr GR, et al. Pain relief and quality of life following radiotherapy for bone metastases: a randomised trial of two fractionation schedules. *Radiother Oncol* 1997; 45:109-16.
12. Gangi A, Kastler B, Klinkert A, et al. Injection of alcohol into bone metastases under CT guidance. *J Comput Assist Tomogr* 1994; 18:932-5.
13. Cotten A, Demondion X, Boutry N, et al. Therapeutic percutaneous injections in the treatment of malignant acetabular

- osteolyses. *Radiographics* 1999; 19:647-53.
14. Gangi A, Gasser B, De Unamuno S, et al. New trends in interstitial laser photocoagulation of bones. *Semin Musculoskelet Radiol* 1997; 1:331-8.
  15. Gröenemeyer DH, Schirp S, Gevargez A. Image-guided percutaneous thermal ablation of bone tumors. *Acad Radiol* 2002; 9:467-77.
  16. Mathis JM, Barr JD, Belkoff SM, et al. Percutaneous vertebroplasty: a developing standard of care for vertebral compression fractures. *Am J Neuroradiol* 2001; 22:373-81.
  17. Cotten A, Boutry N, Cortet B, et al. Percutaneous vertebroplasty: state of the art. *Radiographics* 1998; 18:311-23.
  18. Cotten A, Deprez X, Migaud H, et al. Malignant acetabular osteolyses: percutaneous injection of acrylic bone cement. *Radiology* 1995; 197:307-10.
  19. Marcy PY, Palussiere J, Descamps B, et al. Percutaneous cementoplasty for pelvic bone metastasis. *Support Care Cancer* 2000; 8:500-3.
  20. Hierholzer J, Anselmetti G, Fuchs H, et al. Percutaneous osteoplasty as a treatment for painful malignant bone lesions of the pelvis and femur. *J Vasc Interv Radiol* 2003; 14:773-7.
  21. Alvarez L, Perez-Higuera A, Quinones D, Calvo E, Rossi RE. Vertebroplasty in the treatment of vertebral tumours: postprocedural outcome and quality of life. *Eur Spine J* 2003; 12:356-60.
  22. Cooper I. Cryogenic surgery: a new method of destruction or extirpation of benign or malignant tissues. *N Engl J Med* 1963; 268:743-49.
  23. Sewell P, Jackson M, Dhillon G. Percutaneous MRI guided cryosurgery of bone tumors. *Radiology* 2002; 225:514.
  24. Callstrom MR, Atwell TD, Charboneau JW, et al. Painful metastases involving bone: percutaneous image-guided cryoablation-prospective trial interim analysis. *Radiology* 2006; 241:572-80.
  25. Dupuy DE, Hong R, Oliver B, et al. Radiofrequency ablation of spinal tumors: temperature distribution in the spinal canal. *AJR Am J Roentgenol* 2000; 175:1263-6.
  26. Callstrom MR, Charboneau JW, Goetz MP, et al. Painful metastases involving bone: feasibility of percutaneous CT and US-guided radio-frequency ablation. *Radiology* 2002; 224:87-97.
  27. Goetz MP, Callstrom MR, Charboneau JW et al. Percutaneous image-guided radiofrequency ablation of painful metastases involving bone: a multicenter study. *J Clin Oncol* 2004; 22:300-6.
  28. Posteraro AF, Dupuy DE, Mayo-Smith WW. Radiofrequency ablation of bony metastatic disease. *Clin Radiol* 2004; 59:803-11.
  29. Buy X, Basile A, Bierry G, Cupelli J, Gangi A. Saline-infused bipolar radiofrequency ablation of high-risk spinal and paraspinous neoplasms. *AJR Am J Roentgenol* 2006; 186:S322-6.
  30. Chapman CR, Case KI, Dubner R, et al. Pain measurement: an update. *Pain* 1985; 22:1-31
  31. Hoffmann NE, Bischof JC: The cryobiology of cryosurgical injury. *Urology* 2002; 60:40-9.
  32. Gage AA, Baust J. Mechanisms of tissue injury in cryosurgery. *Cryobiology* 1998; 37:171-86.
  33. Mantyh PW, Clohisey DR, Koltzenburg M, Hunt SP. Molecular mechanisms of cancer pain. *Nat Rev Cancer* 2002; 2:201-9
  34. Mannion RJ, Woolf CJ. Pain mechanisms and management: a central perspective. *Clin J Pain* 2000; 16:S144-56
  35. Tong D, Gillick L, Hendrickson FR. The palliation of symptomatic osseous metastases: final results of the study by the Radiation Therapy Oncology Group. *Cancer* 1982; 50:893-9.
  36. Steenland E, Leer JW, van Houwelingen H, et al. The effect of a single fraction compared to multiple fractions on painful bone metastases: a global analysis of the Dutch Bone Metastasis Study. *Radiother Oncol* 1999; 52:101-9. Erratum in: *Radiother Oncol* 1999; 53:167.
  37. Gangi A, Dietemann JL, Schultz A, et al. Interventional radiologic procedures with CT guidance in cancer pain management. *Radiographics* 1996; 16:1289-304.
  38. Bahn DK, Silverman P, Lee F Sr, et al. In treating localized prostate cancer the efficacy of cryoablation is independent of DNA ploidy type. *Technol Cancer Res Treat* 2004; 3:253-7
  39. Schaefer O, Lohrmann C, Herling M, Uhrmeister P, Langer M. Combined radiofrequency thermal ablation and percutaneous cementoplasty treatment of a pathologic fracture *J Vasc Interv Radiol* 2002; 13:1047-50.
  40. Toyota N, Naito A, Kakizawa H, et al. Radiofrequency ablation therapy combined with cementoplasty for painful bone metastases: initial experience. *Cardiovasc Intervent Radiol* 2005; 28:578-83.
  41. Georgy B, Wong W. Plasma-mediated radiofrequency ablation assisted percutaneous cement injection for treating advanced malignant vertebral compression fractures. *Am J Neuroradiol* 2007; 28:700-5.
  42. Masala S, Manenti G, Roselli M, Mammucari M, et al. Percutaneous combined therapy for painful sternal metastases: a radiofrequency thermal ablation (RFTA) and cementoplasty protocol. *Anticancer Res* 2007; 27:4259-62.
  43. Masala S, Roselli M, Manenti G, et al. Percutaneous cryoablation and vertebroplasty: a case report. *Cardiovasc Intervent Radiol* 2008; 31:669-72.
  44. Masala S, Roselli M, Massari F, et al. Radiofrequency heat ablation and vertebroplasty in the treatment of neoplastic vertebral body fractures. *Anticancer Res* 2004; 24:3129-33.