

# Endovascular revascularisation of popliteal artery occlusions: two complex cases

Toh L M H W, Taneja M, Sebastian M G

## ABSTRACT

**Peripheral vascular disease-related occlusions of the arteries are complex lesions that can be treated surgically or through endovascular means in symptomatic patients. In this case report, we describe two interesting cases of popliteal occlusion that were revascularised using advanced endovascular techniques to salvage the limb. The first case was a chronic popliteal artery occlusion that required atypical arterial access along with embolisation due to earlier attempted intervention to revascularise the artery. The second case was an acute embolic occlusion that was excluded from the circulation primarily rather than through the typical approach of thrombolysis or mechanical thrombectomy.**

**Keywords: complex endovascular interventions, popliteal artery occlusions**

*Singapore Med J 2011;52(3):e40-e44*

## INTRODUCTION

Peripheral vascular disease (PVD) is estimated to affect about 8.6% of our local population.<sup>(1)</sup> Its prevalence is higher in the diabetic population, with an estimated 15.2% of these patients affected by the disease (8.0% for subjects < 60 years, 21.9% for subjects ≥ 60 years).<sup>(2)</sup> PVD is asymptomatic in its early stages, usually detected by reduced ankle-brachial index (ABI < 0.9). With disease progression, these patients present with intermittent claudication, deteriorating to rest pain and ulceration with or without tissue loss. This is usually related to multifocal stenoses or occlusions in the arterial supply to the foot.

The estimated incidence of critical limb ischaemia (CLI) is 220 new cases per million population every year.<sup>(3)</sup> Most of these patients have multisystem cardiovascular atheromatous disease with associated comorbidities involving the coronary arteries and cerebrovascular supply. Limb salvage in this group of patients is considered to be important, as life expectancy has been shown to be reduced in patients undergoing major limb amputation.<sup>(4)</sup> CLI is commonly

seen in our practice in Singapore, with patients requiring urgent revascularisation of the arteries to enable limb salvage. Clinically significant popliteal artery occlusions contributing to CLI is seen in about 5% of patients in our practice.

In this article, we report two patients who presented to us with threatened limb secondary to multifocal atheromatous disease causing critical popliteal occlusions. We describe our experience with advanced endovascular techniques that were used to recanalise the popliteal occlusions, the problems encountered and the approaches used to deal with these complications through the endovascular approach.

## CASE REPORT

### Case 1

A 54-year-old Chinese man presented to the hospital with progressively worsening wet gangrene of the left fourth and fifth toes three days before admission to hospital. The associated comorbidities included non-insulin-dependent diabetes mellitus, end-stage renal failure, hypertension and ischaemic heart disease.

On clinical examination of the peripheral vasculature, the patient was found to have a palpable femoral arterial pulse at the left groin, no popliteal pulse, and feeble dorsalis pedis and posterior tibial artery pulses at the ankle. Doppler examination showed multifocal arterial disease with chronic popliteal artery occlusion and a single vessel run-off to the left foot through the posterior tibial artery. Based on the clinical results, it was decided after joint discussion with the vascular surgeons and radiologist to perform emergency amputation of the left fourth and fifth toes, followed by endovascular revascularisation of the arteries to establish a single line native arterial flow to the foot.

Antegrade left common femoral artery access was obtained, followed by an angiogram through the sheath. This confirmed the presence of chronic occlusion of the popliteal artery extending into its distal bifurcation with collaterals reforming posterior tibial artery in the calf, which was the only supply to the foot (Fig. 1). Attempts to recanalise the chronic popliteal occlusion were made

**Department of Diagnostic Radiology, Singapore General Hospital, Outram Road, Singapore 169608**

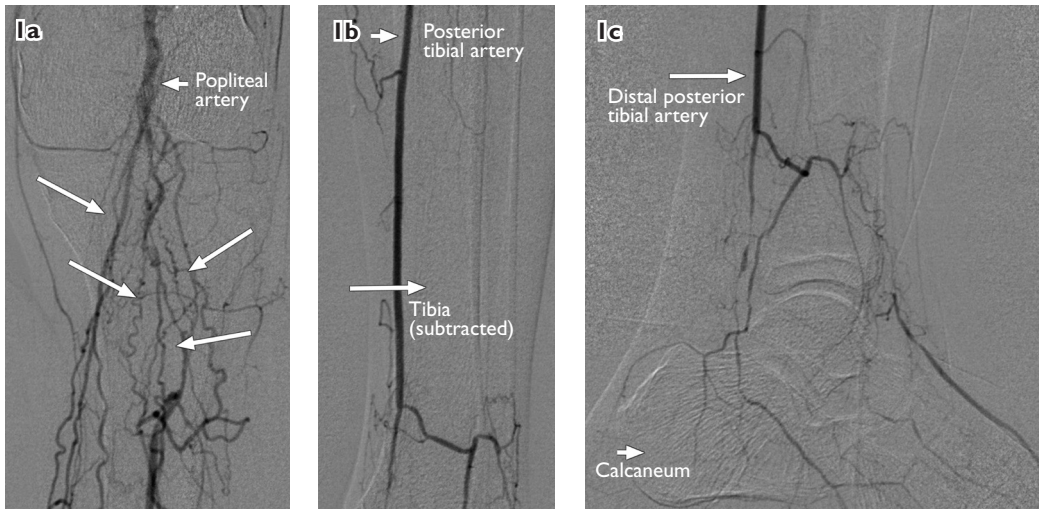
Toh LMHW, MBBS, FRCR, MMed Registrar

Taneja M, MBBS, MD, FRCR Consultant Cardiovascular and Interventional Radiologist

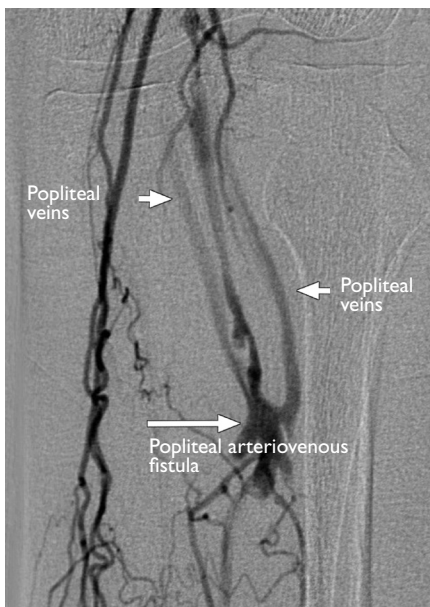
**Department of Surgery**

Sebastian MG, MBBS, MMed, FRCSE Senior Consultant and Vascular Surgeon

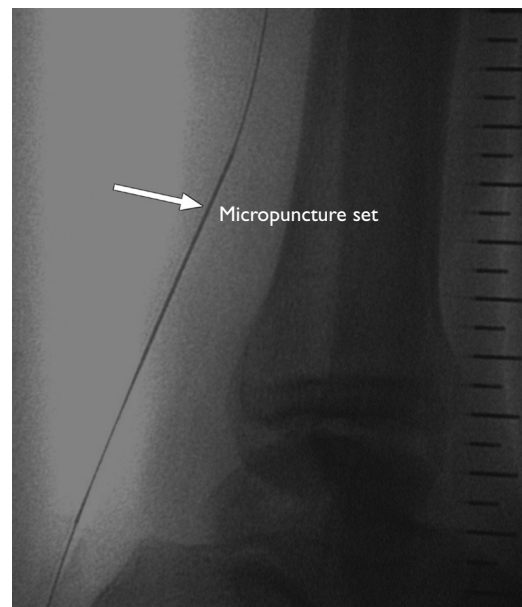
**Correspondence to:**  
Dr Luke Toh  
Tel: (65) 9382 2188  
Fax: (65) 6326 5161  
Email: hwtoh@singnet.com.sg



**Fig. 1** (a–c) Digital subtraction angiograms show chronic occlusion of the popliteal artery extending into its distal bifurcation, with collaterals reformed the posterior tibial artery in the calf, which was the only supply to the foot (long arrows in Fig. 1a refer to collateral vessels).



**Fig. 2** Digital subtraction angiogram shows an iatrogenic popliteal artery-to-vein high-flow arteriovenous fistula as a direct result of earlier intervention.



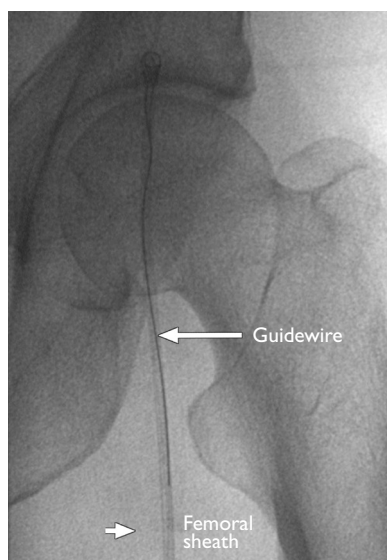
**Fig. 3** Radiograph shows retrograde access of the posterior tibial artery, which was obtained at the ankle using a micropuncture set (arrow).

initially through the intraluminal approach, followed by the subintimal approach. This was unsuccessful at that time as the patient was getting increasingly uncooperative and restless. A decision was made to recall the patient for another session of intervention under deep conscious sedation, with attempted recanalisation of the popliteal occlusion through the antegrade left common femoral (downhill) and retrograde posterior tibial artery (uphill) approach at the ankle using the 'body-floss' technique. This involves passing a wire introduced from the ankle vascular access site and taken out of the artery via the femoral vascular sheath.

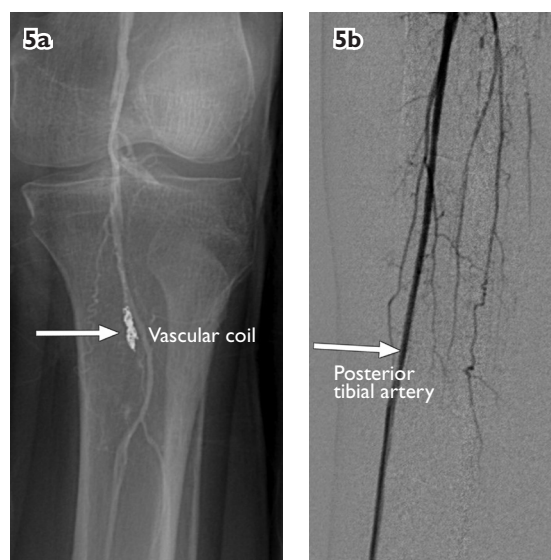
The patient was brought back in for a second session

of intervention two days later. The preliminary angiogram showed a new development; an iatrogenic popliteal artery-to-vein high-flow arteriovenous fistula as a direct result of the intervention attempted earlier (Fig. 2). The arterial supply to the arteriovenous communication was coming off a side branch of the popliteal artery. A decision was made to revascularise the occlusion and embolise the iatrogenic popliteal artery-to-vein fistula with coils.

Retrograde access of the posterior tibial artery was obtained at the ankle using a micropuncture set (Fig. 3). The popliteal occlusion was crossed through this approach using a 0.014-inch guidewire,



**Fig. 4** Radiograph shows a guidewire in the femoral sheath of the left groin, which was subsequently snared out to create a 'body-floss'.



**Fig. 5** (a & b) Digital subtraction completion angiograms show good result with patent native popliteal artery, occluded fistula, and disappearance of collaterals with straight-line flow established to the foot through the native popliteal artery.

with the wire snared out through the femoral artery sheath in the left groin (Fig. 4). The popliteal artery occlusion was recanalised with balloon angioplasty of the occlusion. The occluded popliteal artery opened up well with balloon angioplasty, but there was a persistent iatrogenic popliteal artery-to-vein fistula with significant arteriovenous shunting. The site of the iatrogenic fistula was selectively catheterised with a microcatheter via the antegrade approach from the left common femoral artery, followed by embolisation with microcoils. Completion angiogram showed good result with the occluded fistula, disappearance of collaterals and straight-line flow established to the foot through the native popliteal artery (Fig. 5). The patient's foot showed good healing at the toe amputation site over the following few days.

#### Case 2

An 84-year-old Chinese woman presented with a ten-day history of severe pain in the left calf and foot, and difficulty in walking. She had a history of mild to moderate rest pain over the preceding few months, with recent aggravation of symptoms. Pertinent comorbidities included non-insulin-dependent diabetes mellitus, hypertension and ischaemic heart disease.

Doppler study showed an acute occlusion within the popliteal artery with multifocal infra-popliteal stenoses and occlusions. The patient was brought in immediately for an angiogram with a view to detect possible thrombolysis using overnight intra-arterial urokinase infusion. Antegrade left common femoral artery access

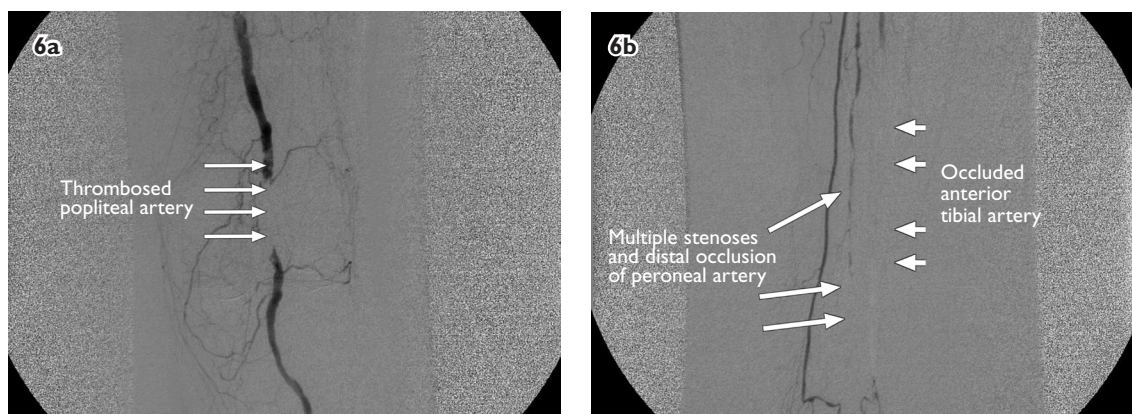
was obtained and an angiogram was performed. The angiographic appearance was that of an acute thrombus on a background of chronic occlusive disease affecting distal popliteal and infra-popliteal arteries (Fig. 6).

Due to the associated risk of complications of thrombolytic therapy, especially in an elderly patient, it was decided to exclude the thrombus instead of dissolving it with urokinase, followed by angioplasty, which is the traditional standard endovascular technique for managing these patients. The acute thrombus was trapped outside the true lumen with a primary covered stent. Revascularisation of the chronically occluded anterior tibial artery was also performed during the same session. Completion angiogram showed complete exclusion of the thrombus, with patent underlying artery and good flow to the foot through two vessels (Fig. 7). The patient responded very well to the treatment and was fully mobile the following morning. She was discharged within the same week.

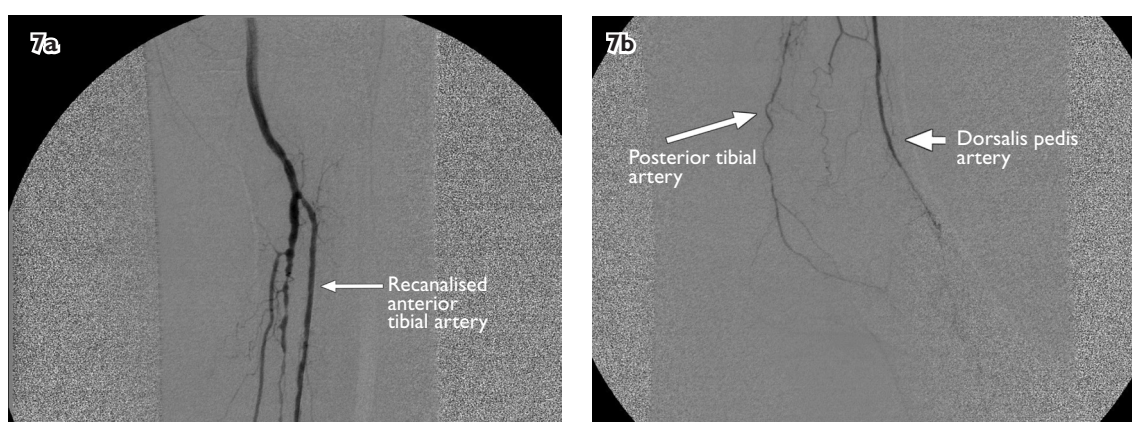
#### DISCUSSION

Various endovascular techniques for recanalisation of occluded arteries in the leg have been described. These include balloon angioplasty, bare nitinol stents, stent-grafts, cryoplasty, percutaneous atherectomy and endovascular laser therapy.<sup>(5-10)</sup> Occlusions of the popliteal artery are more appropriately treated using balloon angioplasty, stent grafts or percutaneous atherectomy due to its location overlying the knee joint.

In Case 1, posterior tibial artery (pedal) access was used for revascularisation of the popliteal and



**Fig. 6** Digital subtraction angiograms show (a) acute thrombus in the left mid-popliteal artery; and (b) severe atheromatous disease in the same limb with multi-level occlusions in the infra-popliteal arteries.



**Fig. 7** (a & b) Digital subtraction completion angiograms show complete exclusion of the thrombus, with patent underlying artery and good flow to the foot through two vessels.

infra-popliteal arteries. Pedal access for recanalisation or angioplasty of infra popliteal arteries is a relatively recent technique that has yielded good results and no significant adverse outcome.<sup>(11)</sup> This technique enables revascularisation of occluded arteries in which the traditional downhill antegrade approach is unsuccessful.

We follow the same protocol in treating infra-popliteal occlusions in patients who initially undergo attempted revascularisation through the antegrade approach. Pedal access is used if traditional downhill approach fails. We routinely use this technique for revascularisation of infra-popliteal arteries. This was our first case where pedal access was used for popliteal occlusion revascularisation. We had ensured that no large sheath (4F or larger) was used during pedal access, since these sheaths can damage and distally occlude the artery being treated, and can even potentially prevent any future surgical bypass operation on the artery.

In Case 2, the traditional endovascular method used was intra-arterial catheter directed thrombolysis followed by angioplasty, if required. Exclusion of the acute clot

in arterial occlusions using covered stents is a relatively recent technique. This approach has been used in a small series described for acute iliac occlusions.<sup>(12)</sup> Its obvious advantage is reduced complications secondary to high-dose thrombolytic therapy, particularly in the elderly population. There is always a risk of distal embolisation during this approach, with aggravation of the symptoms. However, with adequate precautions, such as non-traumatic crossing of occlusion, primary stent placement with no pre-dilatation, adequate length and size of guiding sheath or catheter and using distal protection if required, this can be achieved. The technique can be modified on a case-by-case basis.

Our two cases illustrate atypical techniques in managing arterial occlusions in separate challenging situations. They enabled us to treat our patients more effectively in a less invasive manner compared to the traditionally used surgical intervention. All endovascular interventionists should be familiar with these advanced techniques so as to treat these patients, who often have multiple associated comorbidities, through minimally

invasive means. These recent advances in endovascular peripheral interventions are helpful in managing patients with severe peripheral vascular disease, significantly reducing morbidity and mortality while providing effective treatment at the same time.

## REFERENCES

1. Yeo TC, Chan YH, Low LP, et al. Risk factor profile and treatment patterns of patients with atherothrombosis in Singapore: insight from the REACH Registry. *Ann Acad Med Singapore* 2008; 37:365-71.
2. Phang J, Koh WP. Peripheral Arterial Disease among Diabetic Patients in the Community. In: *Proceedings of the 18th WONCA World Conference 2007*. Abstract 350.
3. Norgren L, Hiatt WR, Dormandy JA, et al. Inter-Society Consensus for the Management of Peripheral Arterial Disease (TASC II). *Eur J Vasc Surg* 2007; 45:S5-67.
4. Melssner OA, Rieger J, Weber C, et al. Critical limb ischemia: hybrid MR angiography compared with DSA. *Radiology* 2005; 235:308-18.
5. Lagana D, Carrafiello G, Dizonno M, et al. Percutaneous treatment of complete chronic occlusions of the superficial femoral artery. *Radiol Med* 2008; 113:567-77.
6. Ferreira M, Lanziotti L, Monteiro M, et al. Superficial femoral artery recanalization with self-expanding nitinol stents: long-term follow-up results. *Eur J Vasc Endovasc Surg* 2007; 34:702-8.
7. Fischer M, Schwabe C, Schulte KL. Value of the hemobahn/viabahn endoprosthesis in the treatment of long chronic lesions of the superficial femoral artery: 6 years of experience. *J Endovasc Ther* 2006; 13:281-90.
8. Samson RH, Showalter DP, Lepore M Jr, Nair DG, Merigliano K. Cryoplasty therapy of the superficial femoral and popliteal arteries: a reappraisal after 44 months' experience. *J Vasc Surg* 2008; 48:634-7.
9. McKinsey JF, Goldstein L, Khan HU, et al. Novel treatment of patients with lower extremity ischemia: use of percutaneous atherectomy in 579 lesions. *Ann Surg* 2008; 248:519-28.
10. Scheinert D, Laird JR Jr, Schroder M, et al. Excimer laser-assisted recanalization of long, chronic superficial femoral artery occlusions. *J Endovasc Ther* 2001; 8:156-66.
11. Spinosa DJ, Leung DA, Harthun NL, et al. Simultaneous antegrade and retrograde access for subintimal recanalization of peripheral arterial occlusion. *J Vasc Interv Radiol* 2003; 14:1449-54.
12. Berczi V, Thomas SM, Turner DR, et al. Stent implantation for acute iliac artery occlusions: initial experience. *J Vasc Interv Radiol* 2006; 17:645-9.