

CME Article

Regular narrow complex tachycardia

Singh D, Teo S G, Poh K K

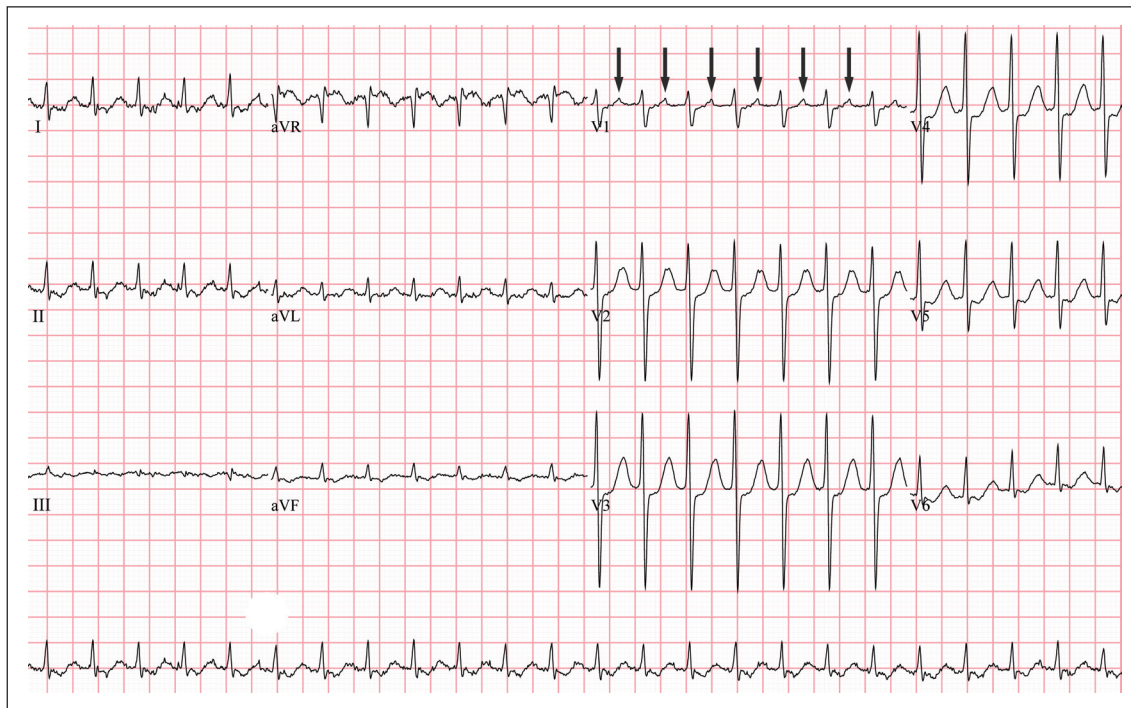


Fig. 1 ECG shows regular narrow complex tachycardia, with retrograde P waves clearly seen in lead V1 (arrows). Note that the RP interval is shorter than the PR interval, i.e. short RP tachycardia.

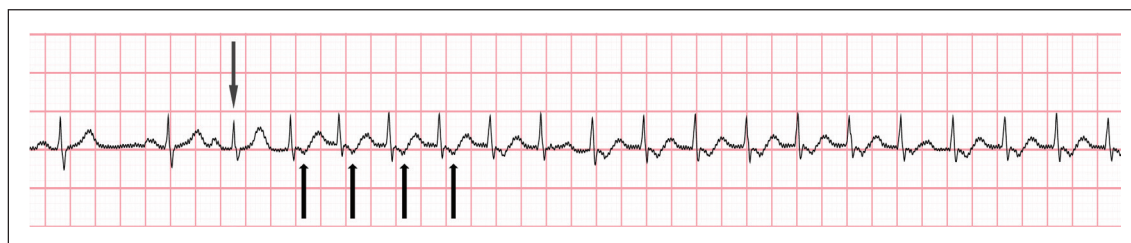


Fig. 2 Telemetry strip shows the onset of regular narrow complex tachycardia initiated by an atrial premature complex (down-pointing arrow). Up-pointing arrows show P waves.

CASE I

CLINICAL PRESENTATION

A 44-year-old man presented to the emergency department with a history of palpitations for the past four hours. There was no associated symptom of giddiness or loss of consciousness. The patient denied any history of chest pain or shortness of breath. Previously, he had similar episodes of palpitation, each lasting for several minutes. He had a past history of mild hypertension that was untreated. Physical examination was unremarkable, except for a heart rate of 165 beats per minute. The blood pressure reading was 120/90 mmHg. A 12-lead electrocardiogram (ECG) was done (Fig. 1). Based on the interpretation of

the ECG, 6 mg of intravenous adenosine was administered as a fast bolus through a large bore intravenous cannula in the antecubital fossa, with continuous ECG monitoring. However, the patient's heart rate remained at 160 beats per minute. A second fast intravenous bolus of 12 mg adenosine was administered and the heart rate suddenly dropped to 80 beats per minute, with immediate relief of symptoms. 12-lead ECG showed normal sinus rhythm at a heart rate of 90 beats per minute, without any evidence of pre-excitation. The patient was admitted to the ward for observation. Telemetry recording showed intermittent episodes of tachycardia that terminated spontaneously (Fig. 2).

Cardiac Department,
National University
Heart Centre,
1E Kent Ridge Road,
NUHS Tower Block,
Level 9,
Singapore 119228

Singh D, MD, MRCP
Associate Consultant

Teo SG, MBBS,
MRCP
Consultant

Yong Loo Lin School
of Medicine

Poh KK, MBBChir,
FRCP, FACC
Senior Consultant and
Associate Professor

Correspondence to:
A/Prof Poh Kian
Keong
Tel: (65) 9237 3289
Fax: (65) 6872 2998
Email: doctorpoh@
yahoo.com

ECG INTERPRETATION

12-lead ECG (Fig. 1) shows a regular narrow QRS complex tachycardia at a heart rate of 167 beats per minute. P waves are clearly seen in lead V1 (arrows in Fig. 1). The RP interval is shorter than the PR interval (i.e. the P wave is nearer to the preceding than the following QRS complex). ST depression is also noted in the inferolateral leads. This ECG is consistent with a short RP paroxysmal supraventricular tachycardia (PSVT), which is most likely an atrioventricular reentrant tachycardia (AVRT).

Telemetry strip (Fig. 2) shows the onset of this narrow complex tachycardia. The first two beats are sinus, followed by an atrial premature complex (down-pointing arrow in Fig. 2), which initiated a run of supraventricular tachycardia (SVT). The P waves are buried within the T waves, as evident by a small inverted notch at the beginning of each T wave (up-pointing arrows).

CLINICAL COURSE

In view of the repeated episodes of palpitation in the past, the patient was offered electrophysiology study and radiofrequency ablation. Successful radiofrequency

ablation of a concealed left-sided accessory pathway was performed. The patient has been asymptomatic since then.

CASE 2

CLINICAL PRESENTATION

A 58-year-old man presented to the emergency department with a history of palpitations for six hours. It was associated with mild chest discomfort. There was no associated symptom of giddiness or syncope. The patient had a past history of ischaemic heart disease. His cardiovascular risk factors were type 2 diabetes mellitus, dyslipidaemia, hypertension and renal impairment. Clinical examination showed a heart rate of 170 beats per minute and a blood pressure reading of 120/80 mmHg. There was no sign of heart failure or cerebral hypoperfusion.

A 12-lead ECG was done (Fig. 3). Based on the ECG findings, a fast bolus of intravenous adenosine was given under continuous ECG monitoring. The heart rate suddenly dropped to 95 beats per minute, with immediate relief of his symptoms. A repeat 12-lead ECG showed normal sinus rhythm without any evidence of pre-excitation. The patient was admitted to the ward for clinical observation.

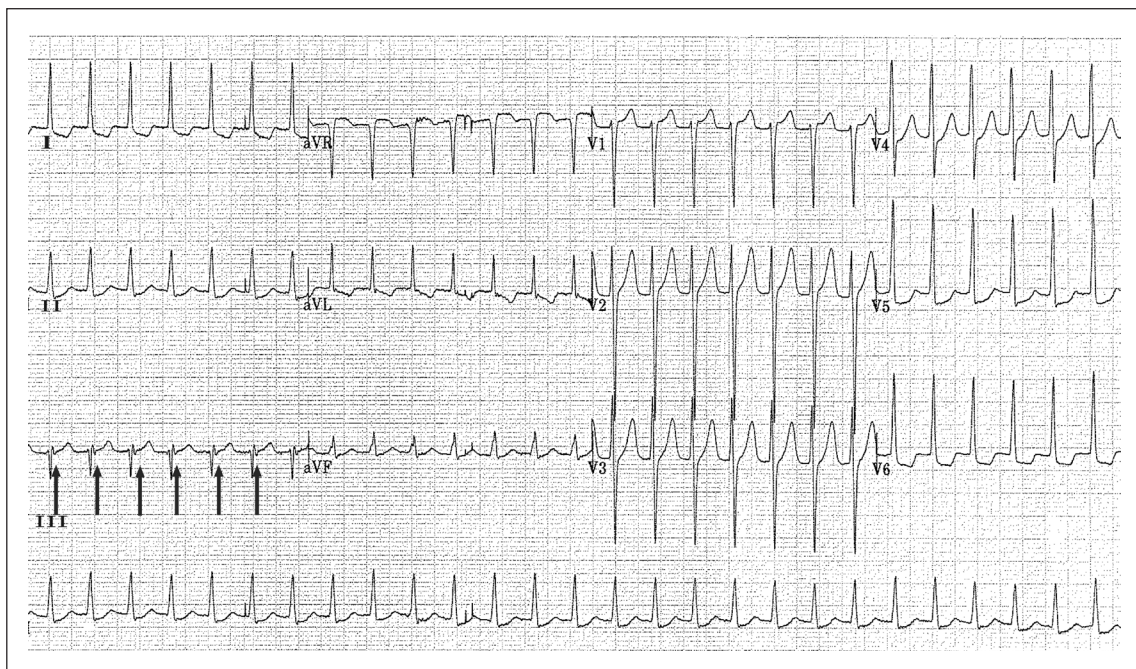


Fig. 3 12-lead ECG shows regular narrow complex tachycardia, with retrograde P wave seen as negative deflection at the end of the QRS complex in lead III (arrows). These features are consistent with an atrioventricular nodal reentrant tachycardia.

ECG INTERPRETATION

12-lead ECG (Fig. 3) shows a regular narrow QRS complex tachycardia at a rate of 170 beats per minute. There was the presence of a retrograde P wave, seen as a negative deflection at the end of the QRS complex in lead III (arrows in Fig. 3). ST segment depression was noted in the lateral leads. The ECG findings of a regular narrow complex tachycardia with retrograde P waves merging with the QRS complex are consistent with atrioventricular nodal reentrant tachycardia (AVNRT), the most common type of PSVT.

CLINICAL COURSE

The patient's stay in the hospital was uneventful. This was the first documented episode of PSVT. He was already on long-term beta-blockers due to underlying ischaemic heart disease and was advised to continue this medication, which was also useful for the prevention of future episodes of PSVT. The patient was given an appointment with a cardiac electrophysiologist in the arrhythmia clinic for further follow-up.

DISCUSSION

Tachycardias are broadly classified based on the width of the QRS complex on the surface ECG.⁽¹⁾ A narrow complex (QRS width < 120 milliseconds [ms]) reflects rapid activation of the ventricles via the normal conduction pathway, i.e. His-Purkinje system, which in turn suggests that the tachycardia originated above the AV node and is thus supraventricular. Broad complex (QRS width > 120 ms) tachycardia suggests that the ventricular activation is slow or abnormal. The most common cause of broad QRS tachycardia is an arrhythmia originating in the ventricles (e.g. ventricular tachycardia). However, SVT can also produce a broad QRS complex if there is pre-existing or rate-related abnormality in the His-Purkinje conduction system, or if the conduction occurs over an accessory pathway.

PSVT is a term used to denote intermittent SVT other than atrial fibrillation, atrial flutter and multifocal atrial tachycardia (AT). The major causes are AVNRT, AVRT, AT and sinoatrial node reentrant tachycardia (SNRT). AVNRT accounts for approximately 60% of cases, AVRT for approximately 30%, and SNRT and AT for 10% of cases.⁽²⁾ PSVTs are mainly a result of re-entry, and the site of re-entry varies in different types.^(1,3) In AVNRT, the site of re-entry is within the AV node or the perinodal tissues. In AVRT, there is an accessory pathway connecting the atrium with the ventricle that acts as the site of re-entry. If the accessory pathway can conduct antegradely during sinus rhythm, then the ECG will show a delta wave due to

pre-excitation of a ventricle.⁽⁴⁾ However, if the accessory pathway only has retrograde conduction properties, then the ECG during normal sinus rhythm does not show any pre-excitation. This type of accessory pathway is called a concealed pathway.

After assessing the haemodynamic status in a patient with a regular narrow complex tachycardia, a 12-lead ECG should be performed and analysed. The characteristics of the P wave can help in the differentiation of SVT. If the P wave morphology is similar to the sinus P wave, then the differentials are sinus tachycardia, inappropriate sinus tachycardia, SNRT or AT originating near the sinus node. If the P wave is retrograde (retrograde P is negative in leads II, III, aVF and positive in lead V1) then the differentials are mainly AVRT and AVNRT. If the P wave is neither sinus nor retrograde, i.e. it is abnormal, then the main differential is AT. After the characterisation of P wave, the RP relationship is examined. Temporal relationship between the R wave and the P wave divides the tachycardia into short and long RP tachycardia. Short RP tachycardia (RP interval less than half of RR interval) includes AVRT and typical AVNRT. Examples of long RP tachycardia (RP interval more than half of the RR interval) are atypical AVNRT and AVRT with slow conducting accessory pathway. However, if the morphology of the P wave in long RP tachycardia is abnormal but it is not a retrograde P wave, then the main differential is AT. If the P waves are undetectable, the most common arrhythmia is AVNRT. In some cases of AVNRT and rarely AVRT, the P wave is at the end of the QRS complex, creating a R' (pseudo R) wave in lead V1 or S' (pseudo S) wave in the inferior leads.^(5,6)

ECGs of the two cases discussed showed ST depression in the inferolateral leads during the episode of PSVT. ST-T changes seen during and just after conversion of paroxysmal episodes of SVT are common but nonspecific. These are poor predictors of underlying coronary artery disease with flow-limiting stenosis. A short period of observation with telemetry and serial cardiac marker levels may be adequate in the post-conversion period.⁽⁷⁾

Acute management of SVT is challenging. Haemodynamic assessments should be carried out immediately. If the patient has any sign of haemodynamic compromise, i.e. hypotension, heart failure or signs of decreased cerebral perfusion, immediate electrocardioversion should be performed. If the patient is haemodynamically stable, then intravenous adenosine is the drug of choice for acute pharmacological conversion of PSVT. Adenosine 6 mg should be administered as a fast bolus from a large bore intravenous cannula, preferably in the antecubital fossa, followed by 5 ml of normal saline flush for speed delivery to the heart. If the tachycardia

persists, adenosine should be repeated at a 12-mg bolus dose.⁽³⁾ Adenosine can produce side effects, such as flushing, nausea, vomiting, chest discomfort and dyspnoea, but these usually resolve rapidly. Other drugs that can be used in the termination of SVT are non-dihydropyridine calcium channel blockers (verapamil and diltiazem), amiodarone and procainamide. Long-term management of PSVT includes expectant management, medication and radiofrequency ablation. A first episode of PSVT can be followed up without any medication, and the patient is advised to perform vagal manoeuvres to terminate such episodes. Repeated episodes can be prevented by beta-blockers or non-dihydropyridine calcium channel blockers. Radiofrequency ablation is a safe and effective alternative to long-term medication, with a success rate exceeding 90%.⁽⁸⁾

ABSTRACT

We discuss cases of paroxysmal supraventricular tachycardia (PSVT), including the patient's presentations and clinical courses. Correct interpretation of electrocardiogram (ECG) and detailed analyses are important in differentiating the various types of PSVT. This is crucial in the immediate and long-term management of these patients.

Keywords: palpitation, narrow complex regular tachycardia, paroxysmal supraventricular tachycardia, atrioventricular nodal reentrant

tachycardia, atrioventricular reentrant tachycardia

Singapore Med J 2011;52(3): 146-150

ACKNOWLEDGEMENT

We acknowledge Professor Chia Boon Lock for his advice and help in the writing of this article.

REFERENCES

1. Ganz LI, Friedman PL. Supraventricular tachycardia. *N Engl J Med* 1995; 332:162-73.
2. Blomström-Lundqvist, C, Scheinman, MM, Aliot, EM, et al. ACC/AHA/ESC guidelines for the management of patients with supraventricular arrhythmias--executive summary: a report of the American College of Cardiology/American Heart Association Task Force on Practice Guidelines and the European Society of Cardiology Committee for Practice Guidelines (Writing Committee to Develop Guidelines for the Management of Patients With Supraventricular Arrhythmias). *Circulation* 2003; 108:1871-909.
3. Ferguson JD, DiMarco,JP. Contemporary management of paroxysmal supraventricular tachycardia. *Circulation* 2003; 107:1096-9.
4. Soo WM, Chong E, Teo SG, Poh KK. Electrocardiography series. ECG delta-waves in patients with palpitation. *Singapore Med J* 2011; 52:68-72.
5. Kalbfleisch SJ, el-Atassi R, Calkins H, et al. Differentiation of paroxysmal narrow QRS complex tachycardias using the 12-lead electrocardiogram. *J Am Coll Cardiol* 1993; 21:85-9.
6. Chauhan VS, Krahn AD, Klein,GJ, et al. Supraventricular tachycardia. *Med Clin North Am* 2001; 85:193-223.
7. Nelson SD, Kou WH, Annesley T, et al. Significance of ST depression during paroxysmal SVT. *J Am Coll Cardiol* 1988; 12:383-7.
8. Morady, F. Radio-frequency ablation as treatment for cardiac arrhythmias. *N Engl J Med* 1999; 340:534-44.

SINGAPORE MEDICAL COUNCIL CATEGORY 3B CME PROGRAMME
Multiple Choice Questions (Code SMJ 201103A)

	True	False
Question 1. The causes of narrow complex tachycardia include:		
(a) Atrioventricular nodal reentrant tachycardia.	<input type="checkbox"/>	<input type="checkbox"/>
(b) Atrioventricular reentrant tachycardia.	<input type="checkbox"/>	<input type="checkbox"/>
(c) Sinus tachycardia.	<input type="checkbox"/>	<input type="checkbox"/>
(d) Ventricular tachycardia.	<input type="checkbox"/>	<input type="checkbox"/>
Question 2. The most common symptom seen in paroxysmal supraventricular tachycardia is:		
(a) Palpitation.	<input type="checkbox"/>	<input type="checkbox"/>
(b) Syncope.	<input type="checkbox"/>	<input type="checkbox"/>
(c) Numbness of the legs.	<input type="checkbox"/>	<input type="checkbox"/>
(d) Dyspnoea.	<input type="checkbox"/>	<input type="checkbox"/>
Question 3. In paroxysmal supraventricular tachycardia:		
(a) ST-T changes may be seen.	<input type="checkbox"/>	<input type="checkbox"/>
(b) ST-T changes are good predictors of underlying coronary artery disease with flow-limiting stenosis.	<input type="checkbox"/>	<input type="checkbox"/>
(c) ST-T changes require extensive investigations.	<input type="checkbox"/>	<input type="checkbox"/>
(d) ST-T changes portend a grim prognosis.	<input type="checkbox"/>	<input type="checkbox"/>
Question 4. The most common cause of paroxysmal supraventricular tachycardia is:		
(a) Atrioventricular reentrant tachycardia.	<input type="checkbox"/>	<input type="checkbox"/>
(b) Atrioventricular nodal reentrant tachycardia.	<input type="checkbox"/>	<input type="checkbox"/>
(c) Atrial tachycardia.	<input type="checkbox"/>	<input type="checkbox"/>
(d) Ventricular tachycardia.	<input type="checkbox"/>	<input type="checkbox"/>
Question 5. In patients presenting with haemodynamically stable narrow complex tachycardia, the drugs of choice for treatment include:		
(a) Intravenous adenosine.	<input type="checkbox"/>	<input type="checkbox"/>
(b) Intravenous lignocaine.	<input type="checkbox"/>	<input type="checkbox"/>
(c) Intravenous verapamil.	<input type="checkbox"/>	<input type="checkbox"/>
(d) Oral digoxin.	<input type="checkbox"/>	<input type="checkbox"/>

Doctor's particulars:

Name in full: _____

MCR number: _____ Specialty: _____

Email address: _____

SUBMISSION INSTRUCTIONS:

(1) Log on at the SMJ website: <http://www.sma.org.sg/cme/smj> and select the appropriate set of questions. (2) Select your answers and provide your name, email address and MCR number. Click on "Submit answers" to submit.

RESULTS:

(1) Answers will be published in the SMJ May 2011 issue. (2) The MCR numbers of successful candidates will be posted online at www.sma.org.sg/cme/smj by 2 May 2011. (3) All online submissions will receive an automatic email acknowledgment. (4) Passing mark is 60%. No mark will be deducted for incorrect answers. (5) The SMJ editorial office will submit the list of successful candidates to the Singapore Medical Council.

Deadline for submission: (March 2011 SMJ 3B CME programme): 12 noon, 25 April 2011.