

Multiple indomethacin-induced colonic perforations in an adolescent

Loh A H P, Ong L Y, Liew W K, Arkachaisri T, Lee V K M, Narasimhan K L, Jacobsen A S

ABSTRACT

Colonic perforation is an uncommon cause of acute abdomen in paediatric patients, and can present a diagnostic enigma as well as management challenge to the paediatric surgeon. An adolescent developed multiple colonic perforations following a short course of oral indomethacin, requiring emergency hemicolectomy. This is the youngest known case of enteral non-steroidal anti-inflammatory drug (NSAID)-mediated large bowel injury. We review current evidence on NSAID-related enteropathy, and postulate potentiating mechanisms that may have accounted for the unusually rapid clinical course of our patient.

Keywords: adverse drug reactions, colonic diseases, indomethacin, intestinal perforation, non-steroidal anti-inflammatory drugs

Singapore Med J 2011;52(4):e82-e84

INTRODUCTION

Colonic perforation is an uncommon cause of acute abdomen in the paediatric population, and poses a diagnostic and management challenge to paediatric surgeons. Injury to the lower gastrointestinal tract related to ingestion of non-steroidal anti-inflammatory drugs (NSAIDs) is uncommon and far less studied than the gastroduodenal, renal and respiratory complications of these drugs. Although rare, NSAID enteropathy often presents acutely with serious complications such as perforation, stricture or ulceration,⁽¹⁾ which may have added impact on the paediatric patient. Gut complications are thought to arise from the topical effects of drug contact with mucosa or from systemic effects causing arachidonic acid metabolism, and their frequency has been shown to be related to treatment dose and duration.^(2,3) We describe a case of multiple colonic perforations in a previously healthy teenage girl who required hemicolectomy following a short period of oral intake of indomethacin.

CASE REPORT

A 15-year-old girl presented with four days of sore

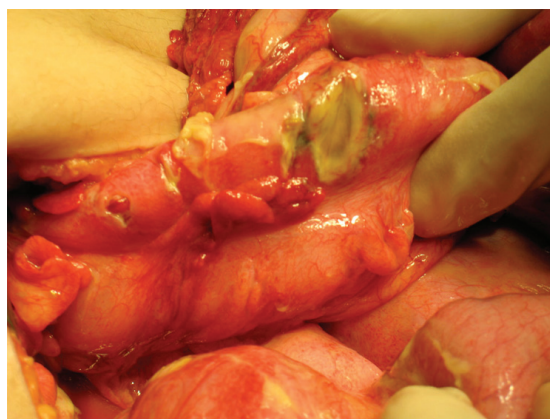

Fig. 1 Intraoperative photograph shows multiple perforations and impending perforations in the caecum and the ascending and proximal transverse colon, with a relatively healthy intervening bowel.

throat and fever, as well as two days of abdominal pain. One day prior to the onset of abdominal pain, a general practitioner had prescribed her with oral cephalexin, paracetamol, orphenadrine and indomethacin. On admission to the hospital, the patient had consumed three doses of 50 mg indomethacin capsules. She had a history of thalassaemia minor, childhood asthma and eczema, and had undergone right hip surgery as an infant. She was febrile, tachycardiac and dehydrated, with generalised abdominal tenderness and guarding. While there was no leucocytosis ($8.84 \times 10^9/L$, 79% neutrophils), her blood urea nitrogen and serum creatinine were both elevated at 10.2 (normal range 1.4–7.7) mmol/L and 101 (normal range 50–90) $\mu\text{mol/L}$, respectively. A provisional diagnosis of suspected appendicitis or colitis was made. Computed tomography (CT) of the abdomen and pelvis showed a normal appendix, but revealed caecal and ascending bowel wall-thickening, consistent with colitis. The patient was initially managed conservatively and treated with intravenous ceftriaxone and metronidazole, but had persistent hypotension requiring multiple fluid boluses with worsening tachycardia and abdominal distension.

Initial diagnostic laparoscopy found gross peritoneal faecal soilage and extensive inflammatory adhesions, with free air and fluid present on entry into the peritoneum via open Hasson technique. On conversion

Department of Paediatric Surgery, KK Women's and Children's Hospital, 100 Bukit Timah Road, Singapore 229899

Loh AHP, MBBS, MRCSE, FAMS Associate Consultant

Ong LY, MBBS, MRCSE, FAMS Consultant

Narasimhan KL, MBBS, MCh, FRCSE Consultant

Jacobsen AS, MBBCh, LRCP & SI, FAMS Senior Consultant and Chairman, Division of Surgery

Rheumatology and Immunology Service

Liew WK, MBBS, MRCPCH Associate Consultant

Arkachaisri T, MD, FACR, DABP Senior Consultant and Head

Department of Pathology, National University Hospital, 5 Lower Kent Ridge Road, Singapore 119074

Lee VKM, MBBS, FRCPA Consultant

Correspondence to: Dr Amos Loh Hong Pheng
Tel: (65) 6394 1113
Fax: (65) 6291 0161
Email: amos.loh.hp@kkh.com.sg

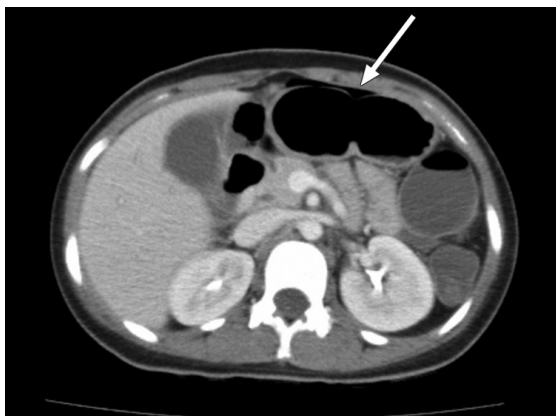


Fig. 2 CT image shows bowel wall-thickening, with a sliver of extraluminal air visible (arrow).

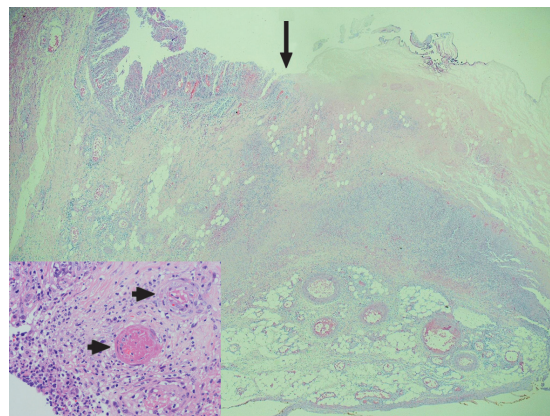


Fig. 3 Photomicrograph shows transverse ischaemic-type necrosis (arrow), with vascular thrombosis seen in the arterioles and venules adjacent to the site of perforation (arrowheads, inset) (Haematoxylin & eosin, $\times 20$, $\times 400$ [inset]).

to open laparotomy, multiple perforations and impending perforations were found in the caecum as well as in the ascending and proximal transverse colon (Fig. 1). A right hemicolectomy was performed, leaving an ileostomy and mucous fistula. Postoperatively, the patient remained intubated and required inotropic support for three days. Her recovery was complicated by wound dehiscence requiring secondary closure. On postoperative retrospective review, a small pocket of extraluminal air was recognised on her previous CT image (Fig. 2). Subsequent investigative work-up attempted to exclude infective, autoimmune and drug-related causes for this unexpected finding.

Histological examination found seven perforations and two impending perforations characterised by transmural necrosis and adjacent suppuration, resembling ischaemic-type changes and haemorrhagic colitis (Fig. 3). Scattered extramural and submucosal vessels showed intraluminal thrombi, suggesting the possible presence of vasculitis, although there was no evidence of inflammatory cells infiltrating the arterial wall. Serology for antinuclear antibody, anti-double-stranded DNA and antineutrophil cytoplasmic antibody was all negative. Magnetic resonance angiography did not demonstrate evidence of stenosis or microaneurysms of the mesenteric vessels. There was also no clinical evidence of systemic vasculitis or inflammatory bowel disease. Peritoneal fluid culture revealed moderate growth of *Campylobacter jejuni* and heavy growth of *Escherichia coli*. Appropriate broad-spectrum antibiotics were administered. Further specification of the latter was negative for *Clostridium difficile* toxins. Cultures for *Shigella spp.*, *Brucella spp.*, *Salmonella spp.* and acid-fast bacilli were negative. The colostomy was closed one month later, after the recovery of clinical and biochemical parameters. The patient recovered uneventfully, with no complaints at the 18-month follow-up.

DISCUSSION

Non-traumatic colonic perforation is uncommon in paediatric patients, and its diagnostic aetiology is often difficult to determine. Clinical signs can be nonspecific, with up to 50% of patients not presenting with any abdominal pain, thus resulting in significant delays in diagnosis. Fever, diarrhoea and abdominal distension may often be the only signs of frank pneumoperitoneum.⁽⁴⁾ In neonates, necrotising enterocolitis may arise due to the use of intravenous indomethacin for ductal closure. In children, colonic perforations are more often due to infective and inflammatory causes rather than drugs.^(4,5) In older patients, NSAID-related perforations occur three times more commonly in the large bowel than the small bowel,⁽³⁾ and these conditions have been described in nearly every drug of this class.⁽⁶⁾ Diagnosis has generally been based on the clinical details of the case, as histopathology has often found only nonspecific ulcerations.⁽⁷⁾ However, the punched-out ulcers in this patient clearly showed that the perforations occurred as a result of vascular compromise rather than by infective-suppurative processes. This is also the youngest known case of enteric NSAID-induced colonic perforation reported in the paediatric literature.

NSAID-induced intestinal mucosal damage is thought to arise from topical exposure or from systemic effects on intestinal permeability, inhibition of prostaglandin synthesis and inhibition of leucocyte migration and function.⁽⁸⁾ Local NSAID toxicity on distal bowel mucosa has been reported in preparations with sustained release or poor solubility; recurrent topical effects can occur with recirculated metabolites from NSAIDs with high enterohepatic excretion, particularly indomethacin, which is almost completely excreted in bile.⁽⁹⁾ Systemic effects are mediated via nitric oxide synthase induction, which results in increased vascular leakage and translocation

of enteropathic gut flora and harmful macromolecules, causing an immunologic response and local inflammation in the gut mucosa.⁽¹⁰⁾ Inhibition of cyclooxygenase (COX), particularly COX-2 expression, decreases endogenous prostaglandins, resulting in impaired mucosal cytoprotection and increased luminal neutrophil transit.⁽¹¹⁾ This diverts arachidonic acid metabolism to the lipoxygenase pathway, thus producing leukotrienes and cytotoxic oxyradicals.⁽¹²⁾

The mechanism of NSAID enteropathy is thought to be dose- and duration-dependent,⁽¹³⁾ with most cases presenting after long-term,^(2,6) rather than short-term oral intake.⁽¹⁴⁾ Histological, immunohistochemical and radionucleotide studies show proportionally increased intestinal permeability with prolonged NSAID use, with consistent inflammatory changes after 12 months of intake.^(10,11,15) However, the rapid clinical progression seen in cases like ours may support the hypothesis that other pathological processes may be responsible instead. These include bacterial-mediated pathophysiologic mechanisms, which may play a contributory role. Indomethacin, in particular, has been shown to produce intestinal lesions only in the presence of enteric flora. Through the hydrolysis of biliary NSAID acyl glucuronides by bacterial β -glucuronidase, toxic-free acids are liberated, which then irritate the downstream bowel.⁽¹⁶⁾ Inflammatory responses due to bacterial superantigens are believed to prime an excessive response to subsequent stimuli.⁽¹⁷⁾ Other possible contributing factors include drug synergism⁽¹⁸⁾ and bowel ischaemia,⁽¹⁹⁾ which is well studied, especially in the neonatal population. In our patient, her pre-existing haemoglobinopathy, antibiotic-induced intestinal microflora alteration, and the presence of enteropathogenic gut flora were factors that could have contributed to her precipitous clinical deterioration following consumption of a short course of indomethacin.

This case illustrates an unexpected but catastrophic complication following the administration of a common enteral drug. It reinforces the need for a thorough case history and a high index of clinical suspicion when approaching cases of paediatric acute abdomen. It also emphasises the importance of judicious prescription of NSAIDs in the paediatric age group.

ACKNOWLEDGEMENTS

The authors wish to thank Prof Wei-Sek Hwang from KK Women's and Children's Hospital Laboratory, for his assistance with the histopathological photomicrograph.

REFERENCES

- Holt S, Rigoglioso V, Sidhu M, et al. Nonsteroidal antiinflammatory drugs and lower gastrointestinal bleeding. *Dig Dis Sci* 1993; 38:1619-23.
- Byrne MF, McGuinness J, Smyth CM, et al. Nonsteroidal anti-inflammatory drug-induced diaphragms and ulceration in the colon. *Eur J Gastroenterol Hepatol* 2002; 14:1265-9.
- Langman MJ, Morgan L, Worrall A. Use of anti-inflammatory drugs by patients admitted with small or large bowel perforations and haemorrhage. *Br Med J (Clin Res Ed)* 1985; 290:347-9.
- Chang YJ, Yan DC, Kong MS, et al. Non-traumatic colon perforation in children: a 10-year review. *Pediatr Surg Int* 2006; 22:665-9.
- Kinnane J, Priebe C, Caty M, Kuppermann N. Perforation of the colon in an adolescent girl. *Pediatr Emerg Care* 1995; 11:230-2.
- Davies NM. Toxicity of nonsteroidal anti-inflammatory drugs in the large intestine. *Dis Colon Rectum* 1995; 38:1311-21.
- Ervens J, Schiffmann L, Berger G, Hoffmeister B. Colon perforation with acute peritonitis after taking clindamycin and diclofenac following wisdom tooth removal. *J Craniomaxillofac Surg* 2004; 32:330-4.
- Bjarnason I, Takeuchi K. Intestinal permeability in the pathogenesis of NSAID-induced enteropathy. *J Gastroenterol* 2009; 44 suppl 19:23-9.
- Risty GM, Najarian MM, Shapiro SB. Multiple indomethacin-induced jejunal ulcerations with perforation: a case report with histology. *Am Surg* 2007; 73:344-6.
- Bjarnason I, Smethurst P, Clark P, et al. Effect of prostaglandin on indomethacin-induced increased intestinal permeability in man. *Scand J Gastroenterol Suppl* 1989; 164:97-102.
- Bjarnason I, Hayllar J, MacPherson AJ, Russell AS. Side effects of nonsteroidal anti-inflammatory drugs on the small and large intestine in humans. *Gastroenterology* 1993; 104:1832-47.
- Hooker GD, Gregor JC, Ponich TP, McLarty TD. Diaphragm-like strictures of the right colon induced by indomethacin suppositories: evidence of a systemic effect. *Gastrointest Endosc* 1996; 44:199-202.
- Kessler WF, Shires GT 3rd, Fahey TJ 3rd. Surgical complications of nonsteroidal antiinflammatory drug-induced small bowel ulceration. *J Am Coll Surg* 1997; 185:250-4.
- Schiffmann L, Kahrau S, Berger G, Buhr HJ. Colon perforation in an adolescent after short-term diclofenac intake. *ANZ J Surg* 2005; 75:726-7.
- Anthony A, Dhillon AP, Nygard G, et al. Early histological features of small intestinal injury induced by indomethacin. *Aliment Pharmacol Ther* 1993; 7:29-39.
- Aabakken L, Osnes M. Non-steroidal anti-inflammatory drug-induced disease in the distal ileum and large bowel. *Scand J Gastroenterol Suppl* 1989; 163:48-55.
- Lu J, Wang A, Ansari S, Hershberg RM, Mckay DM. Colonic bacterial superantigens evoke an inflammatory response and exaggerate disease in mice recovering from colitis. *Gastroenterology* 2003; 125:1785-95.
- Gordon PV, Herman AC, Marcinkiewicz M, et al. A neonatal mouse model of intestinal perforation: investigating the harmful synergism between glucocorticoids and indomethacin. *J Pediatr Gastroenterol Nutr* 2007; 45:509-19.
- Grosfeld JL, Kamman K, Gross K, et al. Comparative effects of indomethacin, prostaglandin E1, and ibuprofen on bowel ischemia. *J Pediatr Surg* 1983; 18:738-42.