

Acute fibrinous and organising pneumonia presenting as complete lung consolidation

Mittal V, Kulshrestha R, Arya A, Bajaj P

ABSTRACT

Acute fibrinous and organising pneumonia (AFOP) is an unusual histopathological pattern of acute lung injury. The clinical manifestations, course and treatment of AFOP have yet to be characterised. All reported cases so far have described bilateral diffuse lung involvement radiologically. We report a case of an adolescent girl who presented with acute hypoxaemic respiratory failure with unilateral complete lung consolidation. She was initially diagnosed with severe community-acquired pneumonia. A computed tomography-guided percutaneous transthoracic trucut biopsy of the left lung revealed the classical histopathological pattern typically observed in AFOP. The patient responded well to treatment involving steroids. The uniqueness of such a presentation in AFOP prompted us to report this case.

Keywords: acute fibrinous and organising pneumonia, consolidation, pulmonary histopathology

Singapore Med J 2011;52(5):e88-e90

INTRODUCTION

Beasley et al first described acute fibrinous and organising pneumonia (AFOP) as an unusual histopathological pattern of acute lung injury.⁽¹⁾ The histopathological characteristics of AFOP include the presence of intra-alveolar fibrin in the form of fibrin 'balls' in patchy distributions, with mild-to-moderate lymphoplasmacytic infiltrate. AFOP has been reported sporadically and with varied associations. Currently, its clinical manifestations, course and treatment are not characterised. All reported cases so far have described bilateral diffuse lung involvement radiologically. We report a case of an adolescent girl with unilateral complete lung consolidation, in which a lung biopsy revealed the classical histopathological pattern seen in AFOP. The patient responded well to steroids. Our case reflects a unique clinical presentation not previously described in AFOP.

CASE REPORT

A previously healthy 14-year-old girl presented with an acute onset of high fever, dry cough, breathlessness and pleuritic chest pain for one week. On examination, she was noted to be in severe respiratory distress. Her chest examination was suggestive of a large, left-sided pleural effusion with contralateral mediastinal shift. Other systemic examinations were normal. A provisional diagnosis of community-acquired pneumonia with left pleural effusion and respiratory failure was made.

The patient had a low haemoglobin level (7.4 gm%) and an elevated erythrocyte sedimentation rate (120 mm in the first hour) and C-reactive protein quantitative level (267 mg/L). Her total leucocyte count (TLC) and all other lab results were within normal limits. Arterial blood gas analysis revealed uncompensated metabolic acidosis with severe hypoxaemia. Chest roentgenogram showed a left opaque hemithorax with contralateral mediastinal shift and right-sided basal infiltrates (Fig. 1a). Contrast-enhanced computed tomography (CT) of the thorax showed complete consolidation of the left lung with a large, left-sided pleural effusion, as well as bronchopneumonia on the right side (Fig. 1b). A left intercostal tube thoracostomy was performed, which drained 1.4 L of straw-coloured pleural fluid. Fluid analysis revealed low cellularity, lymphocyte predominance, no malignant cells and an elevated adenosine deaminase level (94 U/L). Blood and pleural fluid cultures for aerobes were sterile. Mantoux test with 0.1 mL (5 TU) purified protein derivative read 4 mm × 3 mm after 48 hours. The patient was started on antibiotics (co-amoxiclav and levofloxacin) in addition to other supportive treatments. Anti-tubercular treatment (ATT) was added empirically. Despite the treatment, the patient's condition did not improve.

The patient's worsening clinical condition, persistent severe hypoxaemia, poor response to treatment, normal serial TLC as well as our inability to identify the infective pathology resulted in a diagnostic dilemma. Fibre-optic bronchoscopy (FOB) could not be performed due to persistent hypoxaemia. Finally, CT-guided percutaneous transthoracic biopsy of the left consolidated lung was

Department
of Respiratory
Medicine,
Sri Balaji Action
Medical Institute,
Delhi 110063,
India

Mittal V, MD
Senior Resident

Arya A, MD
Senior Consultant
and Head

Department of
Pathology

Bajaj P, MD
Senior Consultant
and Head

Department of
Pathology,
Vallabhnbhai Patel
Chest Institute,
University of Delhi,
Delhi 110007,
India

Kulshrestha R, DNB,
Assistant Professor

Correspondence to:
Dr Vikas Mittal
Tel: (91) 93 1250 8413
Fax: (91) 11 2527 0725
Email: waytovikas@
yahoo.co.in

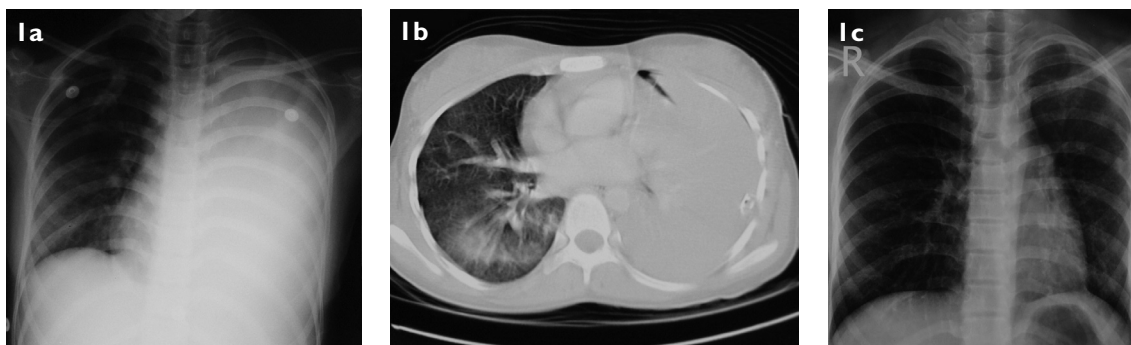


Fig. 1 (a) Chest roentgenogram shows left opaque hemithorax with contralateral mediastinal shift. (b) Contrast-enhanced CT of the thorax (lung window) shows complete consolidation of the left lung, with the left intercostal tube *in situ* and right basal infiltrates. (c) Chest roentgenogram one month after steroid treatment shows near complete resolution.

performed. Histopathology revealed mild chronic lymphocytic interstitial infiltrates and fibrinous exudate occupying all the alveolar spaces. The alveoli were lined by plump vacuolated pneumocytes. No granuloma was seen (Fig. 2). Periodic acid-Schiff, acid-fast bacilli (AFB) and Gram stains were all negative. The biopsy was reviewed independently by two pathologists, and a diagnosis of AFOP was made.

Subsequently, 40 mg of prednisolone was added to the patient's treatment regimen. After a week, we were able to perform FOB. Bronchioalveolar lavage (BAL) cytology was normal, and Gram and AFB stains were negative. The patient's clinical condition continued to improve after the first week. Following treatment with oral steroids, she was discharged in a stable condition about two weeks after the onset of illness. Empirical ATT was stopped at the time of discharge, as polymerase chain reaction for detection of *Mycobacterium tuberculosis* (MTB) was negative, and rapid culture for MTB in pleural fluid and BAL had not shown any growth up to the 6th week. Aerobic cultures of BAL and lung biopsy were sterile. The patient was symptom-free at follow-up after one month. Her chest roentgenogram showed remarkable improvement (Fig. 1c), and spirometry was also within normal limits.

DISCUSSION

The term AFOP was proposed by Beasley et al⁽¹⁾ to describe cases of acute lung injury that do not fit into the histopathological criteria of recognised entities, such as diffused alveolar damage, bronchiolitis obliterans organising pneumonia and eosinophilic pneumonia, which were described in cases with acute or subacute presentations. AFOP is characterised by intra-alveolar fibrin in the form of fibrin 'balls' in patchy distributions, with mild-to-moderate lymphoplasmacytic infiltrates. It has been associated with infections,⁽¹⁾ collagen vascular

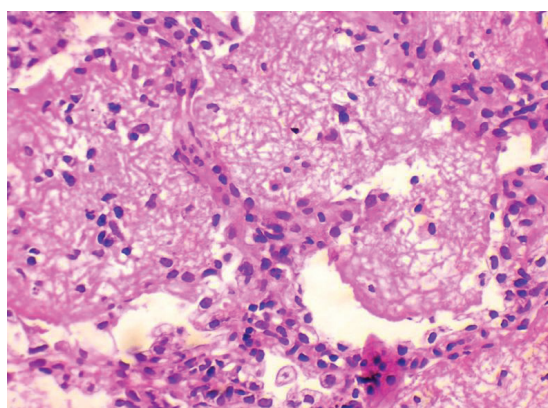


Fig. 2 Photomicrograph of left lung tissue shows intra-alveolar fibrin and mild chronic interstitial infiltrate (Haematoxylin & eosin, $\times 400$).

diseases,⁽¹⁻³⁾ environmental exposures to diverse agents and drugs (amiodarone,⁽¹⁾ busulfan,⁽¹⁾ abacavir,⁽⁴⁾ and decitabine⁽⁵⁾) and acute respiratory distress syndrome.⁽⁶⁻⁸⁾ In many cases, no confirmed causes or associations were successfully identified. Likewise, we were unable to identify the aetiological causes of AFOP in our case.

The clinical manifestations, course and treatment of AFOP are not well characterised. Our patient was an adolescent girl, younger than described in previous reports, who presented with acute onset febrile illness with hypoxaemic respiratory failure. She followed a subacute clinical course and showed remarkable improvement following the addition of steroids (1 mg/kg prednisolone) to her antibiotic treatment. She recovered completely; clinical, radiologic and spirometry examinations showed no impairment of her lung function. Steroids were gradually stopped in tapering doses within one month.

To date, all reported cases of AFOP have shown diffuse lung involvement, with clinical presentations that are similar to acute and subacute diffuse parenchymal lung diseases (DPLD). To our knowledge, this is the first report of an AFOP pattern in a case with predominant

unilateral lung involvement and total consolidation. AFOP has been proposed as a possible autonomic interstitial lung disease, although it is not included in the ATS/ERS classification of idiopathic interstitial pneumonias.⁽⁹⁾ AFOP pattern presenting as unilateral complete lung consolidation, as in our case, precludes it to be classified as a DPLD. The variability in clinical presentations, course, treatment and prognosis of AFOP as well as its diverse associations raise questions about the exact nature and pathogenesis of this pattern. It appears that AFOP is an acute reaction of the lung to an insult which may yet remain unidentified.

In conclusion, AFOP is a relatively new and underreported histopathology that can present with predominant unilateral lung involvement as complete lung consolidation, which in turn poses a huge diagnostic challenge to clinicians. It responds well to additional steroid treatments. Complete clinical and radiological resolution can be expected, with no impairment of lung function. Further studies are needed to better classify AFOP and characterise its clinical presentations, course and treatment. Whether AFOP can be classified as another acute DPLD is still a contentious issue.

REFERENCES

1. Beasley MB, Franks TJ, Galvin JR, Gochuico B, Travis WD. Acute fibrinous and organizing pneumonia: a histological pattern of lung injury and possible variant of diffuse alveolar damage. *Arch Pathol Lab Med* 2002; 126:1064-70.
2. Prahalad S, Bohnsack JF, Maloney CG, Leslie KO. Fatal acute fibrinous and organizing pneumonia in a child with juvenile dermatomyositis. *J Pediatr* 2005; 146:289-92.
3. Balduin R, Giacometti C, Saccharola L, et al. Acute fibrinous and organizing pneumonia in a patient with collagen vascular disease "stigma". *Sarcoidosis Vasc Diffuse Lung Dis* 2007; 24:78-80.
4. Yokogawa N, Alcid DV. Acute fibrinous and organizing pneumonia as a rare presentation of abacavir hypersensitivity reaction. *AIDS*. 2007; 21:2116-7.
5. Vasu TS, Cavallazzi R, Hirani A, Marik PE. A 64-year-old male with fever and persistent lung infiltrate. *Respir Care* 2009; 54:1263-5.
6. Hwang DM, Chamberlain DW, Poutanen SM, et al. Pulmonary pathology of severe acute respiratory syndrome in Toronto. *Mod Pathol* 2005; 18:1-10.
7. Cincotta DR, Sebire NJ, Lim E, Peters MJ. Fatal acute fibrinous and organizing pneumonia in an infant: The histopathologic variability of acute respiratory distress syndrome. *Pediatr Crit Care Med* 2007; 8:378-82.
8. Bhatti S, Hakeem A, Torrealba J, McMahon JP, Meyer KC. Severe acute fibrinous and organizing pneumonia (AFOP) causing ventilatory failure: successful treatment with mycophenolate mofetil and corticosteroids. *Respir Med* 2009; 103:1764-7.
9. Cordeiro CR. Airway involvement in interstitial lung disease. *Curr Opin Pulm Med* 2006; 12:337-41.