

# Tracheobronchial injuries following endotracheal intubation

Gibbaoui H, Abu-Zidan F M, Yaman M

## ABSTRACT

**We report two rare cases of tracheobronchial injury (TBI) following endotracheal intubation. Both intubations were easy and performed by experienced anaesthetists. The injuries for both cases were possibly caused by the tip of an endotracheal tube. A 27-year-old woman regurgitated copiously during induction of general anaesthesia for a Caesarean section. She had a full-thickness TBI 2 cm above the carina, which was repaired through an open thoracotomy. A 68-year-old woman undergoing left mastectomy was intubated with a 7.5-mm endotracheal tube for general anaesthesia. 24 hours after extubation, the patient developed widespread subcutaneous emphysema. There was no associated respiratory distress, and the patient was treated conservatively. The fragile tracheal tissue associated with pregnancy and old age was possibly a contributing factor for injury. Both patients recovered well. Surgical and non-surgical methods can be safely used after careful consideration of the patient's clinical, radiological and endoscopic findings.**

**Keywords:** complications, injuries, intratracheal, intubation, trachea

*Singapore Med J 2011;52(5):e96-e99*

## INTRODUCTION

Tracheobronchial injury (TBI) following endotracheal intubation is a rare, life-threatening complication.<sup>(1,2)</sup> Early recognition and adequate management are crucial for a positive outcome. Surgical repair of such injury was previously the standard of care, but a conservative approach has recently been advocated.<sup>(1)</sup> We present two cases of TBI following endotracheal intubation; one was treated surgically and the other, conservatively. Both patients recovered well.

## CASE REPORTS

### Case 1

A 27-year-old full-term pregnant woman required urgent Caesarean section for breech presentation.

The patient was 147 cm tall and weighed 78.5 kg. Rapid sequence induction, including cricoid pressure, was used. Thiopentone 375 mg and suxamethonium chloride 100 mg were administered intravenously. During induction, the patient regurgitated copiously. An experienced anaesthetist immediately inserted an oral 7.5-mm endotracheal tube with a low-pressure, high-volume cuff. Intubation was easy (Cormack and Lehane Grade 1), and cisatracurium 6 mg was given intravenously after the intubation. Chest auscultation revealed a silent chest, and the patient desaturated to SpO<sub>2</sub> of 88%. The tube was immediately removed and reintubation attempted. On the second attempt, air entry was heard in both lungs, and oxygen saturation improved to 99%. Despite that, high airway pressure was noted (40 cm H<sub>2</sub>O). The operation was successfully completed and the baby was delivered through a lower Caesarean section. Chest radiograph performed before extubation was read as normal (Fig. 1), and thus, the patient was extubated. However, immediately after extubation, she desaturated again and developed severe subcutaneous emphysema. The patient was reintubated without using a stylet. Bilateral chest tubes were inserted, as repeat chest radiograph revealed pneumomediastinum and massive subcutaneous emphysema (Fig. 2). Fiberoptic bronchoscopy showed a full-thickness tracheobronchial injury at the membranous portion of the trachea, 2 cm above the carina and extending to the origin of the right main bronchus. Flexible oesophagoscopy was normal. Surgical repair using interrupted sutures through right posterolateral thoracotomy was performed 12 hours after the injury. The tracheal injury was not severely ragged, suggesting that it was caused by the tip of the endotracheal tube. The patient was discharged in good condition seven days after surgery. Bronchoscopy performed two months later showed complete healing of the injury site without tracheal stenosis.

### Case 2

A 68-year-old diabetic hypertensive woman had left mastectomy and axillary clearance for left breast cancer. The patient was 161 cm tall and weighed 78 kg. Preoperative chest radiograph was normal. Propofol 150 mg, cisatracurium 12 mg and fentanyl 100 µg were

Thoracic Surgery Unit,  
Tawam Hospital,  
Al-Ain,  
PO Box 15258,  
United Arab Emirates

Gibbaoui H, MD  
Acting Consultant

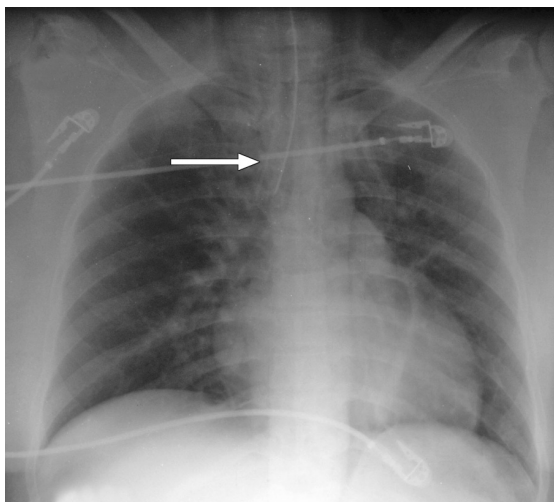
Department of  
Surgery

Yaman M, MD,  
FRCS, FACS  
Medical Director,  
Senior Consultant  
and Chairman

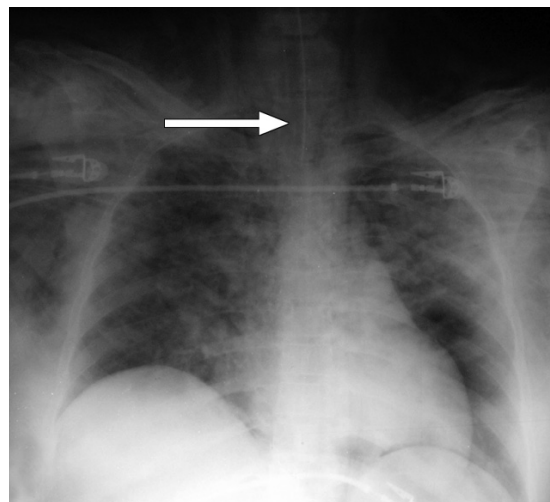
Department of  
Surgery,  
Faculty of Medicine  
and Health Sciences,  
UAE University,  
Al-Ain,  
PO Box 17666,  
United Arab Emirates

Abu-Zidan FM, MD,  
FRCS, PhD  
Professor

Correspondence to:  
Prof Fikri Abu-Zidan  
Tel: (971) 3 713 7579  
Fax: (971) 3 767 2067  
Email: fabuzidan@  
uaeu.ac.ae



**Fig. 1** Portable supine anteroposterior chest radiograph taken before extubation of the patient was read as normal. Retrospectively, there was mild surgical emphysema, which was missed earlier. Note the orientation of the distal portion of the endotracheal tube to the right side (arrow), indicating that the tube was pushed more to the right side.



**Fig. 2** Portable supine anteroposterior chest radiograph after reintubation shows pneumomediastinum with massive subcutaneous emphysema. Note the position of the endotracheal tube, which is more proximal (arrow).

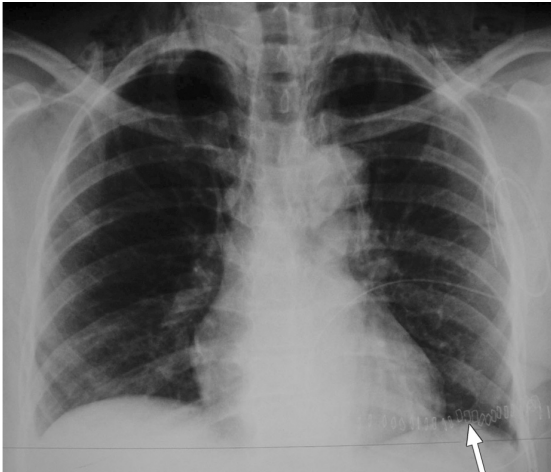
administered intravenously during induction. The patient was intubated orally with a 7.5-mm low-pressure, high-volume cuffed endotracheal tube for general anaesthesia by an experienced anaesthetist. The intubation was easy (Cormack and Lehane Grade 1) and no stylet was used for it. The cuff of the tube was inflated with air using a syringe, and pressure was adjusted clinically. The airway pressure was normal throughout the whole operation (20–23 cm H<sub>2</sub>O). 24 hours after extubation, the patient developed widespread subcutaneous emphysema. There was no associated respiratory distress or difficulty in swallowing. SpO<sub>2</sub> was 97% on room air. Chest radiograph showed diffuse subcutaneous emphysema without pneumothorax (Fig. 3). Computed tomography (CT) imaging of the chest revealed a small complete longitudinal tear at the posterolateral side, at the junction between the middle two-thirds and lower one-third of the trachea at its membranous portion, in addition to the subcutaneous emphysema (Fig. 4). The patient was treated conservatively; she was started on oral antibiotics (ciprofloxacin) and kept under close observation. The subcutaneous emphysema resolved gradually, and she was discharged seven days after surgery.

## DISCUSSION

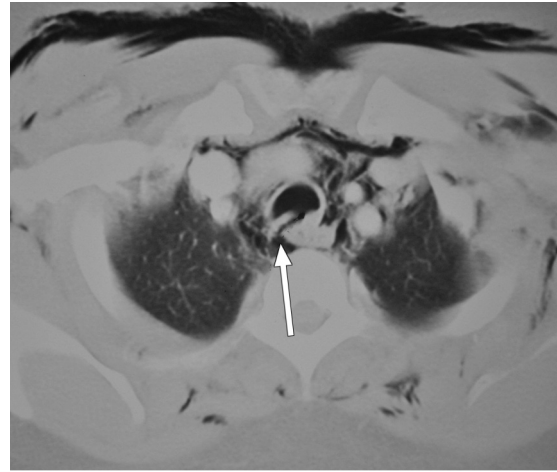TBI is defined as an injury to the trachea or bronchi localised between the level of the cricoid cartilage and the division of the lobar bronchi into their segmental branches. The majority of injuries occur longitudinally along the membranous portion of the trachea, and are located at the level of the carina.<sup>(2)</sup>

TBI following endotracheal intubation can be attributed to the operator, the equipment used or the patient. Factors related to the operator include inexperience and rough or repeated intubation. Those related to the equipment include over-inflation of the cuff, tube malposition, improper tube size and stylet use. Those related to the patient include sudden movement, excessive vomiting or coughing, old age and chronic diseases associated with fragile tissues.<sup>(1,3-5)</sup> Women are more commonly affected, as they are prone to having weakness of the membranous portion of the trachea, making it more fragile and susceptible to injury. Their smaller body size also increases the risk of placing the tube too far down in a short trachea.<sup>(3)</sup>

Our first patient, whose height was 147 cm, was relatively short compared to an adult woman with an average height of 160 cm.<sup>(6)</sup> Fig. 1 shows that the tube had been pushed more to the right side. In order to reduce endobronchial placement of the tube, the tip of the endotracheal tube should be secured 21 cm from the upper incisor teeth in average-sized women.<sup>(6)</sup> The design of modern endotracheal tubes usually includes marking above the cuff to indicate when to stop insertion of the tube, which helps to prevent pushing the tube too deep. The marking on the teeth is useful for subsequent checks to determine if the tube has been placed too deep. The operative finding that the tracheal wound was not severely ragged suggested that the injury was caused by the tip of the endotracheal tube in this patient. Studies have shown that the sudden increase of tracheal pressure by severe coughing or vomiting may cause a tracheal rupture.<sup>(7,8)</sup>



**Fig. 3** Chest radiograph 24 hours after extubation shows diffuse subcutaneous emphysema of the neck without pneumothorax. Note the drain at the left mastectomy site (arrow).



**Fig. 4** Chest CT image with intravenous contrast shows a tear (arrow) at the membranous portion of the trachea with subcutaneous emphysema.

In this case, this may have been another contributing factor for the injury. Application of cricoid pressure at the moment of vomiting or copious regurgitation may cause injuries to the trachea.

It is also important to stress that a significant number of tracheal injuries may occur without apparent difficulty in routine intubations, just as in the case of our second patient.<sup>(2,4,9)</sup> It was difficult to determine the exact cause of injury in this case. Judging from the site of injury, the injury may have been caused by the tip of the tube due to rough handling, or by the quick inflation of the cuff so that it exceeded the maximum diameter of the airway.<sup>(10,11)</sup> The tracheal wound was sharp, as shown in the CT image (Fig. 4), thus supporting the first assumption. Furthermore, both pregnancy and old age are contributing factors, as they cause tissues to be more fragile and more susceptible to injury. Clinical signs usually develop immediately or shortly after extubation, but they may not appear for up to five days. Respiratory distress and subcutaneous emphysema are the most common symptoms in TBI. Haemoptysis, pneumomediastinum and pneumothorax may be present if the TBI communicates freely with the pleural space. Stridor may occur if the larynx or upper trachea is involved. If the diagnosis is delayed, retrosternal pain, fever and leucocytosis may develop due to mediastinitis.<sup>(2,12)</sup>

Conventional chest radiography and fiberoptic bronchoscopy are the preferred diagnostic tools. Early radiological signs include orientation of the distal portion of the endotracheal tube to the right (this was clearly seen in our first case), overdistracted endotracheal balloon cuff, migration of the balloon toward the endotracheal tube tip and pneumomediastinum/

subcutaneous emphysema.<sup>(13)</sup> Fiberoptic bronchoscopy is useful to confirm the diagnosis and to determine the exact location and extent of the injury.<sup>(10)</sup> CT imaging of the chest is advised when mediastinal bleeding or emphysema is suspected, and/or if bronchoscopy carries a high risk in intubated patients who require a high concentration of oxygen support. In this case, CT imaging will be an alternative and safe modality with an accurate diagnosis.<sup>(3,10)</sup>

The management of TBI following endotracheal intubation is controversial. Surgical repair was the only option in the past, but conservative management has recently been advocated, with good clinical outcome in selected cases. The principles of treatment include secure airway distal to injury, low airway pressure, adequate ventilation and prevention/treatment of mediastinitis. Conservative non-operative treatment is reserved for patients with stable vital signs, stable airway with no compromise and lacerations < 2 cm affecting partial thickness of the tracheobronchial wall. This non-operative approach includes adequate antibiotics, chest tube drainage where necessary and reduction of airway pressure in intubated patients with the cuff inflated distal to the tear.<sup>(12,14)</sup> Indications for operative repair include difficulty in ventilating the patient with respiratory distress in the absence of pneumothorax or full-thickness injury and in lacerations > 2 cm. In addition, progressive pneumomediastinum, increasing subcutaneous emphysema, evidence of oesophageal injury or mediastinitis are indications for immediate surgery. The indications for surgical repair are based on the overall clinical, radiological and bronchoscopic findings.<sup>(1,5)</sup> The stated purpose of surgical repair of TBI is to close

the defect so as to have effective ventilation, to prevent mediastinitis secondary to contamination and to prevent long term airway stenosis, especially in cases of lengthy or full-thickness injuries.<sup>(15)</sup> Leinung et al<sup>(16)</sup> classified TBI into three types: type I involves isolated tracheal lesions; type II involves the carina or main stem bronchi; and type III involves distal lesions of lobar or segmental bronchi. The prognosis of TBI following endotracheal intubation depends on the general condition of the patient and the rapidity of diagnosis and management.

In summary, decisions in managing TBI following endotracheal intubation should be based on clinical, radiological and endoscopic findings. Both surgical and non-surgical options can be safely used after careful consideration of the findings. Prevention of these injuries can be achieved by careful selection of appropriately sized endotracheal tubes, avoidance of over-inflation of the cuff and repeated attempts at intubation, as well as skilled, gentle intubation without force, especially in women with conditions associated with fragile tissues like pregnancy and old age.

## REFERENCES

1. Carbognani P, Bobbio A, Cattelani L, et al. Management of postintubation membranous tracheal rupture. *Ann Thorac Surg* 2004; 77:406-9.
2. Stannard K, Wells J, Cokis C. Tracheal rupture following endotracheal intubation. *Anaesth Intensive Care* 2003; 31:588-91.
3. Hofmann HS, Rettig G, Radke J, Neef H, Silber RE. Iatrogenic ruptures of the tracheobronchial tree. *Eur J Cardiothorac Surg* 2002; 21:649-52.
4. Chen EH, Logman ZM, Glass PS, Bilfinger TV. A case of tracheal injury after emergent endotracheal intubation: a review of the literature and causalities. *Anesth Analg* 2001; 93:1270-1.
5. Liu H, Jahr JS, Sullivan E, Waters PF. Tracheobronchial rupture after double-lumen endotracheal intubation. *J Cardiothorac Vasc Anesth* 2004; 18:228-33.
6. Owen RL, Cheney FW. Endobronchial intubation: a preventable complication. *Anesthesiology* 1987; 67:255-7.
7. Roh JL, Lee JH. Spontaneous tracheal rupture after severe coughing in a 7-year-old boy. *Pediatrics* 2006; 118:e224-7.
8. Stevens MS, Mullis TC, Carron JD. Spontaneous tracheal rupture caused by vomiting. *Am J Otolaryngol* 2010; 31:276-8.
9. Mussi A, Ambrogi MC, Menconi G, Ribechini A, Angeletti CA. Surgical approaches to membranous tracheal wall lacerations. *J Thorac Cardiovasc Surg* 2000; 120:115-8.
10. Fan CM, Ko PC, Tsai KC, et al. Tracheal rupture complicating emergent endotracheal intubation. *Am J Emerg Med* 2004; 22:289-93.
11. Kaloud H, Smolle-Juettner FM, Prause G, List WF. Iatrogenic ruptures of the tracheobronchial tree. *Chest* 1997; 112:774-8.
12. Gabor S, Renner H, Pinter H, et al. Indications for surgery in tracheobronchial ruptures. *Eur J Cardiothorac Surg* 2001; 20:399-404.
13. Rollins RJ, Tocino I. Early radiographic signs of tracheal rupture. *AJR Am J Roentgenol* 1987; 148:695-8.
14. Ross HM, Grant FJ, Wilson RS, Burt ME. Nonoperative management of tracheal laceration during endotracheal intubation. *Ann Thorac Surg* 1997; 63:240-2.
15. Conti M, Pougeoise M, Wurtz A, et al. Management of postintubation tracheobronchial ruptures. *Chest* 2006; 130:412-8.
16. Leinung S, Ott R, Schuster E, Eichfeld U. [Tracheobronchial ruptures: classification and management]. *Chirurg* 2005; 76:783-8. German.