

Foetal sacrococcygeal teratoma: extremes in clinical presentation

Wee W W, Tagore S, Tan J V K, Yeo G S H

ABSTRACT

Sacrococcygeal teratoma (SCT) is a congenital tumour that can be diagnosed by ultrasonography (USG). We present our experience with the management of two cases of SCT in our institution between 2008 and 2009. In the first case, SCT was diagnosed at 17 weeks' gestation. The patient was followed up with fortnightly USG to monitor the tumour size, foetal growth and signs of foetal hydrops. The patient delivered a baby girl by Caesarean section at 37 weeks, with good Apgar scores. The neonate underwent an uneventful resection of SCT on Day 1 of life. In the second case, SCT was diagnosed at 20 weeks during screening. In view of foetal hydrops and anaemia, the patient underwent three *in utero* foetal blood transfusions. A baby boy was delivered by Caesarean section at 28 weeks. There was a large friable SCT with massive haemorrhage. Despite maximal resuscitative efforts, the neonate died 30 minutes after birth.

Keywords: foetal hydrops, *in utero* foetal blood transfusion, prenatal diagnosis, sacrococcygeal teratoma, ultrasonography

Singapore Med J 2011;52(6):e118-e123

INTRODUCTION

The exact embryologic origin of germinal neoplasms is unclear. It has been suggested that benign neoplasms result from the disruption of blastogenesis that would otherwise result in conjoined twins. More commonly, it has been proposed that germinal cell neoplasms originate from remnants of the primitive streak, a collection of extragonadal germ cells found in the midline of the dorsal aspect of the embryonic disc, known as Hensen's node.⁽¹⁾ During the fourth week of embryologic development, the primitive streak results in the formation of mesenchyme, the supportive tissues of the embryo.⁽²⁾ The mesenchyme consists of three cell lines: endoderm, ectoderm and mesoderm, and cells from each of these lines are found in teratomas. With the progression of foetal development, Hensen's node

gradually migrates in a caudal direction toward the tip of the coccyx, and the primitive streak degenerates.⁽³⁾

Sacrococcygeal teratomas (SCTs) are the most common germinal cell neoplasms found in the foetus. They originate during embryonic development when the primitive streak fails to differentiate among mesodermal, ectodermal and endodermal tissues in the embryonic disc. SCTs comprise both solid and cystic elements, with > 50% containing calcification and ossification. Common tissue elements include neurologic tissue, skin, muscle, bone, cartilage, respiratory or gut epithelium.⁽⁴⁾ Ultrasonography (US) determines whether SCTs are cystic, solid or mixed in nature. Characteristics of the neoplasm include internal calcifications, haemorrhage, necrosis of the tumour and degeneration of the cystic neoplasm.⁽⁵⁾ The effects of the mass, with or without polyhydramnios, may lead to dystocia and preterm labour. The highly vascular tumour may result in high-output cardiac failure and eventually foetal hydrops. Other complications associated with SCTs include foetal hydronephrosis, placentomegaly, tumour rupture, bleeding and death.

The precise aetiology of SCTs is not known, but there is a definite female predominance. Genetics may play a role in the development of SCTs. An incidence of SCT associated with the deletion of chromosome 7q and partial trisomy of chromosome 2p was found in one cytogenetic case report.⁽⁶⁾ The birth prevalence is approximately one per 27,000 live births.⁽⁷⁾ The two cases presented here illustrate the importance of prenatal diagnosis, management and clinical intervention. Early prenatal diagnosis influences clinical decision and antenatal management, which in turn optimises the outcome.

CASE REPORT

Case 1

A 37-year-old Chinese woman with a history of polycystic ovarian syndrome conceived on clomiphene citrate. She was booked at 12 weeks of gestation at KK Women's and Children's Hospital, Singapore. Her previous history included a vaginal delivery in 1999, followed by a lower-segment Caesarean section for twins in 2004.

Department of
Obstetrics and
Gynaecology,
KK Women's and
Children's Hospital,
100 Bukit Timah
Road,
Singapore 229899

Wee WW, MBBS,
MMed, MRCOG
Medical Officer

Tagore S, MBBS,
MRCOG
Associate Consultant

Tan JVK, MBBS,
MRCOG
Consultant

Yeo GSH, MBBS,
FRCOG, FAMS
Senior Consultant

Correspondence to:
Dr Wee Wei-Wei
Tel: (65) 6394 1001
Fax: (65) 6298 6343
Email: wcube@
hotmail.com

Table I. Tabulation of the growth scan details with increasing gestation for Case I.

Date	Gestation (wks + days)	SDS of AC	AC (mm)	Teratoma size (cm)	MCA PSV (cm/s)	AFI (cm)
1/8/2008	17 + 6	-	-	3.3 × 3.2	28.49	-
19/8/2008	20 + 3	1.25	163	4.4 × 4.1 × 3.9	28.44	-
2/9/2008	22 + 0	-	-	5.2 × 4.9 × 4.6	30.90	10.9
18/9/2008	24 + 5	-	-	7.1 × 6.5 × 5.6	39.64	12.9
2/10/2008	26 + 3	2.77	247	8.1 × 7.8 × 9.1	39.52	16.2
14/10/2008	28.4 + 0	-	-	9.5 × 8.3 × 8.7	-	15.2
28/10/2008	30.4 + 0	1.64	273	10.5 × 10.3 × 10.2	51.00	16.6
3/11/2008	31.3 + 0	3.07	297	-	-	20.5
13/11/2008	32.7 + 0	1.11	289	12.4 × 11.6 × 10.5	57.68	24.5
25/11/2008	34.4 + 0	4.17	339	14.0 × 12.1 × 9.8	58.60	22.8
2/12/2008	35.4 + 0	4.31	350	14.4 × 13.9 × 10.6	64.42	20.6

Data is missing in some cases, as measurements were not taken.

SDS: Standard deviation score; AC: abdominal circumference; MCA PSV: middle cerebral artery peak systolic velocity; AFI: amniotic fluid index.

The first trimester screening revealed a high risk for trisomy 21. Amniocentesis performed showed no karyotypic abnormalities. US performed at 17 weeks showed an SCT measuring 33 mm × 32 mm × 28 mm, with a normal middle cerebral artery peak velocity (MCA PSV). Another US at 20 weeks revealed a coccygeal teratoma slightly bigger in size as compared to the previous imaging (44 mm × 41 mm × 39 mm). The patient was referred to the paediatric surgeon and counselled regarding postnatal prognosis and surgical management.

The patient was subsequently followed up at the Foetal Medicine Clinic with fortnightly US for foetal growth and monitoring (Table I). There was no obvious pericardial effusion, hydrops or ascites. MCA PSV was normal. US at 35 weeks' gestation revealed an amniotic fluid index (AFI) of 20.6 cm, an SCT measuring 14.4 cm × 13.9 cm × 10.6 cm, normal MCA PSV with no obvious hydrops (Figs. 1 & 2). A decision was made for elective Caesarean section at 37–38 weeks of gestation. A baby girl with a birth weight of 4.47 kg was delivered by an uncomplicated elective lower segment Caesarean section at 37 weeks and 3 days, with an Apgar score of 9 at both one and five minutes (Figs. 3 & 4). The cord arterial pH stood at 7.292, with a base excess of -3.1 mmol/L.

Computed tomography (CT) imaging of the neonate's abdomen and pelvis was performed on Day 1 of birth, which revealed a large SCT with intra-abdominal extension, possibly up to the inferior aspect of the superior mesenteric vessels. This mass was in continuity with the soft tissue in the pelvis and lower abdomen, thus displacing the urinary bladder and uterus anterosuperiorly, and was bordered superiorly by the superior mesenteric vessels. There was no obvious extension of this mass into the spinal canal. A vascular stalk was seen extending inferiorly down the left anterior

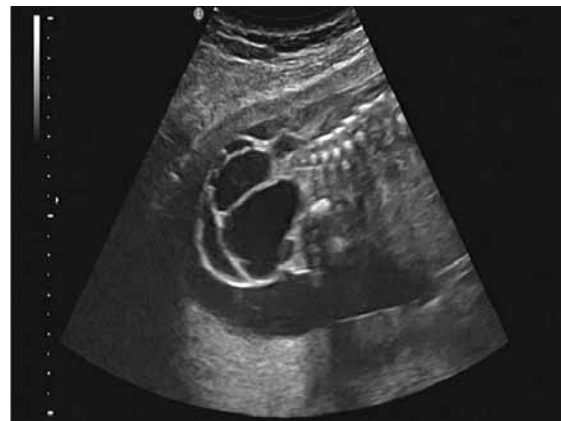

Fig. 1 Case I. Trans-abdominal US image shows a lobulated swelling, predominantly cystic, at the sacrococcygeal region at 20 weeks' gestation.

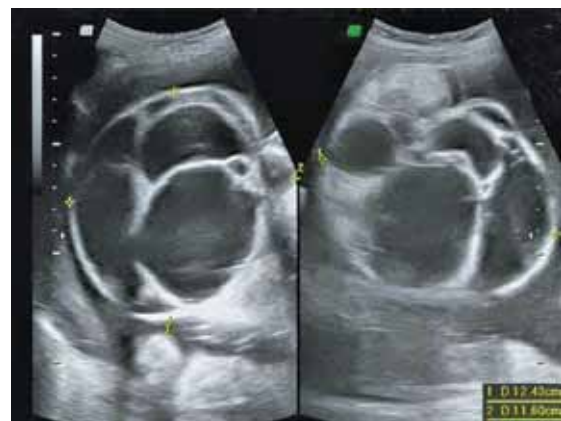

Fig. 2 Case I. Trans-abdominal US image of the SCT measuring 12.4 cm × 11.6 cm × 10.5 cm at 33 weeks of gestation. The SCT had a final recorded dimension of 14.3 cm × 13.9 cm × 10.6 cm on imaging at 35 weeks of gestation.

aspect of the sacrum into the exophytic component of the mass.

The neonate underwent an uneventful resection of the SCT on the same day. Intraoperative findings

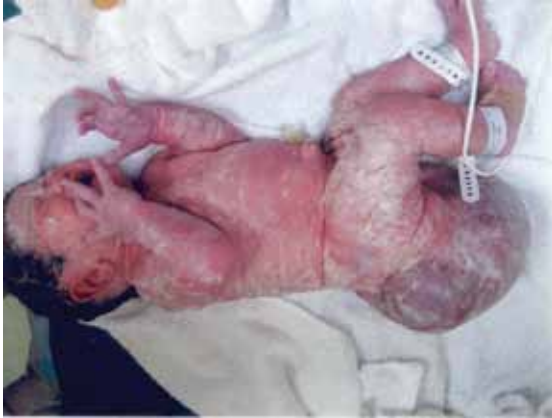

Fig. 3 Case 1. Photograph shows a 4.47-kg baby girl with SCT delivered by Caesarean section.

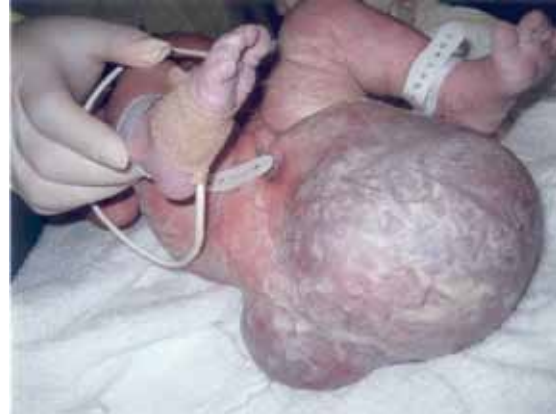

Fig. 4 Case 1. Photograph shows a huge, lobulated swelling that is predominantly cystic, with some solid component seen at the sacrococcygeal region. The anal opening is pushed anteriorly.

showed a large SCT measuring 15.0 cm × 12.0 cm × 5.0 cm that was mainly cystic with some solid component. The tumour was attached to the lower end of the coccyx superiorly and the rectum anteriorly. There was no intra-abdominal extension. Histology showed features of benign mature cystic teratoma. Postoperatively, the neonate recovered well, and was discharged on Day 13 of life. Upon follow-up at two weeks post surgery, the neonate was well and the wound had healed. She was on regular follow-up with the neonatologist.

Case 2

A 38-year-old Chinese woman with no notable past medical history conceived with *in vitro* fertilisation (IVF), and was booked at eight weeks of gestation. Her history included a previous vaginal delivery in 2005, conceived through IVF. First trimester screening revealed a high risk for trisomy 21 due to thickened nuchal translucency. Amniocentesis showed normal karyotype. Cardiac imaging performed at 16 weeks' gestation was normal. US performed at 20 weeks' gestation showed a sacrococcygeal mass of 51 mm × 48 mm × 47 mm, with a normal MCA PSV of 28.59 cm/s (1.0–1.29 Multiples of Median [MoM]; Fig. 5). We therefore suspected the presence of an SCT or meningocele. Magnetic resonance (MR) imaging of the foetus was performed at 22 weeks' gestation to confirm the diagnosis. It revealed a heterogeneous well-defined mass with solid and cystic components protruding from the perineum, suggestive of an SCT. The mass measured 74 mm × 49 mm × 74 mm in size and extending into the pelvis up to L5 level, thus elevating the urinary bladder.

The patient was referred to the paediatric surgeon and received counselling regarding postnatal prognosis and surgical management. US at 24 weeks and five days' gestation showed that the SCT had increased in size to

12.9 cm × 9.3 cm × 8.8 cm, with vascularity and intra-abdominal extension measuring 2.4 cm × 2.4 cm. The heart appeared enlarged (right > left). Cardiothoracic ratio was 0.66. There was no tricuspid regurgitation. Pleural effusion (3.7 mm) and pericardial effusion (2.8 mm) were present. MCA PSV was 60.01 cm/s (> 1.55 MoM) and AFI was 18.5 cm.

In view of the early signs of heart failure and anaemia (MCA PSV >1.55 MoM), the patient underwent foetal blood transfusion on the same day. 70 ml of blood was transfused into the umbilical vein. The blood used for transfusion was cytomegalovirus (CMV)-negative, irradiated, washed and O-negative. The pre- and post-transfusion foetal haematocrit (HCT) were 25% and 40%, respectively, with a rise of foetal haemoglobin (Hb) from 8.5 to 13.6 g/dL. Post-transfusion US performed on the same day revealed an MCA PSV of 30.89 cm/s (< 1.0 MoM) and AFI of 12.6 cm. The patient was subsequently closely followed up in the Foetal Medicine Clinic with frequent US (Table II).

In view of the increasing MCA PSV (>1.55 MoM), the patient was given a second foetal blood transfusion at 26 weeks and three days of gestation. 85 ml of blood was transfused into the umbilical vein. The pre- and post-transfusion foetal HCT were 27% and 42%, respectively, with a rise in foetal Hb from 9.2 to 14.3 g/dL. Amnioreduction was performed under aseptic technique (600 ml amniotic fluid was drained). AFI and MCA PSV post procedure were 22.6 cm and 41.53 cm/s (< 1.29 MoM), respectively. MCA PSV continued to rise (> 1.55 MoM). A third foetal blood transfusion was performed at 27 weeks and six days of gestation, and 90 ml of CMV-negative, irradiated and washed O-negative blood was transfused into the umbilical vein. The pre- and post transfusion foetal HCT were 24% and 41%, respectively, with a rise of foetal Hb

Table II Growth scan details with increasing gestation for Case 2.

Date	Gestation (wks + days)	SDS of AC	AC (mm)	Teratoma size (cm)	MCA PSV (cm/s)	MoM	AFI (cm)
1/9/2009	20	-0.30	141	5.1 × 4.8 × 4.7	28.59	1.0-1.29	-
15/9/2009	21 + 4	1.41	178	7.6 × 6.4 × 6.0	27.99	1.0-1.29	-
1/10/2009	23 + 6	-	-	11.4 × 10.5 × 7.8	41.90	1.29-1.50	12.3
8/10/2009	24 + 5	2.68	226	12.9 × 9.3 × 8.8	60.01	> 1.55	18.5
8/10/2009	24 + 5	-	-	Post-transfusion:	30.89	< 1.0	12.6
13/10/2009	25 + 4	3.25	239	12.6 × 13.0 × 9.5	40.01	1.0-1.29	19.9
15/10/2009	25 + 6	3.86	248	13.4 × 10.5 × 12.2	48.06	1.29-1.50	18.8
19/10/2009	26 + 3	-	-	-	63.10	> 1.55	-
19/10/2009	26 + 3	-	-	Post-transfusion:	41.53	1.0-1.29	22.6
22/10/2009	26 + 6	3.33	254	13.6 × 14.5 × 12.0	50.98	1.29-1.50	20.1
27/10/2009	27 + 4	4.08	-	14.3 × 14.4 × 11.8	58.14	1.50-1.55	20.0
29/10/2009	27 + 6	-	-	Post-transfusion:	68.67	> 1.55	-
3/11/2009	28 + 4	6.30	302	15.8 × 12.3 × 14.3	59.77	> 1.55	16.0

Data is missing in some cases, as measurements were not taken.

SDS: standard deviation score; AC: abdominal circumference; MCA PSV: middle cerebral artery peak systolic velocity; MoM: multiples of median; AFI: amniotic fluid index

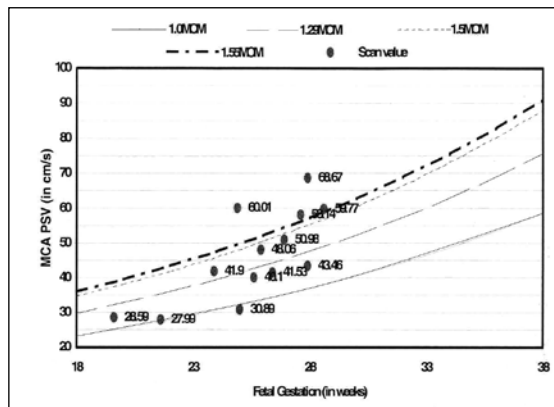


Fig. 5 Graph shows the MCA PSV trend of the foetus in Case 2 with increasing gestation.

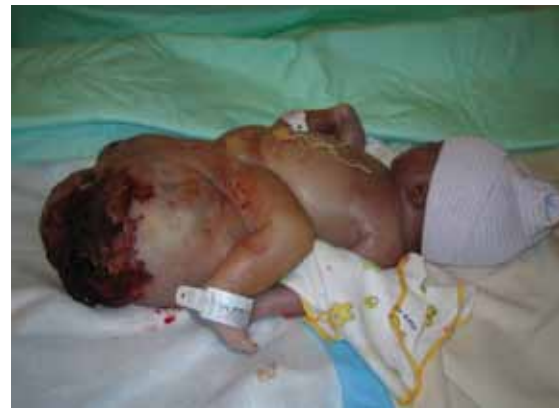

Fig. 6 Case 2. Photograph of the 3.5-kg baby boy delivered by an uncomplicated elective lower segment Caesarean section at 28 weeks and 6 days shows a large friable SCT measuring 16.0 cm × 13.0 cm × 14.5 cm, with active oozing from the tumour.

from 8.2 to 13.9 g/dL. Amnioreduction was performed under aseptic technique (1,180 ml amniotic fluid was drained). However, despite repeated transfusions, the MCA PSV levels remained high.

Repeat US at 28 weeks and four days showed an SCT measuring 15.8 cm × 12.3 cm × 14.3 cm. The heart was enlarged with a CT ratio of 0.65. The MCA PSV continued to remain high (> 1.55 MoM) and AFI was 16 cm. The inferior vena cava was dilated at 7.5 mm. A decision was made for delivery at 28 weeks and six days in view of the persistently high MCA PSV despite repeated *in utero* foetal blood transfusions. Intramuscular dexamethasone 12 mg × 2 doses, 12 hours apart was administered.

A baby boy with a birth weight of 3.59 kg was delivered by an uncomplicated elective lower segment Caesarean section at 28 weeks and six days. Despite three previous intrauterine foetal blood transfusions,

the neonate was apnoeic, with extreme pallor and bradycardia (heart rate < 60 bpm) was present at birth. There was massive haemorrhage from the large friable SCT (measuring 16.0 cm × 13.0 cm × 14.5 cm), which was complicated by disseminated intravascular coagulation (Fig. 6). The cord arterial pH was 7.261, with a base excess of -5.6 mmol/L. The neonate was intubated at one minute of life and monitored in the neonatal intensive care unit (NICU). In the NICU, two pints of packed red cell, one pint of fresh frozen plasma, 600 ml of normal saline and a bolus of recombinant factor VII were administered. The tumour was wrapped by the surgeons for tamponade. The neonate, however, continued to experience massive bleeding from the tumour and had a further drop in heart rate and blood pressure. Despite maximal, active resuscitative efforts, the neonate died 30 minutes after birth.

DISCUSSION

Prior to the late 1980s, most cases of SCTs were diagnosed at delivery with the presentation of a sacral mass. The diagnosis of SCTs is made antenatally in more than 50% of cases.⁽⁸⁾ With the advancement in obstetric US technology in recent years, the detection rate is much higher now. Serial foetal US is important when a sacral mass has been identified; it can monitor the development of polyhydramnios, tumour rupture and placentomegaly. Foetal MR imaging, although not routinely performed in SCT, is indicated in order to better assess the vascularity and nature of the tumour, as demonstrated in our second case.

Doppler US is performed to detect the reversal of diastolic blood flow in the umbilical arteries that are indicative of arteriovenous shunting through the tumour. Olutoye et al⁽⁹⁾ concluded that foetuses with abnormal umbilical artery waveforms should be considered for *in utero* intervention or early delivery to prevent foetal demise. Increased Doppler flow measurements may also be indicative of haemodynamic changes in high-output cardiac failure. However, Doppler US in SCT is not practised in our institution.

Once an SCT is diagnosed in a foetus, a multidisciplinary approach optimises the outcome. Both our patients were counselled by an expert foetal medicine specialist with regard to the diagnosis, management and prognosis. Development of polyhydramnios increases the risk of premature delivery. Volume reduction by amniocentesis, tocolysis to prevent preterm labour and corticosteroids for foetal lung maturity may be required. In both cases, the pertinent issues counselled by the paediatric surgeon included associated anomalies (vertebral, spinal, anorectal), antenatal complications like tumour vascular steal, cardiac failure with hydrops and foetal demise. Long-term issues, including a small risk of malignancy requiring regular follow-up, constipation, bowel and/or bladder incontinence and lower limb weakness in the presence of associated spinal anomalies, were also discussed in detail. Neonatologists were consulted with regard to neonatal prognosis and care. The prognosis for the foetus in our second case was predictably worse than that in our first case. In comparison to Case 1, the foetus in Case 2 had persistent abnormal MCA PSV values, with consequent repeated *in utero* foetal blood transfusions for foetal anaemia.

Foetal intervention increases the risk of preterm labour. Kum et al suggested that foetal intervention should only be considered if there is an accurate prenatal diagnosis, absence of fatal anomalies and the ability to intervene without increasing the risk of maternal

compromise.⁽¹⁰⁾ Foetal surgical interventions include amnioreduction, cyst aspiration and open surgical debulking of the SCT. Other less invasive foetal interventions are radiofrequency thermal ablation of the tumour's blood supply and tumour embolisation.

The clinical management of the mother and foetus diagnosed with SCT is based on physiological risk factors caused by the tumour and the likelihood of foetal/maternal survival if foetal surgical intervention is performed prior to delivery. In the absence of hydrops or maternal complications, delivery should be delayed as long as possible to allow foetal maturation. Once foetal lung maturity is attained, foetuses with large or highly vascular SCT should be delivered by Caesarean section so as to minimise the risk of bleeding. Postnatally, the SCT should be surgically removed as soon as possible, so as to minimise risk of bleeding and proliferation of undifferentiated tissues. Prior to surgery, CT imaging should be performed to assess the extent of the tumour and to identify pelvic involvement.

Following surgical resection, the recurrence rates for both benign and malignant SCTs have been reported to range from 7.5% to 22%.⁽³⁾ If the coccyx is involved as in Case 1 and 2, the risk of recurrence is higher. Saygili-Yilmaz et al⁽¹¹⁾ reported a case of SCT diagnosed prenatally at 32 weeks of gestation. US revealed a 14.0 cm × 12.0 cm mass with solid and cystic components in the sacral region of the foetus. MR imaging revealed no apparent intra-pelvic or intra-abdominal extent of the tumour. In contrast to our two patients, the Caesarean section in the above case was performed at 34 weeks of gestation in view of deteriorating high cardiac output compromise in the foetus. After stabilisation of the infant, the SCT was successfully excised at Day 10 of life.⁽¹¹⁾

Over a seven-year period, Chisholm et al identified nine foetuses with SCT diagnosed antenatally. Six infants survived the neonatal period. Foetal hydrops developed in three foetuses, none of whom survived. Inadequate ventilation secondary to prematurity was a contributing factor in each lethal case. This suggested that diagnosis at early gestation, the presence of foetal hydrops and prematurity predicted a poor prognosis. It was recommended that delivery should be delayed to allow for foetal development, and stabilisation of the infant should be attained before excision of the SCT.⁽¹²⁾

With optimal prenatal and clinical management, foetuses with SCTs can have a better prognosis. The two cases presented above illustrate the importance of prenatal diagnosis, management and clinical intervention: SCT complicated by hydrops and anaemia may lead to a poorer prognosis and death.

REFERENCES

1. Pantanowitz L, Jamieson T, Beavon I. Pathobiology of sacrococcygeal teratomas. *S Afr J Surg* 2001; 39:56-62.
2. Moore KA, Persaud TVN. *The Developing Human: Clinically Oriented Embryology*. 7th ed. Philadelphia: Saunders, 2002.
3. Tuladhar R, Patole SK, Whitehall JS. Sacrococcygeal teratoma in the perinatal period. *Postgrad Med J* 2000; 76:754-9.
4. Keslar PJ, Buck JL, Suarez ES. Germ cell tumours of the sacrococcygeal region: radiologic-pathologic correlation. *Radiographics* 1994; 14:607-20.
5. Shaaban AF, Kim HB, Milner R, Crombleholme T. The role of ultrasonography in fetal surgery and invasive fetal procedures. *Semin Roentgenol* 1999; 34:62-77.
6. Le Caignec C, Winer N, Boceno M, et al. Prenatal diagnosis of sacrococcygeal teratoma with constitutional partial monosomy 7q/trisomy 2p. *Prenat Diagn* 2003; 23:981-4.
7. Swamy R, Embleton N, Hale J. Sacrococcygeal teratoma over two decades: birth prevalence, prenatal diagnosis and clinical outcomes. *Prenat Diagn* 2008; 28:1048-51.
8. Gabra HO, Jesudason EC, McDowell HP, Pizer BL, Losty PD. Sacrococcygeal teratoma--a 25-year experience in a UK regional center. *J Pediatr Surg* 2006; 41:1513-6.
9. Olutoye OO, Johnson MP, Coleman BG, et al. Abnormal umbilical cord Dopplers may predict impending demise in fetuses with sacrococcygeal teratoma. A report of 2 cases. *Fetal Diagn Ther* 2003; 18:428-31.
10. Kum CK, Wong YC, Prabhakaran K. Management of fetal sacrococcygeal teratoma. *Ann Acad Med Singapore* 1993; 22:377-80.
11. Saygili-Yilmaz ES, Incki KK, Turgut M, Kelekci S. Prenatal diagnosis of type I sacrococcygeal teratoma and its management. *Clin Exp Obstet Gynecol* 2008; 35:153-5.
12. Chisholm CA, Heider AL, Kuller JA, et al. Prenatal diagnosis and perinatal diagnosis of fetal sacrococcygeal teratoma. *Am J Perinatol* 1999; 16:89-92.