

# Entangled bilateral adnexal torsion in a premenarchal girl: a laparoscopic approach

Kitporntheranunt M, Wong J, Siow A

## ABSTRACT

**Bilateral adnexal torsion is a rare event in children. A high index of suspicion, together with prompt surgical treatment, would help to save the ovaries and preserve its function. We report a case of entangled bilateral adnexal torsion managed successfully via laparoscopy. An 11-year-old premenarchal girl complained of chronic intermittent abdominal pain that worsened over 24 hours. Computed tomography of the abdomen and pelvis showed a bilobed cystic tumour (10 cm × 12 cm × 12 cm and 3 cm × 4 cm) lying in the left abdomen and another cystic tumour (10 cm × 6 cm × 5 cm) in the pelvis. At laparoscopy, entangled bilateral adnexal torsion was seen. After disentanglement and detorsion of both adnexa, bilateral ovarian cystectomy was performed, and both ovaries were preserved. This case illustrates that laparoscopic treatment is possible for large entangled bilateral adnexal torsion in children.**

**Keywords:** adnexal torsion, bilateral, entangle, laparoscopy, premenarche

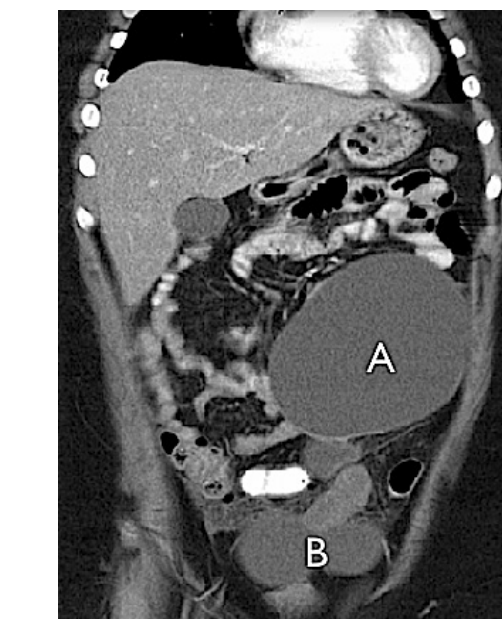
*Singapore Med J 2011;52(6):e124-e127*

## INTRODUCTION

Adnexal torsion is an uncommon condition that requires acute intervention, especially in paediatric patients. Early diagnosis and management is paramount to prevent the loss of ovarian function and to preserve fertility. Bilateral adnexal torsion is a rare event, with only a few cases reported in women using ovarian stimulating drugs<sup>(1)</sup> and in premenarchal girls with synchronous or asynchronous ovarian tumours.<sup>(2,3)</sup> A high index of suspicion, together with prompt ultrasonographic imaging, forms the cornerstone for diagnosis. We present a case of entangled bilateral adnexal torsion in a premenarchal girl, which was managed successfully by laparoscopy.

## CASE REPORT

An 11-year-old girl presented to the paediatric emergency



**Fig. 1** CT image of the abdomen shows a bilobed large cystic mass (A) extending to the upper abdomen and a biloculated cystic mass (B) in the pelvis.

department with a four-year history of intermittent lower abdominal pain that worsened over 24 hours. The pain was localised to the right iliac fossa and was constant in nature. It was not associated with nausea, vomiting, fever or a change in bowel habits. The previous episodes of pain were not precipitated by exertion and usually resolved spontaneously.

Physical examination revealed a relatively comfortable girl who was 137 cm tall and weighed 53.2 kg (body mass index [BMI] 32.3 kg/m<sup>2</sup>). Her vital signs were normal (pulse rate 85/min, blood pressure 120/73 mmHg, temperature 36.8°C) and her abdomen was soft and mildly tender over the umbilical area, with no rebound tenderness or guarding. A smooth and firm mass (15 cm × 10 cm) was palpated at the periumbilical. The mass was freely mobile from left to right, and it was possible to get above the mass. It was dull to percussion and did not have any flow murmurs within.

Abdominal ultrasonography revealed a large cystic tumour (17 cm × 13 cm × 10 cm) in the right adnexa and

**Minimally Invasive Surgery Unit, KK Women's and Children's Hospital, 100 Bukit Timah Road, Singapore 229899**

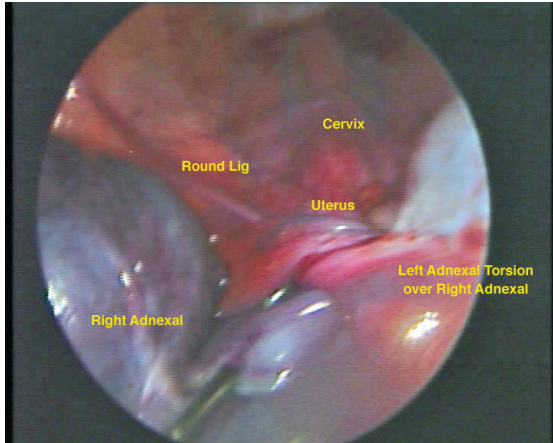
Kitporntheranunt M, MD  
Clinical Fellow

Siow A, MMed, MRANZCOG, MRCOG  
Senior Consultant and Director

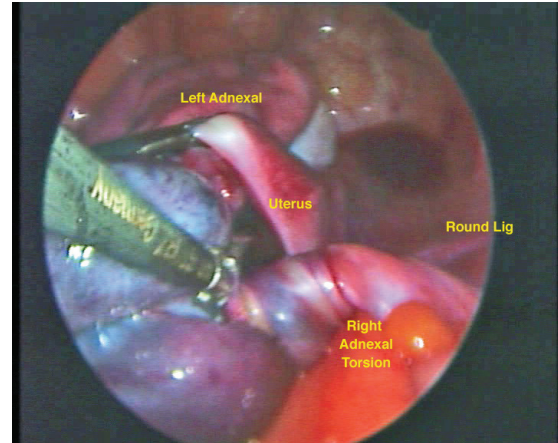
**Department of Paediatric Surgery**

Wong J, MBChB, MRCS  
Associate Consultant

**Correspondence to:**  
Dr Anthony Siow  
Tel: (65) 6293 4044  
Fax: (65) 6297 0339  
Email: anthonySiow@gmail.com



**Fig. 2** Laparoscopic image shows left adnexal torsion displaced to the right pelvis and lying above the right infundibulopelvic ligament.



**Fig. 3** Laparoscopic image shows the left adnexa decompressed, untwisted and replaced to the left pelvis, exposing right adnexal torsion.

another cystic tumour (10 cm × 6 cm × 5 cm) in the left adnexa. Both tumours had thin walls with no septation, solid lesions or blood flow within. Computed tomography (CT) imaging (Fig. 1) done eight hours later revealed the larger tumour (A) as bilobed (10 cm × 12 cm × 12 cm and 3 cm × 4 cm), lying toward the left abdomen and extending superiorly to the left hypochondrium (Fig. 1). The left adnexal tumour (B) (10 cm × 6 cm × 5 cm) seen previously on ultrasonography appeared to be displaced further inferiorly into the deeper pelvis. Both ovaries were not identified and the bowels were unremarkable. The ovarian tumour markers were normal.

With the provisional diagnosis of ovarian torsion, an emergency laparoscopy was performed. Following general anaesthesia, a urinary catheter was inserted, and the patient was placed in supine position as vaginal instrumentation was not consented. Open entry pneumoperitoneum was created at the umbilicus. The initial operative finding revealed a 17-cm bilobed tumour in the right peritoneal cavity and an ischaemic-looking 8-cm tumour in the left pelvis. The uterus was not visualised initially, as the tumours occupied most of the lower abdominal cavity and pelvis. A second 5-mm port was placed 4 cm superior to the umbilicus, and the laparoscopic camera was re-positioned cephalad for better visualisation. A third 5-mm port was inserted in the left abdominal region at the level of the umbilicus. This third port, together with the 10-mm umbilical port, was used as the operative port for the surgery.

To locate the small pre-pubescent uterus, both the round ligaments were traced from the inguinal regions toward the midline. It then became clear that the 17-cm bilobed tumour in the right peritoneal cavity was the torted left adnexa (Fig. 2). It consisted of a 12-cm

peritubular/broad ligament clear cyst and a 5-cm ovarian cyst. Following decompression of the 12-cm peritubular/broad ligament cyst, the torted left ovary was untwisted over two rounds and replaced to the left pelvis anterior to the uterus. By doing so, the normal pre-pubescent uterus was seen lying on top of the 8-cm tumour in the left pelvis. Further inspection revealed that this tumour was the twisted right adnexa (Fig. 3). Untwisting the 8-cm tumour over three rounds revealed three multiloculations of 5–8 cm cysts involving the right ovary and para-ovarian regions. Laparoscopic cystectomy was done to remove these cysts with no cyst rupture.

We then turned our attention to the left peritubular/broad ligament mass that was decompressed earlier. The previous broad ligament incision was extended to 3 cm and the cyst removed by turning the broad ligament inside-out through the incision. The left ovarian cyst was subsequently removed. All the cysts were removed using a lap-sac. At the end of the surgery (160 min), both tubes and ovaries appeared healthy, with minimal residual signs of ischaemia. A peritoneal drain was placed and removed on postoperative Day 2 when there was no more drainage. The postoperative recovery was uneventful, and the patient was discharged on postoperative Day 3. The final histology confirmed benign bilateral serous cysts, with no borderline features or malignancy. Ultrasonography done at two months' follow-up revealed a pre-pubertal uterus and normal-size ovaries. There were no complaints of abdominal pain.

## DISCUSSION

Adnexal torsion is uncommon and accounts for 2.7% of all acute abdominal pain in children.<sup>(4)</sup> It is usually unilateral and can involve both the ovary and fallopian

tube, frequently in association with ovarian or para-ovarian cysts. Bilateral adnexal torsion is a rare event, with only a handful of cases reported till date.<sup>(2,3)</sup> To the best of our knowledge, this is the first reported case of entangled bilateral adnexal torsion in a premenarchal girl. Adnexal torsion in children can present with nonspecific symptoms. Common presentations include recurrent lower abdominal pain (83%), nausea or vomiting (70%) and sometimes, a palpable abdominal mass (36%).<sup>(4)</sup> In cases where torsion and spontaneous detorsion occur, symptoms can come and go over years. As ovarian cysts  $\leq 5$  cm may not be detected clinically in an obese patient, the diagnosis of adnexal torsion can be difficult. These two factors may have contributed to the delayed diagnosis of chronic adnexal torsion in this case, thereby allowing the cysts to enlarge to clinically palpable sizes.

When abdominal pain persists in the presence of palpable abdominal mass, urgent imaging is recommended in order to exclude torsion. Although ultrasonography is usually the initial modality employed, the sonographic features of torsion, such as unilateral enlarged ovary ( $> 4$  cm), a 'string of pearls' sign, coexistent mass within the twisted ovary, free pelvic fluid and twisted vascular pedicle, are not highly specific.<sup>(5)</sup> Addition of Doppler studies to demonstrate the patterns of adnexal blood flow may aid the diagnosis. Although normal Doppler studies cannot exclude adnexal torsion, the absence of venous flow gives a positive predictive value of 94%.<sup>(6)</sup> Increasingly, CT and magnetic resonance (MR) imaging are being used to differentiate adnexal torsion from other pathologies. Features such as a smooth, thickened wall adnexal mass abnormally located in the pelvis with ipsilateral deviation of the uterus on CT and enlargement/hyperintensity of the ovarian stroma on MR image give a raised suspicion for torsion.<sup>(5,7,8)</sup> In addition, CT and MR imaging can provide additional details regarding large tumours and accurately differentiate between intraperitoneal and retroperitoneal, solid and cystic as well as solitary and septated masses. This radiological information, together with ovarian tumour markers, is crucial for the planning of surgical extirpation.

One of the mechanisms of adnexal torsion in young girls relates to the relative elongation of adnexal ligaments due to the small uterus within the pelvis and the relatively higher position of the ovary at the pelvic brim. This structural configuration, together with the underdeveloped supporting connective tissue surrounding the ovary, predisposes to torsion when an abrupt change in motion or intraabdominal pressure occurs, as seen in the active lifestyle of children.<sup>(3)</sup> Adnexal torsion is also frequently associated with adnexal mass. The US Healthcare Cost

and Utilization Project for the year 2000 showed that the prevalence of adnexal mass in female children (age  $< 14$  years) was 4.5/10,000.<sup>(9)</sup> Torsion was seen more frequently in children with large adnexal mass or adnexal mass of para-ovarian position, as they present an unbalanced weight in the adnexal for torsion. Where torsion is associated with cysts, it is prudent to remove them for histology and to prevent recurrent torsion. Prevention of recurrent torsion can be done through prophylactic surgical interventions, either of the same ovary or the contralateral ovary, as reported by many studies.<sup>(2,10)</sup> Although some doctors have recommended elective oophorectomy in all children who have had ovarian torsion,<sup>(10)</sup> there is currently no consensus on the proper management of this phenomenon in the literature.<sup>(4,11)</sup>

In the past, it was advocated that ischaemic-looking adnexal torsions be removed completely without detorsion. The concern then was with embolisation of thrombus and toxic products.<sup>(12)</sup> It is now believed that this embolic phenomenon is either not present or is clinically insignificant. Recently, many reports have shown that a more conservative approach with conservation of the torqued adnexa is a feasible option.<sup>(13)</sup> Frequently, an inspection of ischaemic-looking adnexa cannot differentiate between reversible tissue ischaemia and irreversible tissue necrosis. Oelsner et al<sup>(14)</sup> found that in 102 cases of torsion, even with a median torsion duration of 16 (range 2–144) hours, 93% of patients subsequently had normal follicular development after detorsion of an ischaemic-looking ovary. This information is highly pertinent when dealing with adnexal torsion in premenarchal patients, as the preservation of ovarian function and fertility is paramount.

Laparoscopic surgery, with its benefits of less blood loss, less pain and faster recovery, is the ideal route for adnexal surgery. In a premenarchal girl, the reduced risk of adhesion formation from laparoscopy is vital for preserving her future fertility. In addition, less pain, smaller incisions and shorter hospital stay reduce the psychological impact of surgery in paediatric patients.<sup>(3,15)</sup> Laparoscopy remains a viable option, even in the presence of large masses, as evidenced in this case. To accommodate laparoscopic dissection of the large mass, we placed our operative ports higher up the abdominal cavity, with the camera port sited 4 cm above the umbilicus. This configuration provided a panoramic view of the entire peritoneal cavity. It also effectively employed the entire peritoneal cavity as the operative field to tackle the large tumours. As uterine manipulation was not consented, traction on the round ligaments would

normally suffice in manipulating the small uterus. In this case, identification of the round ligaments proved to be an important step to elucidate that the bilateral adnexal torsions were further entangled together.

It is recommended to restore the normal anatomy by detorting the adnexa before proceeding to cystectomy, as this would enable a clear view of the ureter so as to prevent injury. In this case, restoration of the pelvic anatomy and detorsion were only possible by decompressing the 12-cm peritubular/broad ligament cyst, which, on radiological imaging appeared to contain only fluid. Cystectomy of a torqued ovary should be done with utmost care, as the tissue can be friable and bloody. A systematic separation of the cyst from the ovarian tissue, starting circumferentially from the periphery of the ovary toward the centre of the hilum, is advised. This ensures that the cyst can be removed in one piece, securing the main vascular attachment at the hilum last. As the degree of re-perfusion to the ovary after surgery is variable, leaving a peritoneal drain will enable early detection of primary haemorrhage in the postoperative period.

This case demonstrates that bilateral adnexal torsion can be difficult to diagnose. When diagnosed, conservative laparoscopic surgery to preserve ovarian function is an option in the paediatric patient. Despite the large size of the adnexal torsion, placing the laparoscopic ports higher up the abdominal wall helps facilitate surgery. Restoring normal anatomy and detorsion are important steps in such a procedure, and in this instance, it revealed a rare case of entangled bilateral adnexal torsion.

## REFERENCES

1. Bider D, Goldenberg M, Ben-Rafael Z, Oelsner G. Bilateral adnexal torsion after clomiphene citrate therapy. *Hum Reprod* 1991; 6:1443-4.
2. Ozcan C, Celik A, Ozok G, Erdener A, Balik E. Adnexal torsion in children may have a catastrophic sequel: asynchronous bilateral torsion. *J Pediatr Surg* 2002; 37:1617-20.
3. Takeda A, Manabe S, Mitsui T, Nakamura H. Laparoscopic management of mature cystic teratoma of bilateral ovaries with adnexal torsion occurring in a 9-year-old premenarchal girl. *J Pediatr Adolesc Gynecol* 2006; 19:403-6.
4. Breech LL, Hillard PJ. Adnexal torsion in pediatric and adolescent girls. *Curr Opin Obstet Gynecol* 2005; 17:483-9.
5. Chang HC, Bhatt S, Dogra VS. Pearls and pitfalls in diagnosis of ovarian torsion. *Radiographics* 2008; 28:1355-68.
6. Ben-Ami M, Perlitz Y, Haddad S. The effectiveness of spectral and color Doppler in predicting ovarian torsion. A prospective study. *Eur J Obstet Gynecol Reprod Biol* 2002; 104:64-6.
7. Hiller N, Appelbaum L, Simanovsky N, et al. CT features of adnexal torsion. *AJR Am J Roentgenol* 2007; 189:124-9.
8. Ghossain MA, Hachem K, Buy JN, et al. Adnexal torsion: magnetic resonance findings in the viable adnexa with emphasis on stromal ovarian appearance. *J Magn Reson Imaging* 2004; 20:451-62.
9. Schultz KA, Ness KK, Nagarajan R, Steiner ME. Adnexal masses in infancy and childhood. *Clin Obstet Gynecol* 2006; 49:464-79.
10. Crouch NS, Gyampoh B, Cutner AS, Creighton SM. Ovarian torsion: to pex or not to pex? Case report and review of the literature. *J Pediatr Adolesc Gynecol* 2003; 16:381-4.
11. Oelsner G, Shashar D. Adnexal torsion. *Clin Obstet Gynecol* 2006; 49:459-63.
12. Hibbard LT. Adnexal torsion. *Am J Obstet Gynecol* 1985; 152:456-61.
13. Aziz D, Davis V, Allen L, Langer JC. Ovarian torsion in children: is oophorectomy necessary? *J Pediatr Surg* 2004; 39:750-3.
14. Oelsner G, Cohen SB, Soriano D, et al. Minimal surgery for the twisted ischaemic adnexa can preserve ovarian function. *Hum Reprod* 2003; 18:2599-602.
15. Broach AN, Mansuria SM, Sanfilippo JS. Pediatric and adolescent gynecologic laparoscopy. *Clin Obstet Gynecol* 2009; 52:380-9.