

# Multiple aberrant coeliac trunk ramifications

Paraskevas G K, Raikos A

## ABSTRACT

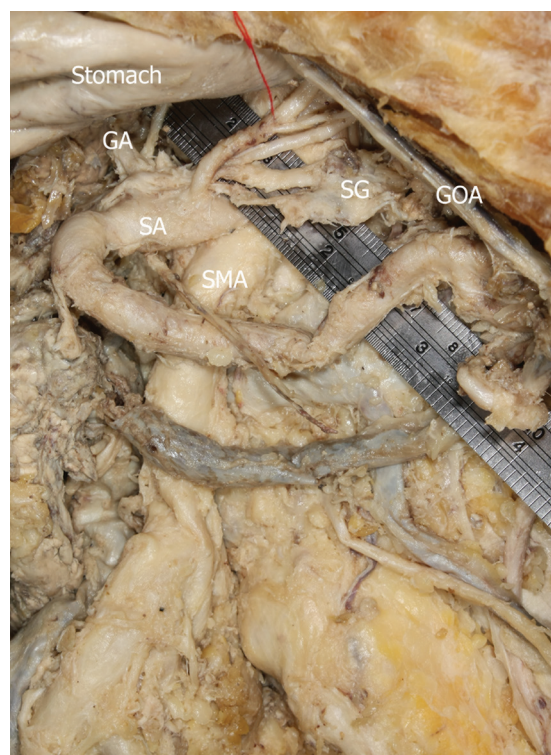This study describes a routine educational cadaveric dissection, where multiple aberrant coeliac trunk branches were noticed. Specifically, the accessory left hepatic artery emerged from the left gastric artery, while the left inferior phrenic artery originated from the coeliac trunk. The accessory left suprarenal artery was found to commence from the coeliac trunk, whereas two aberrant left suprarenal arteries branched separately from the origin of the left inferior phrenic artery. Finally, the accessory jejunal artery was observed to originate from the coeliac trunk. Anatomical variations of the coeliac trunk branches can significantly alter the surgical management of the upper abdomen; hence, clinicians and radiologists should be aware of such aberrant vascular anatomy so as to reduce the incidence of surgical complications.

**Keywords:** abdominal aorta, celiac trunk, hepatic artery, inferior phrenic artery, suprarenal artery, variation

*Singapore Med J 2011;52(7):e147-e149*

## INTRODUCTION

For decades, arterial variations of the aorta have attracted the attention of anatomists, clinicians and radiologists due to their prominent significance in many surgical specialties. The coeliac trunk is one of the most well-documented arterial trunks, with many researchers pondering on the topic, as well as providing detailed studies and an impressive number of specimens. The first description of normal and aberrant coeliac trunk anatomy was published in 1756 by Haller.<sup>(1)</sup> However, studies regarding the inferior phrenic artery (IPA) are limited, since they were considered to be of minor clinical interest in the past. Nowadays, it is known that the IPA employs the most frequent origin of extrahepatic arterial blood source in hepatocellular carcinoma.<sup>(2)</sup> In cases of unresectable hepatic tumour involving collateral arterial supply from the right or left IPA, the interventional radiologist should precisely detect the appropriate pathway for catheter placement during tumour embolisation. If involved,



**Fig. 1** Photograph shows a coeliac trunk with multiple aberrant branching patterns.

GA: left gastric artery; SA: splenic artery; SG: suprarenal gland; SMA: superior mesenteric artery; GOA: gastro-omental artery

the IPA contributes to increased liver blood flow in the event of hepatic artery occlusion.<sup>(2)</sup> We present a case of combined arterial variants that add further to the expanding list of coeliac trunk variations.

## CASE REPORT

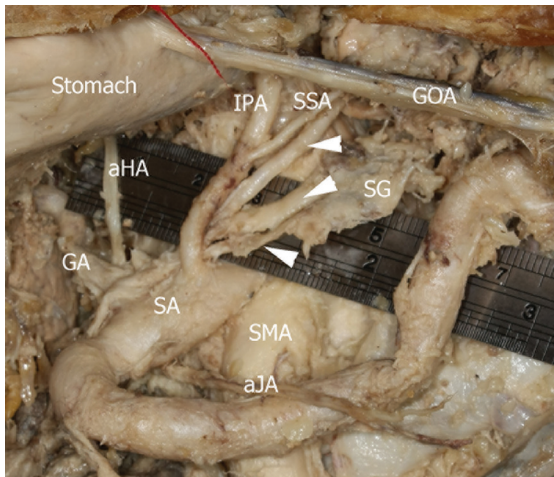
During a routine educational dissection course of a formalin-embalmed cadaver of a 94-year-old man, multiple aberrant coeliac trunk branches were identified. After careful resection of the interrupting tissues, the typical three-branch coeliac trunk, originating from the anterior wall of the abdominal aorta, 6 mm proximal to the superior mesenteric artery, was observed (Fig. 1). However, after the initial portion of the coeliac trunk, the following aberrant anatomy was noticed: (1) The splenic artery originated from the midline of the anterior aspect of the coeliac trunk, while the common hepatic artery arose from the left aspect of the trunk. The left

Department of  
Anatomy,  
Medical School,  
Aristotle University  
of Thessaloniki,  
PO Box 300,  
Thessaloniki 54124,  
Greece

Paraskevas GK,  
MD, PhD  
Assistant Professor

Raikos A, MD,  
PhD  
Student

**Correspondence to:**  
Dr George K  
Paraskevas  
Tel: (30) 23 1099 9330  
Fax: (30) 23 1099 9330  
Email: g\_paraskevas@  
yahoo.gr



**Fig. 2** Photograph shows multiple variations of the coeliac trunk branching pattern in a male cadaver. The arrowheads indicate accessory suprarenal arteries.

IPA: inferior phrenic artery; aHA: accessory hepatic artery; GA: left gastric artery; SSA: superior suprarenal artery; SA: splenic artery; SMA: superior mesenteric artery; SG: suprarenal gland; GOA: gastro-omental artery; aJA: accessory jejunal artery.

gastric artery branched from the left aspect of the coeliac trunk instead of from the typical origin pattern from the right aspect of the aorta; (2) An accessory left hepatic artery originated from the left gastric artery. It emerged at a distance of 10 mm from the branching point of the left gastric artery, coursed straight upward and supplied the left lobe of the liver; (3) The left IPA originated at a distance of 12 mm from the origin of the coeliac trunk. After a short course, the artery provided the left superior suprarenal artery; (4) An accessory left suprarenal artery commenced between the splenic and the common hepatic artery; (5) Two supernumerary left suprarenal arteries emerged separately from the origin of the left IPA (Fig. 2). The first artery terminated in the middle of the left suprarenal gland, while the second supplied the inferior pole of the gland; and (6) An accessory jejunal artery originated from the coeliac trunk.

## DISCUSSION

Studies regarding coeliac trunk and hepatic artery variations are abundant in the literature. Some of them describe classifications for multiple types of arterial variants.<sup>(3,4)</sup> Arjhansiri et al observed a typical pattern of hepatic artery in 80.5% of the 200 patients in their angiographic study, and an accessory left hepatic artery initiating from the left gastric artery in 5.5% of patients. Interestingly, 1.5% of the studied arterial systems did not match those in Arjhansiri et al's study.<sup>(5)</sup> In a study conducted on 1,000 donor livers, Hiatt et al reported normal hepatic artery anatomy in 75.7% of the specimens,

and found the accessory left hepatic artery originating from the left gastric artery in 9.7% of the specimens.<sup>(4)</sup>

Hepatic arterial tree anomalies include replaced right hepatic artery in 11%–21% of cases and replaced left hepatic artery in 3.8%–10% of cases, while accessory right and left hepatic arteries have an incidence of 0.8%–8%, according to a recent review.<sup>(6)</sup> Apart from a normal or variable origin, the common hepatic artery may have an unusual course, which can be an incidental finding during angiographic studies, anatomical dissection or surgical intervention.<sup>(7)</sup> In a single case study, Nayak et al outlined the presence of a left phrenic artery and gastroduodenal artery in addition to the three classic branches from the coeliac trunk, while a connecting loop was present between the superior and inferior pancreaticoduodenal arteries. The above aberrant arterial combination carries clinical significance for surgeons dealing with a variety of interventions (e.g. gastric and duodenal ulcers, mobilisation of the head of the pancreas), in terms of minimising blood loss.<sup>(8)</sup> Surgeons operating on the upper abdomen, such as during liver transplantation and the biliary tract, must be aware of such anatomical variants, as any erroneous artery ligation could lead to liver lobe or segmental necrosis.

Since there are limited studies and study materials focusing on the origin of inferior phrenic and suprarenal arteries, very few classifications regarding their origin are available. However, variation in IPA origin is a rule, rather than an exception. In a study of 74 cadavers, the artery arose from the abdominal aorta and the coeliac trunk in 31 and 34 cadavers, respectively.<sup>(3)</sup> A study of 383 computed tomography (CT) images showed that the site of IPA origin was the coeliac trunk and aorta in 152 and 148 cases, respectively.<sup>(9)</sup> The IPA has also been found to originate from the renal ( $n = 59$ ), left gastric ( $n = 14$ ), hepatic ( $n = 8$ ), superior mesenteric ( $n = 1$ ) and contralateral IPA ( $n = 1$ ) arteries.<sup>(6)</sup>

During conventional computed imaging, it can sometimes be difficult to identify the IPA due to its small diameter. The use of three-dimensional contrast-enhanced dynamic magnetic resonance (MR) imaging facilitates accurate visualisation of the right and left IPA in 84% and 73% of healthy individuals, respectively.<sup>(10)</sup> The left IPA may serve as collateral blood supply in cases of both right and left gastric artery occlusions.<sup>(11)</sup> Interestingly, collateral liver blood supply may occur in occluded or non-occluded hepatic arteries.<sup>(12)</sup> There are reports about the role of IPAs in hepatocellular carcinoma. Loukas et al highlighted that the right IPA was 2.5 mm more dilated in one out of 30 liver specimens affected by hepatocellular carcinoma.<sup>(13)</sup> This finding affirms the assumption that

these tumours may receive increased blood supply from IPAs. Embryologically, the coeliac trunk as well as the IPAs derive from six pairs of ventral splanchnic vessels (subphrenic, upper, middle, lower ventricular and upper and lower intestinal). During foetal development, these pairs span and disappear; however, the persistence of longitudinal channels between primitive vessels may lead to vascular anomalies or variations.<sup>(14)</sup>

Adachi studied 26 suprarenal glands and reported that the superior suprarenal artery originated from the IPA in 23 cases, while direct origin from the aorta was observed in only one case. The middle suprarenal artery was found arising from the IPA and the aorta in five and 11 cases, respectively. The inferior suprarenal artery was missing in three out of 265 cases.<sup>(3)</sup> Manso and DiDio reported that the right superior suprarenal artery arose from the right IPA in 83.3% of cases, while the left superior suprarenal artery branched from the left IPA in 80% of cases. The coeliac trunk originated from the right and left superior suprarenal artery in 6.7% and 6.7% cases, respectively. The aorta was the most common site of origin for the right (53.3%) and left (46.7%) middle suprarenal arteries. Finally, the right and left inferior suprarenal arteries emerged from the right and left renal arteries in 70% and 50% of cases, respectively.<sup>(15)</sup>

In conclusion, knowledge of the variations of the coeliac trunk, hepatic artery and IPA can significantly assist in liver tumour treatment, liver transplantation and biliary tract surgery. Identification of typical and non-typical IPA origins may significantly alter the outcome of transcatheter chemoembolisation in hepatocellular carcinoma treatment, as the inferior phrenic and hepatic arteries are equally important to tumour blood supply and the probability of metastasis.

## REFERENCES

- Haller A. *Icones anatomicae in quibus aliquae partes corporis humani delineatae proponuntur et arteriarum potissimum historia continetur*. Göttingen: Vandenhoeck, 1756.
- Takeuchi Y, Arai Y, Inaba Y, et al. Extrahepatic arterial supply to the liver: observation with a unified CT and angiography system during temporary balloon occlusion of the proper hepatic artery. *Radiology* 1998; 209:121-8.
- Adachi B. *Das Arteriensystem der Japaner*. Kyoto: Verlag der Kaiserlich-Japanischen Universität zu Kyoto. Tokyo: Kenyusha Press, 1928.
- Hiatt JR, Gabbay J, Busutil RW. Surgical anatomy of the hepatic arteries in 1000 cases. *Ann Surg* 1994; 220:50-2.
- Arjhansiri K, Charoenrat P, Kitsukjit W. Anatomic variations of the hepatic arteries in 200 patients done by angiography. *J Med Assoc Thai* 2006; 89 Suppl 3:S161-8.
- Shukla PJ, Barreto SG, Kulkarni A, Nagarajan G, Fingerhut A. Vascular anomalies encountered during pancreatoduodenectomy: do they influence outcomes? *Ann Surg Oncol* 2010; 17:186-93.
- Wang MJ, Cheng Z, Wang R, Li Y, Zhou ZG. Unusual course of the common hepatic artery originating from the coeliac trunk. *Surg Radiol Anat* 2010; 32:883-5.
- Nayak SR, Prabhu LV, Krishnamurthy A, et al. Additional branches of coeliac trunk and its clinical significance. *Rom J Morphol Embryol* 2008; 49:247-9.
- Gwon DI, Ko GY, Yoon HK, et al. Inferior phrenic artery: anatomy, variations, pathologic conditions, and interventional management. *Radiographics* 2007; 27:687-705.
- Ito K, Kim MJ, Mitchell DG, Honjo K. Inferior phrenic arteries: depiction with thin-section three-dimensional contrast-enhanced dynamic MR imaging with fat suppression. *J Magn Reson Imaging* 2001; 13:201-6.
- Seki H, Kimura M, Yoshimura N, et al. Gastric toxicity related to perfusion of the stomach via the left inferior phrenic artery during hepatic arterial infusion chemotherapy: report of two cases. *Radiat Med* 1999; 17:435-8.
- Gokan T, Hashimoto T, Matsui S, et al. Helical CT demonstration of dilated right inferior phrenic arteries as extrahepatic collateral arteries of hepatocellular carcinomas. *J Comput Assist Tomogr* 2001; 25:68-73.
- Loukas M, Hullett J, Wagner T. Clinical anatomy of the inferior phrenic artery. *Clin Anat* 2005; 18:357-65.
- Murakami T, Ohtsuka A, Piao DX. Typology of the human coeliac, left gastric, splenic, hepatic, superior mesenteric, inferior mesenteric and inferior phrenic arteries. *Okayama Igakkai Zasshi* 1995; 107:219-26.
- Manso JC, DiDio LJ. Anatomical variations of the human suprarenal arteries. *Ann Anat* 2000; 182:483-8.