

Fistulisation of pyogenic liver abscess into the portal vein and bile ducts

Aydin C, Kayaalp C, Kutlu R, Yilmaz S

ABSTRACT

We report pyogenic liver abscess complicated by fistulisation into the portal vein and bile ducts in a 58-year-old diabetic woman, who was admitted to the hospital with fever, chills and rigors. Abdominal ultrasonography and computed tomography demonstrated a 7-cm multiloculated abscess in segment III, close to the left branch of the portal vein. The abscess was drained under fluoroscopic guidance in a single pass. Pus was aspirated, and diluted water-soluble contrast was injected into the cavity. Early films revealed filling of the cavity. Later, the contrast appeared in the bile ducts and left branch of the portal vein. Radiological intervention was discontinued. Immediate surgery, including left lateral segmentectomy, was performed. The preoperative course was uneventful, except for superficial surgical site infection. We opine that a hepato-venous fistula is an indication for surgical intervention, and that early resection of the fistula can prevent severe septic complications.

Keywords: bile duct, hepatectomy, interventional radiology, liver abscess, portal vein

Singapore Med J 2011;52(7):e153-e155

INTRODUCTION

The incidence of pyogenic liver abscess has remained constant for the last 100 years. Approximately 40% of patients with pyogenic liver abscesses develop systemic or local complications, increasing both morbidity and mortality.⁽¹⁾ Generalised sepsis and pleural effusion are the most common systemic and local complications of pyogenic liver abscess. Other complications include rupture into cavities, portal vein thrombosis, hepatic vein or vena cava inferior occlusion, hepatic artery pseudoaneurysms, haemobilia, and very rarely, fistulisation into the hepatic veins or portal vein.⁽²⁻¹⁰⁾ We report a case of pyogenic liver abscess complicated by fistulisation into both the portal vein and bile ducts, which was treated by radical surgery.

CASE REPORT

A 58-year-old diabetic woman was admitted with a one-week history of intermittent fever with chills and rigors. She had undergone cholecystectomy for acute cholecystitis one month ago. Physical examination revealed fever and tender hepatomegaly. Laboratory tests showed elevated white blood count and slightly abnormal liver function. Abdominal ultrasonography (US) and computed tomography (CT) revealed a 7-cm multi-loculated abscess in segment III of the liver, close to the left portal vein. Intrahepatic and extrahepatic bile ducts were normal. Intravenous antibiotics were administered and percutaneous drainage was planned.

The abscess was drained under fluoroscopic guidance with a 22G needle in a single pass. Pus was aspirated, and diluted water-soluble contrast was injected into the abscess cavity. Early films revealed filling of the abscess cavity, and later, contrast appeared in the bile ducts and branch of the portal vein (Fig. 1). Excessive contrast injection was avoided so as to prevent flushing septic material into the circulation through the fistula. No percutaneous catheter was placed, and immediate surgical intervention was planned for the complicated liver abscess.

Left lateral segmentectomy (segment II–III resection) was performed without any complications. The liver resection line was away from the abscess and fistula tract. Resection was performed from the healthy tissue, and the cutting line was almost 3 cm away from the fistula tract. During hepatectomy, we did not open the abscess cavity and did not detect any portal pyaemia, thrombosis or fistula during the liver resection. Macroscopic examination of the opened specimen after resection confirmed that the fistula tract was indeed located between the abscess cavity and the branch of the portal vein. There was no portal thrombosis noted. Postoperative course was uneventful except for superficial surgical site infection. The patient was asymptomatic at 24 months follow-up.

DISCUSSION

Nearly all pyogenic liver abscesses are fatal if left

Department of General Surgery, Inonu University, Turgut Ozal Medical Centre, Malatya 44315, Turkey

Aydin C, MD
Assistant Professor

Kayaalp C, MD
Professor

Yilmaz S, MD
Professor

Department of Radiology

Kutlu R, MD
Associate Professor

Correspondence to:
Prof Cuneyt Kayaalp
Tel: (90) 422 341 0660 / 3706
Fax: (90) 422 341 0229
Email: cuneytkayaalp@hotmail.com

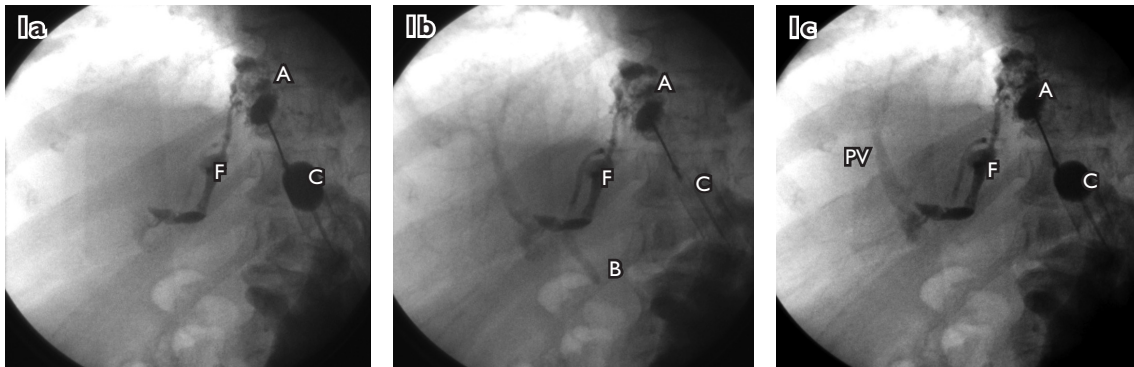


Fig. 1 Fluoroscopic images show the fistula between the bile ducts and portal vein. (a) The catheter, abscess cavity and fistula tract were visualised; (b) The bile duct first appeared and later, the portal vein was demonstrated; (c) The fistula, abscess and catheter can all be demonstrated. A: abscess; F: fistula; C: catheter; B: bile duct; PV: portal vein

untreated. Factors such as old age, clinical sepsis, diabetes mellitus and malignancy are associated with high mortality rates.^(11,12) Free perforation or rupture into neighbouring organs also increases morbidity and mortality. As reported by Chou et al, the overall mortality rate in ruptured and non-ruptured pyogenic liver abscesses was 43.5% and 15.5%, respectively.⁽¹³⁾ Therefore, early diagnosis and prompt therapy of pyogenic liver abscess are essential in order to reduce its complications as well as the associated morbidity and mortality.

Liver abscess is usually diagnosed using noninvasive radiologic imaging. US is a useful imaging modality for diagnosis, but CT is a more ideal diagnostic tool, as it has 97% sensitivity.⁽¹⁴⁾ In our case, the liver abscess was diagnosed with both US and CT. Although magnetic resonance imaging using T1- and T2-weighted and serial gadolinium-enhanced gradient-echo images has been used to differentiate hepatic abscesses from other focal hepatic lesions, the role of more sophisticated imaging techniques remains undefined.⁽¹⁵⁾

Complications associated with liver abscess, such as free perforation or external compression, can easily be diagnosed with noninvasive radiologic methods, but it is more difficult to demonstrate fistulae of the vascular or biliary structure using noninvasive methods. In the past, percutaneous or endoscopic imaging methods have been used to demonstrate biliary or venous fistulae in abscess cavities.⁽⁶⁻⁸⁾ In our case, neither US nor CT demonstrated the fistula between the abscess and the portal vein or bile ducts. We diagnosed the fistula by injecting contrast into the abscess cavity under fluoroscopic guidance during percutaneous aspiration. Percutaneous aspiration and drainage under US or CT guidance is a useful and popular method for treatment of pyogenic liver abscess. As abscess communications can be overlooked with simple aspiration and drainage, injection of contrast into

the cavity under fluoroscopic guidance is essential for the diagnosis of cavity-related fistulae.

The most common systemic complication associated with pyogenic liver abscess is sepsis, which may occur due to venous or lymphatic communications of the abscess cavity. These communications are usually small and do not cause massive bacterial dissemination, and these bacteraemia usually resolve with antibiotics. However, when a major vessel communicates with the abscess cavity, massive bacterial dissemination leading to severe septic deterioration can be expected. Chung et al reported two cases of hepato-venous fistula (fistulous communications between the liver abscess and the hepatic or portal veins) encountered during abscessography of the liver. Both cases were treated with percutaneous drainage and antibiotics, which resulted in acute septic deterioration requiring prolonged intensive medical care and ventilatory support.⁽⁶⁾ There was no severe sepsis in our case despite extensive hepato-venous communications. We conclude that immediate surgical intervention helps to prevent severe septic complications. Traditionally, surgery for liver abscess is indicated for coexisting biliary pathologies, perforated abscess and unsuccessful percutaneous interventions. We believe that the diagnosis of hepato-venous fistula is an indication for early surgical intervention for pyogenic liver abscess.

REFERENCES

1. Barnes SA, Lillemo KD. Liver abscess and hydatid cyst disease. In: Zinner MJ, Schwartz SI, Ellis H, eds. *Maingot's Abdominal Operations*. 10th ed. Stamford: Appleton & Lange, 1997: 1513-45.
2. Yang DM, Kim HN, Kang JH, et al. Complications of pyogenic hepatic abscess: computed tomography and clinical features. *J Comput Assist Tomogr* 2004; 28:311-7.
3. Thomas MR, DeFriend D, Edwards A, Jackson SA. Portal vein thrombosis and multiple hepatic abscesses diagnosed by percutaneous transhepatic cholangiography (PTC). *Clin Radiol* 2002; 57:73-4.

4. Kang M, Bapuraj JR, Khandelwal N, et al. Liver abscess associated with hepatic artery pseudoaneurysm with arteriovenous fistula: imaging and interventional management. *Acta Radiol* 2006; 47:162-6.
5. Webber RJ, Coe JI. Rupture of pyogenic hepatic abscess into hepatic vein; report of a case. *Surgery* 1950; 27:907-10.
6. Chung YF, Tay KH, Stan B, et al. Percutaneous drainage of liver abscess complicated by hepato-venous fistula. *Singapore Med J* 2003; 44:299-301.
7. O'Connor AR, Curtis H, Dunn WK. Portal venous opacification at ERCP in association with multiple hepatic abscesses and portal vein thrombosis. *Clin Radiol* 2000; 55:980-2.
8. Skelly MM, Ryder SD. Images in Hepatology. Liver abscesses with biliportal fistula. *J Hepatol* 1999; 31:365.
9. Khalil A, Chadha V, Mandapati R, et al. Hemobilia in a child with liver abscess. *J Pediatr Gastroenterol Nutr* 1991; 12:136-8.
10. Urschel HC Jr, Skinner DB, Mcdermott WV Jr. Hemobilia secondary to liver abscess. Report of a case treated by partial hepatectomy. *JAMA* 1963; 186:797-9.
11. Chou FF, Sheen-Chen SM, Chen YS, et al. Prognostic factors for pyogenic abscess of the liver. *J Am Coll Surg* 1994; 179:727-32.
12. Pitt HA, Zuidema GD. Factors influencing mortality in the treatment of pyogenic hepatic abscess. *Surg Gynecol Obstet* 1975; 140:228-34.
13. Chou FF, Sheen-Chen SM, Lee TY. Rupture of pyogenic liver abscess. *Am J Gastroenterol* 1995; 90:767-70.
14. Halvorsen RA, Korobkin M, Foster WL, Silverman PM, Thompson WM. The variable CT appearance of hepatic abscesses. *AJR Am J Roentgenol* 1984; 142:941-6.
15. Cohen JL, Martin FM, Rossi RL, Schoetz DJ Jr. Liver abscess. The need for complete gastrointestinal evaluation. *Arch Surg* 1989; 124:561-4.