

# Primary cutaneous cryptococcosis due to *Cryptococcus gattii* in Singapore

Lingegowda B P, Koh T H, Ong H S, Tan T T

## ABSTRACT

Cryptococcosis is an invasive fungal infection that occurs worldwide. Infections caused by *Cryptococcus (C.) neoformans* are commonly associated with immunocompromised patients, while those caused by *C. gattii* predominantly affect immunocompetent hosts. However, they have also been increasingly reported in immunocompromised patients such as those with HIV. Cutaneous involvement by *C. gattii* in immunocompetent patients is a rare manifestation, with only a few cases reported worldwide. *C. gattii* infection has rarely been reported in Singapore, with all three reported cases presenting as meningitis in immunocompetent individuals. Its natural habitat is the Eucalyptus tree, which is common in Singapore. We report the case of a 37-year-old migrant worker who had primary cutaneous infection due to *C. gattii* after sustaining traumatic inoculation.

**Keywords:** cryptococcosis, *Cryptococcus gattii*, immunocompetent patient, primary cutaneous infection

Singapore Med J 2011;52(7):e160-e162

## INTRODUCTION

Cryptococcal infection can affect any organ of the human body. Cutaneous involvement is the third most common after pulmonary and central nervous system (CNS) involvement. Currently, two species and four serotypes of *Cryptococcus (C.)* have been recognised. *C. neoformans* species complex comprises *C. neoformans* var. *grubii* (serotype A), *C. neoformans* var. *neoformans* (serotype D) and *C. gattii* species (serotype B and C). In most cases, the cutaneous lesions are attributable to haematogenous dissemination (i.e. secondary cutaneous cryptococcosis) by *C. neoformans*. However, rare cases of primary cutaneous cryptococcosis from direct inoculation or exposure, especially due to haematogenous dissemination are increasingly being reported and recognised. We report a case of primary cutaneous infection due to *C. gattii* following trauma in an immunocompetent patient. A total of seven cases of

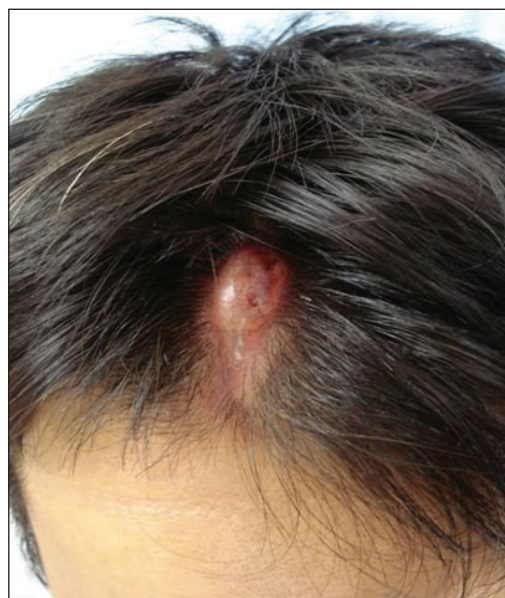

Fig. 1 Photograph shows a discharging nodule measuring 3 cm × 1 cm on the scalp.

cutaneous cryptococcosis due to *C. gattii* reported so far are reviewed.

## CASE REPORT

The patient was a 37-year-old Chinese man who worked as a forklift driver at a local port warehouse. He sustained a laceration to his scalp when a loose plank from a forklift pallet flipped as the wheels of his vehicle went over it. His wound was cleaned and the tissue glued together by a hair apposition technique of closure. However, a week later, the wound started to break down, and over the next two months, he presented to his general practitioner with pain and serous discharge. He was referred subsequently for wide excision of what was clinically a pyogenic granuloma. He reported being well previously, with no history of being immunocompromised. He had no risk factors for HIV infection, and the HIV serology performed was negative. The patient kept no pets and had not travelled outside Singapore since arriving here for work eight years ago. He denied the use of any traditional Chinese medications or local application of any folk medications to the non-healing lesion. He was otherwise asymptomatic.

Department of Infectious Diseases, Singapore General Hospital, Outram Road, Singapore 169608

Lingegowda BP, MBBS, MD Associate Consultant

Tan TT, MBBS, MRCP, PhD Consultant

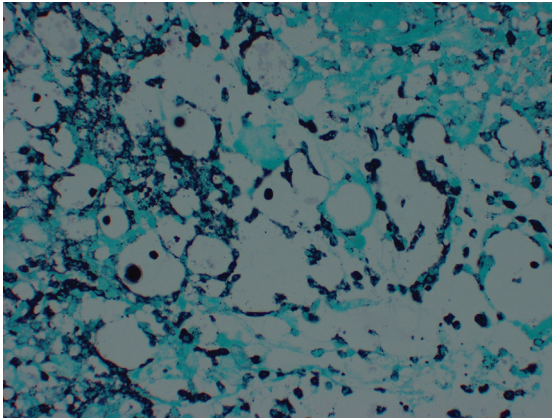
Department of Pathology

Koh TH, MBBS, DTM&H, FRCPA Senior Consultant

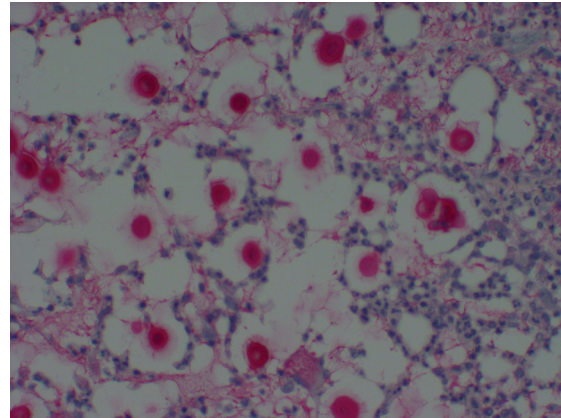
Department of General Surgery

Ong HS, MBBS, FRCSE Senior Consultant

**Correspondence to:** Dr Pushpalatha Bangalore Lingegowda  
Tel: (65) 6321 3479  
Fax: (65) 6227 5247  
Email: pushpalatha.bangalore.lingegowda@sgh.com.sg



**Fig. 2** Photomicrograph of the excised tissue shows the cell walls of *Cryptococcus* outlined by brown-to-black stains (Gomori methenamine stain,  $\times 400$ ).



**Fig. 3** Photomicrograph of the excised tissue shows the mucopolysaccharide capsule of *Cryptococcus* stained pink (Mucicarmine stain,  $\times 400$ ).

On physical examination, a few small cervical lymph nodes were palpable, together with a 3 cm  $\times$  1 cm discharging nodule on the patient's scalp. The scalp wound was non-healing just prior to excision (Fig. 1). The patient's full blood count and in particular, his total white blood cell count was normal. His electrolytes, liver function, CD4 count and chest radiograph were also normal. The fungal culture from the excised tissue grew *C. neoformans* var. *gattii*, and histology was positive for *Cryptococcus* (Figs. 2 & 3). Histopathological examination of the tissue revealed round, brown-to-black bodies with Gomori methenamine silver stain (Fig. 2), while *Cryptococcus* was stained pink with mucicarmine.

## DISCUSSION

The cutaneous infective manifestations of cryptococcosis are most often the result of dissemination from the lung. They usually occur in immunocompromised patients. These patients often have poor cell-mediated immunity (e.g. those with HIV infection), have had solid organ transplantation or require corticosteroids. Cutaneous cryptococcosis has rarely been reported in immunocompetent hosts. Several researchers have noted that *C. gattii* commonly cause infections in immunocompetent hosts.<sup>(1,2)</sup> The predominant clinical manifestations involve the lungs, followed by the CNS and less commonly, the skin.

In 2003, a group of French researchers reviewed 1,974 cases of cryptococcosis and found 28 patients with a distinct illness characterised by cutaneous inoculation and onset of local symptoms within a month of the trauma.<sup>(3)</sup> Most cases were due to *C. neoformans* var. *neoformans* (serotype D). The researchers proposed to recognise primary cutaneous cryptococcosis as a

distinct clinical entity. The evidence included absence of dissemination, solitary skin lesion on unclothed areas, lack of underlying disease, history of skin injury, participation in outdoor activities, exposure to bird droppings and isolation of *C. neoformans* serotype D.<sup>(3)</sup>

The first case of primary cutaneous cryptococcosis due to *C. gattii* in an immunocompetent individual was reported in a 75-year-old Australian man.<sup>(4)</sup> This yeast is endemic in Australia.<sup>(4)</sup> Only a handful of cutaneous *C. gattii* infections in immunocompetent hosts have been reported around the world.<sup>(4-10)</sup> Three cases partially fulfil the proposed criteria of primary cutaneous cryptococcosis.<sup>(4,5,10)</sup> Hamann et al reported a case of extensive cellulitis of the arm with no history of trauma. However, the authors noted that a trivial injury might have gone unnoticed since the patient was an orchid grower who used both his arms to mix potting material. Also, the categorisation of the case as immunocompetent has been questioned in view of the diagnosis of monoclonal gammopathy of unknown significance.<sup>(4)</sup> Lacaz et al reported a case of extensive ulceration on the forearm of a patient, which started as a macula, with no history of trauma preceding the lesion.<sup>(5)</sup> Tilak et al reported a case of cryptococcal meningitis with an antecedent non-healing ulcer of the great toe, which had been present for five months prior to the presentation of meningitis. The toe lesion has been documented as a boil that progressed to an ulcer, with no history of trauma.<sup>(10)</sup> In addition, four other reports also fit the description of secondary cutaneous cryptococcosis in immunocompetent individuals.<sup>(6-9)</sup> We support the observations of Xiujiiao et al that the presence of *C. neoformans* serotype D may not be a necessary condition for the diagnosis of primary cutaneous cryptococcosis.<sup>(8)</sup>

*C. gattii* has rarely been reported in Singapore. Two groups of researchers reported a total of three cases of meningitis in 2002.<sup>(11,12)</sup> This is despite the fact that Eucalyptus trees are common in Singapore. A recent report from neighbouring Malaysia indicates that *C. gattii* infection is not uncommon in this part of the world.<sup>(13)</sup> Also, recent analysis of publications on *Cryptococcus* confirmed the association of *C. gattii* with woody materials, and distinguished this species from *C. neoformans* niche in soil and pigeon droppings.<sup>(14)</sup> The differentiation of cryptococcal species can be accomplished on L-canavanine-glycine-bromothymol blue agar; *C. gattii* colours the medium blue, while *C. neoformans* does not (medium remains yellow). The reports and surveys suggest that *C. gattii* is likely to have wider global geographic distribution and is not restricted to tropical and subtropical regions. Hence, greater recognition of this infection, which could lead to traumatic skin lesions that are unresponsive to antibiotics in apparently healthy persons, is necessary. Also, the case reported by Tilak et al highlights the appreciation of the pathogenicity of *C. gattii*.<sup>(10)</sup> This case is unusual, in terms of both the finding of *C. gattii* in Singapore, as well as the route of infection.

#### ACKNOWLEDGEMENT

We would like to specially thank Dr Jacqueline Hwang Siok Gek for providing the histological slides.

#### REFERENCES

1. Chen S, Sorrell T, Nimmo G, et al. Epidemiology and host- and variety- dependent characteristics of infection due to *Cryptococcus neoformans* in Australia and New Zealand. *Clin Infect Dis* 2000; 31:499-508.
2. Berrie C. Outbreak of *Cryptococcus gattii* infection in humans in British Columbia, *Medscape Medical News*; 2007.
3. Neuville S, Dromer F, Morin O, et al. Primary cutaneous cryptococcosis: a distinct clinical entity. *Clin Infect Dis* 2003; 36:337-47.
4. Hamann ID, Gillespie RJ, Ferguson JK. Primary cryptococcal cellulitis caused by *Cryptococcus neoformans* var. *gattii* in an immunocompetent host. *Australas J Dermatol* 1997; 38:29-32.
5. Lacaz Cda S, Heins-Vaccari EM, Hernandez-Arriagada GL, et al. Primary cutaneous cryptococcosis due to *Cryptococcus neoformans* var. *gattii* serotype B, in an immunocompetent patient. *Rev Inst Med Trop Sao Paulo* 2002; 44:225-8.
6. Ridell RJ, Entwisle BR. Cryptococcal granulomata of the skin in a patient with pulmonary and cerebral cryptococcosis. *Australas J Dermatol* 1969; 10:100-8.
7. Severo LC, Berta-E-Zardo I, Londero AT. Cutaneous cryptococcosis due to *Cryptococcus neoformans* var. *gattii*. *Rev Iberoam Micol* 2001; 18:200-1.
8. Xiujiao X, Ai'e X. Two cases of cutaneous cryptococcosis. *Mycoses* 2005; 48:238-41.
9. Dora JM, Kelbert S, Deutschendorf C, et al. Cutaneous cryptococcosis due to *Cryptococcus gattii* in immunocompetent hosts: case report and review. *Mycopathologia* 2006; 161:235-8.
10. Tilak R, Prakash P, Nigam C, et al. Cryptococcal meningitis with an antecedent cutaneous Cryptococcal lesion. *Dermatol Online J* 2009; 15:12.
11. Taylor MB, Chadwick D, Barkham T. First reported isolation of *Cryptococcus neoformans* var. *gattii* from a patient in Singapore. *J Clin Microbiol* 2002; 40:3098-9.
12. Koh TH, Tan AL, Lo YL, Oh H. *Cryptococcus neoformans* var. *gattii* meningitis in Singapore. *Med Mycol* 2002; 40:221-3.
13. Tay ST, Rohani MY, Hoo TS, Hamimah H. Epidemiology of cryptococcosis in Malaysia. *Mycoses* 2010; 53:509-14.
14. Springer JD, Chaturvedi V. Projecting global occurrence of *Cryptococcus gattii*. *Emerg Infect Dis* 2010; 16:14-20.