

# Retinal changes in various altitude illnesses

Arora R, Jha K N, Sathian B

## ABSTRACT

**Introduction:** This study aimed to evaluate the retinal changes associated with altitude illness in young soldiers.

**Methods:** A total of 50 young soldiers with altitude illness, who were referred to a tertiary care hospital between October 2003 and January 2006, were included in the study.

**Results:** All the soldiers were male. The mean age of the subjects was 30.3 (range 20–44) years. Nine (18 percent) soldiers had acute mountain sickness (AMS), nine (18 percent) had high-altitude pulmonary oedema (HAPE) and 20 (40 percent) had high-altitude cerebral oedema (HACE). Retinal haemorrhages were observed in 29 soldiers (58 percent). Among these 29 cases, two also had symptoms of AMS, five had symptoms of HAPE and twelve had symptoms of HACE. High-altitude retinal haemorrhage alone as a sign of altitude illness was seen in ten cases. Severe grades of high-altitude retinopathy were found mostly in soldiers who suffered from HAPE and HACE. Visual recovery was complete in 22 (76 percent) soldiers. High-altitude retinal haemorrhage was associated with partial visual impairment in five (17 percent) soldiers and permanent visual loss in two (seven percent) soldiers.

**Conclusion:** Retinal haemorrhages were noticed in 58 percent of soldiers with altitude illness. The association of severe grades of high-altitude retinopathy with HAPE and HACE was statistically significant. Branch retinal vein occlusion with macular oedema is an additional finding in our study, which has not been previously reported

**Keywords:** altitude, cerebral oedema, pulmonary oedema, retinal haemorrhage

*Singapore Med J 2011; 52(9): 685–688*

## INTRODUCTION

Exposure to high altitude for varying durations is responsible for various health hazards, collectively known as altitude illness. Altitude illness involves four clinical entities: acute mountain sickness (AMS), high-altitude retinopathy (HAR), high-altitude pulmonary oedema (HAPE) and high-altitude cerebral oedema (HACE).<sup>(1)</sup> HAR is characterised by increased dilatation of the retinal veins and arteries, diffuse or punctate retinal haemorrhages usually located peripherally but occasionally in the macula, vitreous haemorrhages, papillary haemorrhages, cotton wool spots and papilloedema.<sup>(2-5)</sup> Inadequate autoregulatory response of the retinal vascular system is thought to be responsible for HAR.<sup>(6)</sup> The aim of the present study was to evaluate the retinal changes associated with altitude illness in young soldiers.

## METHODS

During the period October 2003 to January 2006, we studied 50 soldiers with altitude illness at a tertiary care hospital. Soldiers suffering from HAPE and HACE were admitted after initial treatment at a referral hospital near the place where illness occurred. This was a non-randomised and observational study. The inclusion criteria were soldiers posted at high altitudes (2,743 m above mean sea level [MSL]) for a duration of more than two weeks to one year, presentation with symptoms of altitude illness (namely, headache, insomnia, anorexia, lethargy, HAPE, HACE) and presentation with ocular manifestations due to high altitude (e.g. blurring of vision, scotoma, decreased visual acuity, changes in visual fields). Patients of altitude illness who had pre-existing hypertension, diabetes mellitus and Eales' disease were excluded from the study.

All patients underwent detailed history-taking and a physical examination. A complete ophthalmological examination, including best corrected visual acuity, anterior segment examination, applanation tonometry and a detailed dilated fundus examination (by +90 D and indirect ophthalmoscopy) were also undertaken. Fundus changes were graded according to Weidman's classification of HAR.<sup>(2)</sup> Fundus photography (Zeiss Fundus camera, Allied Vision Technologies GmbH, Stadroda, Germany), fundus fluorescein angiography

Department of  
Ophthalmology,  
Manipal College of  
Medical Sciences,  
Pokhara,  
Kaski 13402,  
Nepal

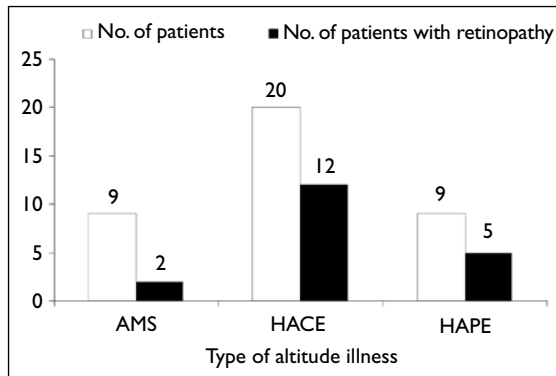
Arora R, DNB  
Lecturer

Jha KN,  
Professor

Department of  
Community  
Medicine

Sathian B, MD, PhD  
Assistant Professor

Correspondence to:  
Dr Reema Arora  
Tel: (977) 98 06641743  
Fax: (977) 61 526418  
Email: reemaoph@  
yahoo.com



**Fig. 1** Bar chart shows the incidence of retinal lesions in various types of altitude illness.

and automated perimetry (HFA 30-2, Carl Zeiss Meditech Inc, Dublin, CA, USA) were performed in all patients. In addition, the patients underwent ancillary investigations such as haemoglobin, total and differential leucocyte counts, complete blood count, erythrocyte sedimentation rate, haematocrit, blood sugar (fasting and postprandial), lipid profile, chest radiograph, electrocardiography and urine examination. Patients with HAPE and HACE underwent additional specific investigations such as echocardiography, computed tomography and magnetic resonance imaging of the brain. The patients were followed up for 12–18 months.

Patients were divided into four groups depending on the type of high-altitude illness, i.e. AMS, HAPE, HACE or HAR, and the incidence and severity of retinal haemorrhages were studied. Data was analysed using Excel 2003 (Microsoft Corporation, Redmond, WA, USA), Statistical Package for the Social Sciences Windows version 16.0 (SPSS Inc, Chicago, IL, USA) and the Windows Epi Info 3.5.1 version. The z-test was used to examine the statistical significance between the different variables. A p-value < 0.05 (two-tailed) was considered statistically significant. Odds ratio was also used to establish the statistical association.

## RESULTS

All patients were male and aged 20–44 (mean  $30.3 \pm 8$ ) years. Retinal haemorrhage was noted in 29 (58%) patients. Among the 50 patients seen, nine (18%) each had AMS and HAPE, and 20 (40%) had HACE. Out of the 29 patients with retinal changes, 19 had associated altitude illness (Fig. 1). In the remaining ten (20%) cases, the only evidence of altitude illness was high-altitude retinal haemorrhages (HARH) without any association. Two patients developed sudden-onset hypertension at high altitude. Among the 29 patients, two (7%) had Grade I, nine (31%) had Grade II, eight (28%) had Grade III and five (17%) had Grade IV retinal haemorrhage (Fig. 2).

**Table I. Severity of retinal haemorrhages in various altitude illnesses.**

Grade	No. of patients			
	AMS (n = 9)	HAPE (n = 9)	HACE (n = 20)	HAR (n = 10)
I	1	0	1	0
II	1	2	4	2
III	0	2	3	3
IV	0	1	3	1
BRVO with macular oedema	0	0	0	4
Post-neuritic optic atrophy	0	0	1	0
Retinal changes	2	5	12	10

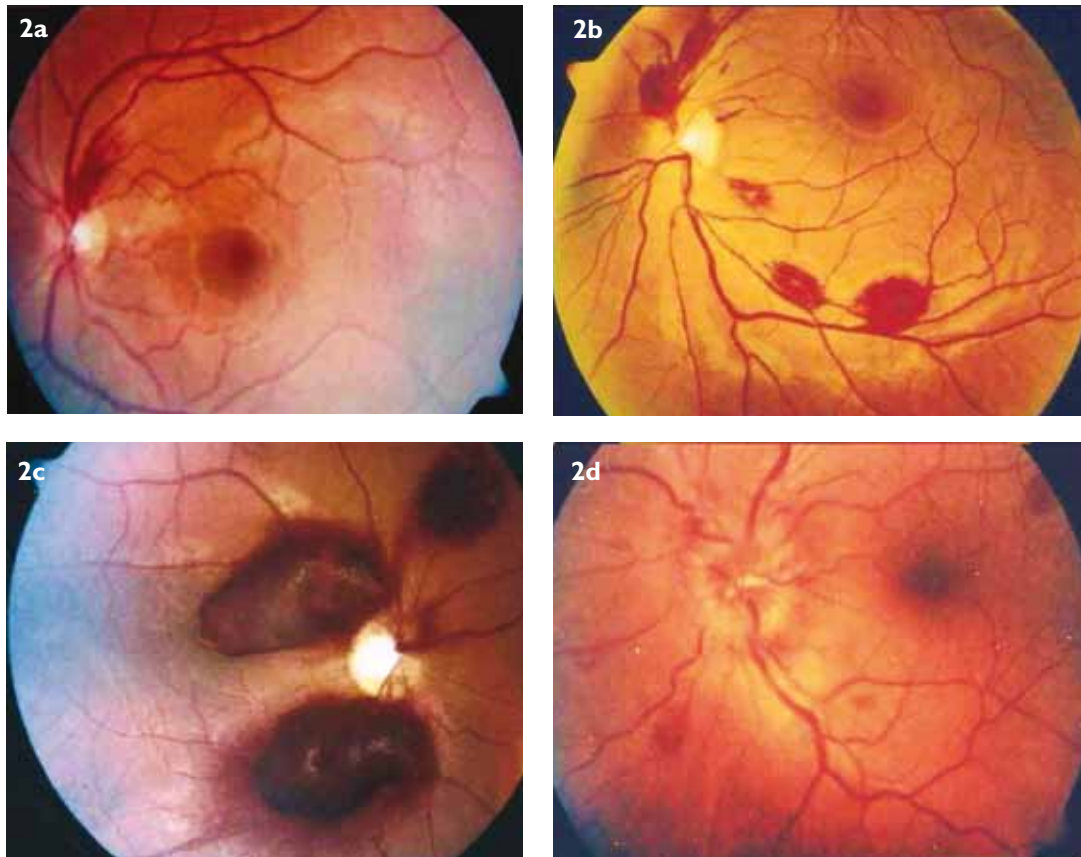
AMS: acute mountain sickness; HAPE: high-altitude pulmonary oedema; HACE: high-altitude cerebral oedema; HAR: high-altitude retinopathy; BRVO: branch retinal vein occlusion

Four patients had branch retinal vein occlusion (BRVO) with macular oedema in one eye (Fig. 3) and venous engorgement in the other eye, which was an additional finding that has not been previously reported. The remaining one patient had post-neuritic optic atrophy at presentation. Unilateral HARH was noted in 38% of the patients and bilateral HARH, in 62%.

The severity of retinal haemorrhages was significantly ( $p < 0.05$ ) greater in patients with HAPE and HACE than in those with AMS (Table I). 22 (75%) patients had full visual recovery by 12 weeks. Five (19%) patients (premacular haemorrhage = 2, BRVO with ischaemic maculopathy = 1, subhyaloid haemorrhage = 1, vitreous haemorrhage = 1) showed only partial visual recovery, even at 24 weeks. Two (6%) patients (one had post-neuritic optic atrophy and the other, occipital lobe infarct) showed no visual recovery at 24 weeks.

## DISCUSSION

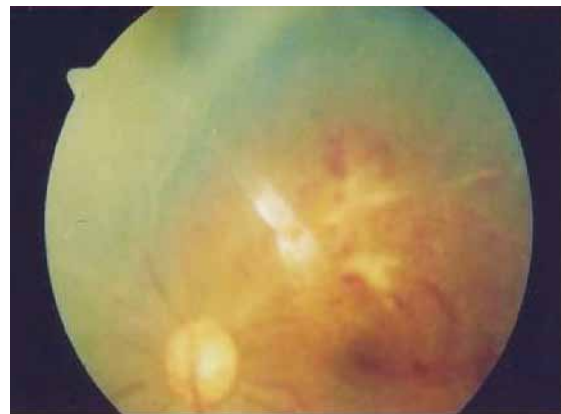HAR was first described by Singh et al, who noted retinal vasculature changes in 24 out of the 1,925 patients (1.3%) diagnosed with acute mountain sickness occurring between 11,000 ft (3,353 m) and 18,000 ft (5,486 m) above MSL.<sup>(7)</sup> Frayser et al observed retinal haemorrhages in nine out of 25 (36%) subjects at an altitude of 17,500 ft (5,334 m) above MSL.<sup>(8)</sup> Retinal haemorrhages at high altitude are more common in young and physically well-trained subjects.<sup>(9,10)</sup> This may be due to more dilated vessels and more systemic circulatory strain imposed on the retina during exercise in young patients. In our series of altitude illness, we observed retinal haemorrhages in 58% of patients. The relatively higher incidence of occurrence in this study is likely due to the young age of the soldiers posted at high altitude; 52% of the patients were



**Fig. 2** Fundus photographs show (a) Grade 1; (b) Grade 2; (c) Grade 3; and (d) Grade 4 high-altitude retinopathy according to the Weidman classification of high-altitude retinopathy.<sup>(2)</sup>

< 30 years of age, and this age group constituted 69% of HAR patients. However, this correlation between young age and HAR was not statistically significant ( $p > 0.05$ ).

Autoregulation of retinal vessels plays an important role in maintaining circulation in eyes that are exposed to chronic hypoxia.<sup>(6)</sup> Inadequate autoregulatory response of the retinal vascular system is thought to be responsible for HAR. As an individual ascends to more than 2,743 m above MSL, the fraction of oxygen in the atmosphere remains constant. Decrease in atmospheric pressure causes the partial pressure of oxygen to drop. This results in hypoxia, with the partial pressure of arterial oxygen decreasing from 95 mmHg at sea level to approximately 60 mmHg at 15,000 ft (4,572 m) above MSL.<sup>(11)</sup> This drop in oxygen available to meet the body's metabolic requirements initiates a host of physiological changes. Retinal blood flow has been shown to increase by 128% after four days at 5,300 m above MSL.<sup>(8)</sup> This causes a clinically observed increase in diameter and tortuosity of the retinal blood vessels and optic disc hyperaemia, which are seen in most individuals at high altitude and considered to be a normal response to high altitude.<sup>(12,13)</sup> Autoregulation of the retinal vessels is observable as vasodilatation during hypoxia, but choroidal vessels do not autoregulate and normally



**Fig. 3** Fundus photograph shows the left eye of a patient with superotemporal branch retinal vein occlusion with macular involvement.

operate at full flow capacity. These differences explain why preretinal haemorrhages occur more frequently than deeper haemorrhages.<sup>(14)</sup>

Increased haematocrit and haemoglobin concentrations often occur in high-altitude climbers.<sup>(15)</sup> Haemoconcentration causes increased blood viscosity, increased coagulability and decreased oxygen transport capacity. Local stasis caused by impaired microcirculation and local high blood pressure peaks may cause capillary

bursts.<sup>(12,16)</sup> Increased expression of nitric oxide or vascular endothelial growth factor has been observed to occur in the retina due to hypoxia caused by conditions such as diabetic retinopathy, central or BRVO and chronic obstructive airway diseases.<sup>(17,18)</sup> These conditions cause a breakdown of the inner retinal blood barrier, resulting in vasodilatation and increased vascular permeability. The same mechanism may be operating during hypoxia due to high altitude, producing changes like retinal venous dilatation, retinal haemorrhages, retinal oedema and cotton wool spots.

No sexual predilection in retinal haemorrhage has been found in any previous studies. All patients in the current study were male. The most common retinal manifestation reported was superficial haemorrhages.<sup>(3)</sup> The incidence and severity of retinal haemorrhage were found to be higher in associated illnesses like HAPE and HACE.<sup>(9)</sup> In the present study, superficial retinal haemorrhage (69%) was the most common manifestation, followed by premacular haemorrhages, vitreous haemorrhages and BRVO (10%–20%). The high incidence of retinal haemorrhages in our series may be due to the higher number of patients with severe altitude illness (HAPE [18%] and HACE [40%]) and the fact that our study was conducted at a referral centre. In the present study, a greater proportion of severe grade HAR were found in patients who suffered from HAPE and HACE. Papilloedema was found in 11% of HAPE and 15% of HACE cases. The association between higher prevalence and greater severity of retinal lesions in HAPE and HACE patients was statistically significant ( $p < 0.05$ ).

Four out of 29 patients (14%) had BRVO with macular oedema without any associated altitude illness, which was a finding that had never been reported. Among the four patients with BRVO, three showed full visual recovery at 12 weeks and one had partial visual recovery at 24 weeks. Although central retinal vein obstruction with vitreous haemorrhage<sup>(19)</sup> and unilateral anterior ischaemic optic neuropathy<sup>(20)</sup> has previously been described, BRVO with macular oedema has not. Butler et al reported decreased visual acuity without full recovery in only one of four patients of HARH.<sup>(19)</sup> McFadden et al noted minimal evidence of visually significant adverse effects.<sup>(3)</sup> The majority of patients in the present study showed full recovery. However, patients with severe lesions such as premacular haemorrhage and subhyaloid haemorrhage showed partial or no recovery.

HARHs occur more frequently in younger individuals who perform strenuous exercise at high

altitude. Its severity is significantly associated with illnesses like HAPE and HACE. As a majority of these patients show resolution of retinal lesions and recovery of visual acuity, visual symptoms alone are not an indication for urgent descent. However, in the event of progression or worsening of the symptoms, descent is mandatory.

## REFERENCES

- Houston CS. High altitude illness. Disease with protean manifestations. *JAMA* 1976; 236:2193-5.
- Wiedman M. Les hémorragies rétiniennes des sommets. *Concilium Ophthalmologium*, 22nd, 1974, Paris. 1975; 2:544-7.
- McFadden DM, Houston CS, Sutton JR, et al. High-altitude retinopathy. *JAMA* 1981; 245:581-6.
- Wiedman M. High altitude retinal haemorrhage. *Arch Ophthalmol* 1975; 93:401-3.
- Frayser R, Houston CS, Bryan AC, Rennie ID, Gray G. Retinal hemorrhage at high altitude. *N Engl J Med* 1970; 282:1183-4.
- Braun U, Braun M, Jonas JB. [High altitude retinopathy after Himalayan ascent]. *Klin Monbl Augenheilkd* 1997; 211:213-4. German.
- Singh I, Khanna PK, Srivastava MC, et al. Acute mountain sickness. *N Engl J Med* 1969; 280:175-84.
- Frayser R, Houston CS, Gray GW, Bryan AC, Rennie ID. The response of the retinal circulation to altitude. *Arch Intern Med* 1971; 127:708-11.
- Wiedman M, Tabin GC. High-altitude retinopathy and altitude illness. *Ophthalmology* 1999; 106:1924-6.
- Brinchmann-Hansen O, Myhre K, Sandvik L. Retinal vessel responses to exercise and hypoxia before and after high altitude acclimatisation. *Eye (Lond)* 1989; 3:768-76.
- West JB. Human physiology at extreme altitudes on Mount Everest. *Science* 1984; 223:784-8.
- Rennie D, Morrissey J. Retinal changes in Himalayan climbers. *Arch Ophthalmol* 1975; 93:395-400.
- Kobrick JL, Appleton B. Effects of extended hypoxia on visual performance and retinal vascular state. *J Appl Physiol* 1971; 31:357-62.
- Cusick PL, Benson OO, Boothby WM. Effects of anoxia and of high concentration of oxygen on the retinal vessels Preliminary report. *Proc Staff Meetings. Mayo Clinic*. 1948; 15:500-2.
- Zink RA, Schaffert W, Messmer K, Brendel W. Hemodilution: practical experience in high altitude expedition. In: Brendel W, Zink RA, eds. *High altitude physiology and medicine*. New York: Springer Verlag, 1982:291-7.
- Shults WT, Swan KC. High altitude retinopathy in mountain climbers. *Arch Ophthalmol* 1975; 93:404-8.
- Kaur C, Sivakumar V, Foulds WS. Early response of neurons and glial cells to hypoxia in the retina. *Invest Ophthalmol Vis Sci* 2006; 47:1126-41.
- Kaur C, Foulds WS, Ling EA. Blood-retinal barrier in hypoxic ischaemic conditions: basic concepts, clinical features and management. *Prog Retin Eye Res* 2008; 27:622-47.
- Bulter FK, Harris DJ Jr, Reynolds RD. Altitude retinopathy on Mount Everest, 1989. *Ophthalmology* 1992; 99:739-46.
- Bandyopadhyay S, Singh R, Gupta V, Gupta A. Anterior ischaemic optic neuropathy at high altitude. *Indian J Ophthalmol* 2002; 50:324-5.