

Cytomegalovirus colitis in immunocompetent patients

Momin N, Telisinghe P U, Chong V H

ABSTRACT

Cytomegalovirus (CMV) infection can present with severe manifestations that are associated with significant morbidity and mortality, especially in immunocompromised patients. CMV infections in immunocompetent patients are usually transient and do not exhibit many symptoms. However, in some patients, the manifestations can be severe. We report CMV colitis in two immunocompetent patients; one in a young man who was critically ill with septicaemia and significant non-bloody diarrhoea that responded to specific CMV treatment, and another in an elderly woman who presented with nonspecific abdominal pain and fever that resolved without specific CMV treatment.

Keywords: colitis, diarrhoea, gastrointestinal, immunocompetent

Singapore Med J 2011; 52(9): e170–e172

INTRODUCTION

Cytomegalovirus (CMV) infection causes severe diseases and significant morbidity and mortality in immunocompromised patients. In contrast, it typically runs a more benign course in immunocompetent individuals, who may remain asymptomatic or at most, experience an infectious mononucleosis-like syndrome.⁽¹⁾ The less common but significant manifestations include colitis, meningitis, encephalitis, transverse myelitis, Guillain-Barré syndrome, haemolytic anaemia, thrombocytopenia, thrombosis of the venous or arterial vascular system, uveitis, pericarditis, myocarditis and pneumonitis.^(1,2) Significant complications can result in death and chronic disability. We present CMV colitis in two immunocompetent patients who manifested significant diarrhoea requiring treatment and self-limiting, nonspecific abdominal pain.

CASE REPORT

Case 1

A previously healthy 29-year-old Malay man was admitted with acute confusional state. This was preceded by a week-long history of cough, fever, chills

and anorexia. He had also experienced intermittent headaches and abdominal pain over the past two months. On admission, the patient appeared unwell and had chickenpox-like vesicular skin rash. He was tachycardic (heart rate 157 beats per minute [bpm]), and his blood pressure was 107/77 mmHg. Random glucose level was high (28.9 mmol). Blood investigations showed mild microcytic anaemia (haemoglobin 12.7 g/dL, mean corpuscular volume 66.6 fL), leucocytosis ($18.1 \times 10^9/L$) with neutrophilia (90%) and thrombocytopenia ($35 \times 10^9/L$). His clotting profile was deranged, with an international normalised ratio of 1.4. He had renal impairment (creatinine 210 $\mu\text{mol/L}$), and his liver function tests were also deranged, with a total bilirubin of 16 $\mu\text{mol/L}$, alanine aminotransferase 230 U/L, alkaline phosphatase 165 U/L and gamma-glutamyltransferase 55 U/L. He was also found to have hypoalbuminaemia (21 g/L).

The patient was treated for septic shock, chickenpox and disseminated intravascular coagulopathy. He was admitted to the intensive care unit (ICU), where he was intubated and put on ventilation, and then started on inotropic support. Broad-spectrum intravenous (IV) meropenem (1 g tid) and acyclovir (800 mg qid) were started. The Dermatology Consult also suspected disseminated chickenpox. Interestingly, the aspirate of vesicles and blood cultures isolated *Burkholderia pseudomallei*. The antibiotics were changed to our first-line regime of co-amoxiclav (1.2 g tid) and ceftazidime (2 g tid). As the patient's improvement was slow, computed tomography (CT) of the abdomen and thorax was done, which revealed multiple abscesses; one right liver lobe abscess and multiple abscesses within the spleen and lungs. None of the abscesses were suitable for drainage.

The patient's stay in the ICU was complicated by hydropneumothorax that required the insertion of a chest drain. He subsequently developed large volume diarrhoea (>5 L per day) two weeks into his ICU admission. Multiple stool evaluations were negative for *Clostridium difficile* A and B toxins and other organisms. Colonoscopy revealed macroscopic features of pseudomembranous colitis, but biopsy showed nonspecific inflammation. Empirical metronidazole therapy and other therapies, including octreotide, loperamide and cholestyramine, failed to

Gastroenterology Unit,
Department of Medicine,
Raja Isteri Pengiran Anak Saleha Hospital,
Bandar Seri Begawan,
BA 1710,
Brunei Darussalam

Momin N, MBBS,
MRCP
Senior Medical Officer

Chong VH, MRCP,
FAMS, FRCP
Consultant

Department of Pathology

Telisinghe PU,
MBBS, FRCP
Consultant

Correspondence to:
Dr Chong Vui Heng
Tel: (673) 877 8218
Fax: (673) 224 2690
Email: chongvuih@yahoo.co.uk

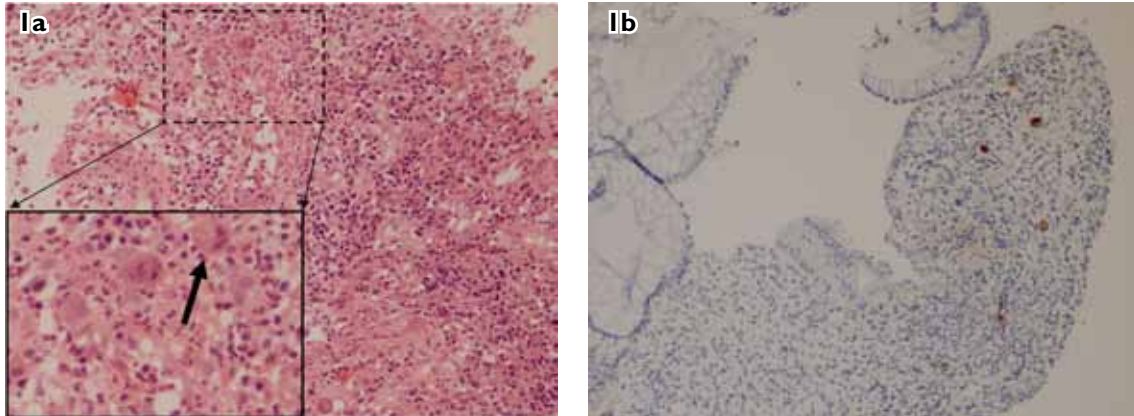


Fig. 1 Photomicrographs of colonic biopsy show (a) acute inflammatory infiltrate and a cytomegalovirus (CMV) inclusion body (Cowdry body, arrow) (Haematoxylin & eosin, $\times 10$; insert $\times 20$); and (b) Cowdry body (Immunoperoxidase staining, $\times 10$).

resolve the diarrhoea. Repeat CT showed resolution of the abscesses. At this point, opportunistic infection was suspected. Upper gastrointestinal endoscopy was unremarkable, apart from a cervical inlet patch. Duodenal aspirates isolated *Klebsiella* spp. and *Candida* spp. Repeat colonoscopy showed diffuse colitis, and random biopsies were taken to exclude CMV colitis. On this occasion, however, histology confirmed the suspicion of CMV colitis (Fig. 1). HIV serology was non-reactive. IV ganciclovir was started at 5 mg/kg twice daily for 14 days, and the patient exhibited marked clinical improvement. Eventually, he was able to tolerate oral feeding and was discharged from the ICU. Unfortunately, he was re-admitted to the ICU later with multiresistant *Acinetobacter* pneumonia and multi-organ failure. The patient died three months after admission.

Case 2

A 61-year-old previously healthy Malay woman was admitted with a week-long history of cough that was productive of white sputum, along with left iliac fossa pain, constipation, vomiting, fever and anorexia. On admission, she was febrile (38°C), dehydrated and tachycardic (heart rate 120 bpm). Her blood pressure was 150/72 mmHg and her abdomen was distended, with tenderness in the left iliac fossa. The rest of the examination was unremarkable. Blood investigations showed leucocytosis ($13.7 \times 10^9/\text{L}$) with neutrophilia (80%), mild hyponatraemia (130 mmol/L) and hypokalaemia (2.7 mmol/L). The liver profile and random blood glucose level were normal. Abdominal radiography showed faecally loaded colon and dilated transverse colon. Ultrasonography revealed multiple gallstones and a cortical cyst in the left kidney.

The patient was started empirically on IV cefuroxime (1.5 g tid) and IV metronidazole (500 mg tid). Over the next few days, she remained febrile and her abdominal

pain persisted. Her antibiotics were later changed to IV ciprofloxacin (200 mg bid). Blood and urine cultures were negative. Colonoscopy showed inflamed rectal mucosa, polyps and multiple diverticuli in the sigmoid, with surrounding inflamed mucosa (Fig. 2). The mucosa of the proximal descending colon and splenic flexure was ulcerated and nodular. Ischaemic colitis was suspected. However, her biopsy showed changes that were typical of CMV colitis. HIV serology test was non-reactive. The patient's symptoms improved without treatment for CMV. She declined a repeat colonoscopy, and CT did not reveal any abnormalities in the colon. She remained well during follow-up.

DISCUSSION

Clinically significant CMV-related disease among immunocompetent hosts is uncommon. However, seroprevalence studies for CMV among adult populations have shown that the rate of infection ranges from 40% to 100%.^(1,3) Most of these infections occur during childhood. This suggests that subclinical or mild primary infections are common. Reactivation of latent infection is less common, and apart from those associated with immunosuppressant therapies and immunodeficiency (congenital or acquired), is usually associated with the development of systemic immunosuppression from underlying severe illnesses. Immunocompetent patients with critical illness in the ICU setting have been shown to be at higher risk, with a rate of proven active CMV infection as high as 36%.^(1,4) Important risk factors include positive CMV serology, ICU stay lasting five days or more, severe sepsis, disease severity and duration of ventilation.^(2,4,5) Our first patient had at least three risk factors, whereas the second did not have any risk factors at all.

The gastrointestinal tract is one of the most commonly affected systems, especially the colon.⁽²⁾ CMV colitis has been described in different age groups, ranging from the

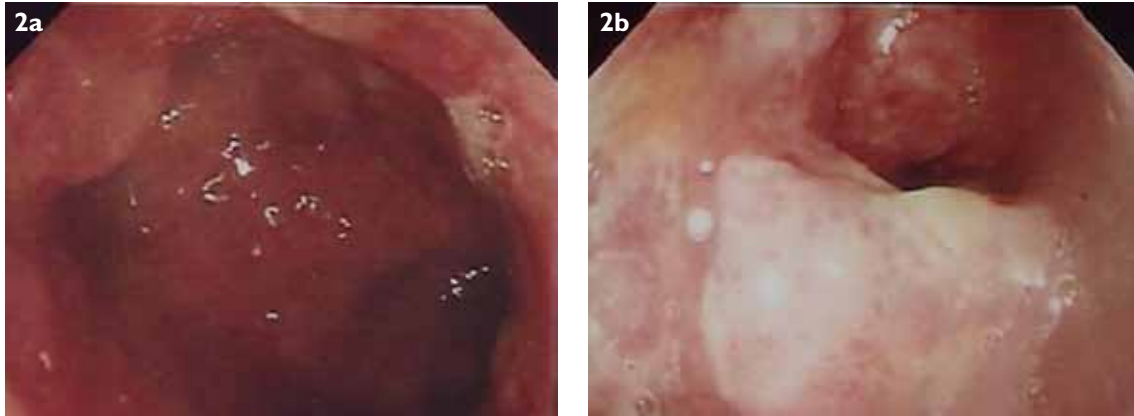

Fig. 2 Endoscopic images show (a) friable ulcerated colonic mucosa; and (b) stenosis.

very young (five-week-old infant)⁽⁶⁾ to young adults⁽⁷⁾ and the elderly.⁽⁸⁾ The reason for the predilection of the colon is unknown. The presence of underlying mucosa pathology such as inflammatory bowel disease has been reported to be a risk factor.⁽⁹⁾ None of our patients had any underlying colonic disorders. Clinical manifestations of CMV colitis are similar to other infective causes, with diarrhoea, fever and abdominal pain predominating. In one study, 53% of the patients with diarrhoea had bloody stools and another 20% had positive occult blood testing.⁽¹⁾

CMV infections in immunocompetent ICU patients have been associated with poor outcomes.⁽¹⁰⁾ Therefore, CMV-related diseases, including colitis, need to be treated, especially among severely ill patients. Early diagnosis and appropriate treatment are essential. Our first patient recovered with specific CMV treatment despite a delay in diagnosis. Interestingly, our second patient recovered without any specific CMV treatment. Spontaneous remission of clinically significant CMV infections has been known to happen. Approximately one-third of patients have reportedly recovered without any treatment for CMV infection.⁽¹¹⁾ This group of patients may represent a segment of individuals who are in the middle of a spectrum, where at one end, the disease is very mild or asymptomatic and at the other end, the manifestations are severe and associated with significant mortality.

Our two cases highlight that the manifestations and endoscopic findings of CMV infections can resemble other common conditions. Endoscopic findings in our patients were consistent with pseudomembranous and ischaemic colitis. These are not unexpected, given the medical condition and age of our patients. Therefore, a high index of suspicion is important, and adequate biopsies and serological studies are vital for early diagnosis.

In conclusion, our two cases present a rare cause of colitis in immunocompetent individuals, and highlight the need to consider CMV colitis as a cause for unexplained diarrhoea and other abdominal symptoms in immunocompetent patients who are critically ill, mildly symptomatic, or have symptoms resembling commonly encountered conditions.

REFERENCES

1. Friel TJ. Epidemiology, clinical manifestations, and treatments of cytomegalovirus infection in immunocompetent hosts. In: UpToDate February 2010 [online]. Available at: www.uptodate.com/contents/epidemiology-clinical-manifestations-and-treatment-of-cytomegalovirus-infection-in-immunocompetent-hosts. Accessed April 15, 2010.
2. Rafailidis PI, Mourtzoukou EG, Varbobitis IC, Falagas ME. Severe cytomegalovirus infection in apparently immunocompetent patients: a systematic review. *Virology* 2008; 5:47.
3. Staras SA, Dollard SC, Radford KW, et al. Seroprevalence of cytomegalovirus infection in the United States, 1988-1994. *Clin Infect Dis* 2006; 43:1143-51.
4. Kalil AC, Florescu DF. Prevalence and mortality associated with cytomegalovirus infection in nonimmunosuppressed patients in the intensive care unit. *Crit Care Med* 2009; 37:2350-8.
5. Jaber S, Chanques G, Borry J, et al. Cytomegalovirus infection in critically ill patients: associated factors and consequences. *Chest* 2005; 127:233-41.
6. Jonkhoff-Slok TW, Veenhoven RH, de Graeff-Meeder ER, Büller HA. An immunocompetent infant with cow's milk allergy and cytomegalovirus colitis. *Eur J Pediatr* 1997; 156:528-9.
7. Blair SD, Forbes A, Parkins RA. CMV colitis in an immunocompetent adult. *J R Soc Med* 1992; 85:238-9.
8. Lockwood MR, Liddle J, Kitsanta P. Cytomegalovirus colitis--an unusual case for diarrhoea in an elderly woman. *Age Ageing* 2006; 35:198-200.
9. Kandiel A, Lashner B. Cytomegalovirus colitis complicating inflammatory bowel disease. *Am J Gastroenterol* 2006; 101:2857-65.
10. Osawa R, Singh N. Cytomegalovirus infection in critically ill patients: a systematic review. *Crit Care* 2009; 13:R68.
11. Galiatsatos P, Shrier I, Lamoureux E, Szilagyi A. Meta-analysis of outcome of cytomegalovirus colitis in immunocompetent hosts. *Dig Dis Sci* 2005; 50:609-16.