

Use of radiosynovectomy in recurrent warfarin-related haemarthrosis in degenerative arthritis

Tan Y K, Lai H K, Chong Y Y

ABSTRACT

Radiosynovectomy is a local and minimally invasive radiotherapy for treating various chronic inflammatory arthritis such as rheumatoid arthritis, osteoarthritis and haemophilic arthropathy. In haemophilic arthropathy, it reduces the frequency of haemarthrosis and delays the development of severe joint destruction, which ultimately requires surgical intervention. Its role in warfarin-related haemarthrosis is less clear. Haemarthrosis is an uncommon complication of warfarin use, and anticoagulation may need to be discontinued. We describe yttrium-90 radiosynovectomy use in a 74-year-old man with underlying ischaemic heart disease, atrial fibrillation, previous embolic stroke and recurrent haemarthrosis of an osteoarthritic right knee. Anticoagulation was vital and could not be permanently stopped. Due to continuing anticoagulation, he had multiple hospitalisations with recurrent right knee haemarthrosis. Intraarticular right knee yttrium-90 citrate colloid injection led to a cessation of haemarthrosis for eight months. We examined the available literature for the role of radiosynovectomy in such circumstances.

Keywords: arthritis, haemarthrosis, radiosynovectomy, warfarin

Singapore Med J 2011; 52(9): e184–e186

INTRODUCTION

Radiosynovectomy (RSV) is a technique of local and minimally invasive radiotherapy, which was first performed by Fellinger et al in 1952.⁽¹⁾ It was originally used to ameliorate pain and inflammation in the treatment of refractory synovitis in rheumatoid arthritis. It is useful as an alternative treatment modality to surgical synovectomy. In addition, data regarding its use in various forms of joint disorders, for example, in patients with knee osteoarthritis and in haemophiliacs, has also been published.⁽²⁻⁵⁾ In the latter group, prophylactic

administration of clotting factors may be unsuccessful in preventing further haemarthrosis, especially in the presence of clotting factor inhibitors. RSV may be useful in such difficult clinical scenarios; it can reduce the recurrence of haemarthrosis and the development of severe joint damage, which could ultimately lead to major surgical intervention.⁽⁶⁾

RSV involves the injection of a radionuclide in colloidal form into the joint space. The type of radionuclide utilised depends on the joints involved, as well as the emitting energy, the half-life and the penetration depth of the emitted radiation of the radionuclide used in the treatment.⁽¹⁾ The commonly used colloidal radionuclides are yttrium-90 silicate/citrate, rhenium-186 sulfide and erbium-169 citrate.

Spontaneous haemarthrosis is unusual in non-haemophilic patients on anticoagulation, occurring with a frequency of 0.15 per 100 patient-years of treatment.⁽⁷⁾ Although bleeding episodes can quickly be reversed with withdrawal of anticoagulation, this is not possible in all cases. There is a paucity of literature on the use of RSV in anticoagulation-induced haemarthrosis, specifically warfarin-related recurrent haemarthrosis. We describe the use of RSV in a patient on anticoagulation with recurrent right knee haemarthrosis.

CASE REPORT

The patient was a 74-year-old Chinese man with a previous history of ischaemic cardiomyopathy, coronary artery bypass graft surgery, atrial fibrillation and embolic stroke, from which he had fully recovered. He presented with a two-day history of acute pain in the right knee and swelling without any trauma or knee injuries. Physical examination showed swelling in the right knee with a tense suprapatellar knee effusion. Knee aspiration yielded 40 ml of frank haemarthrosis. Joint fluid analysis showed an absence of birefringent crystals on polarising microscopy, and fluid cultures were sterile. Laboratory investigations showed a haemoglobin of 12.7 g/dl (normal range [NR] 14–18 g/dl), total white blood count of $11.52 \times 10^9/L$ (NR 4–10 $\times 10^9/L$), with slight neutrophilia of 82% (NR 40%–75%) and a normal

Department of Rheumatology and Immunology, Singapore General Hospital, Outram Road, Singapore 169608

Tan YK, MBBS, MMed, MRCP Registrar

Raffles International Medicine centre, 585 North Bridge Road, #02-00, Raffles Hospital, Singapore 188770

Chong YY, MBBS, MMed, MRCP Consultant

Nuclear Medicine and PET Centre, Department of Diagnostic Radiology, Mount Elizabeth Hospital, 3 Mount Elizabeth, Singapore 228510

Lai HK, MBChB, MRCP, FAMS Consultant

Correspondence to: Dr Tan York Kiat
Tel: (65) 9631 8628
Fax: (65) 6220 7765
Email: yorkkiat@yahoo.com.sg

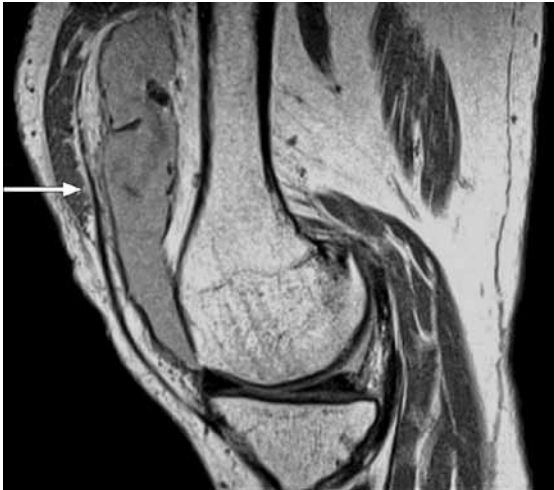

Fig. 1 MR image of the right knee shows large joint effusion at the suprapatellar recess, demonstrating a fluid-fluid level (arrow) due to layering of blood.

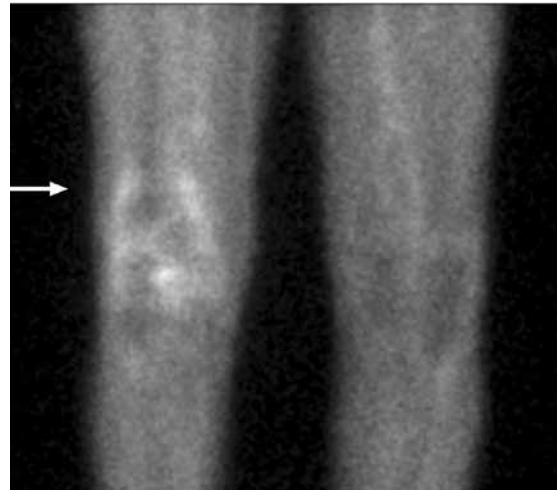


Fig. 2 TC-99m MDP triphasic bone image of both knees shows increased tracer accumulation in the right knee at the blood pool phase (arrow).

platelet count of $177 \times 10^9/L$ (NR 140–440 $\times 10^9/L$). His erythrocyte sedimentation rate was elevated at 34 mm in the first hour (NR 1–10 mm/hr). His international normalised ratio (INR) was 1.91.

Plain radiograph of the right knee showed no osteochondral lesion. Magnetic resonance imaging (Fig. 1) revealed a large joint effusion at the suprapatellar recess, demonstrating a fluid level that was consistent with haemarthrosis. There was severe chondrosis at the patellofemoral joint, with almost complete cartilage denudation at the patellar articular surface. The medial trochlear cartilage was also denuded with fissures that were present at the lateral trochlear cartilage. There was no evidence of marrow oedema to suggest recent contusion, and the ligaments were all intact. A horizontal oblique inferior surfacing tear was observed at the junction of the posterior horn and body of the medial meniscus, but it was not considered to account for the degree of right knee haemarthrosis.

The patient was initially treated conservatively with rest and pressure bandage. He sustained two more similar episodes of knee haemarthrosis when warfarin intake was resumed. Anticoagulation could not be stopped in view of his atrial fibrillation and previous embolic stroke. A subsequent decision was made to reduce the intensity of anticoagulation to achieve an INR of 1.7–2.2. Despite maintaining his INR at ≤ 2.0 , the patient was hospitalised three more times over the next two months for recurring problem of right knee haemarthrosis. He did not respond to the conservative therapy of pressure bandage or intra-articular steroid injection. A decision was made for RSV to control his recurrent haemarthrosis. A triphasic bone scintiscan of the knees was performed prior to RSV, which demonstrated features consistent with an

inflammatory process in the right knee joint (Fig. 2). A 126-MBq dose of yttrium-90 citrate colloid was injected into the patient's right knee. A bremsstrahlung whole body imaging performed 23 hours after administration of the yttrium-90 citrate colloid showed focal tracer accumulation in the right knee joint, with no extravasation of the colloid. Warfarin was then successfully restarted. The patient had no further haemarthrosis for the next eight months despite being on warfarin. Target INR was raised to 2.5. When he again presented with similar right knee haemarthrosis (corresponding INR 3.32), a repeat RSV was scheduled; unfortunately, he succumbed to an acute coronary event in the hospital.

DISCUSSION

We describe the case of a man with recurrent warfarin-related haemarthrosis of the right knee, which responded favourably to RSV. He was asymptomatic for eight months after the RSV, despite being on treatment for anticoagulation. When he presented again with the same problem, we predicted that he may further benefit from a second course of RSV.

The pathogenesis of synovitis in haemarthrosis associated with warfarin use is not well understood. In haemophilic synovitis, it was postulated to be secondary to synovial proliferation and the thickening that follows phagocytosis of intra-articular erythrocytes. This proliferated and thickened synovial tissue is highly vascular. Being impinged between joint surfaces, the synovial tissue can be subjected to a perpetuated cycle of continual bleeding and inflammation.⁽⁸⁾

Yttrium-90 citrate colloid is one of the commonly used colloidal radionuclides in RSV for knee joints. Yttrium-90 has a half-life of 2.7 days, and emits pure

beta radiation with a mean energy of 0.94 MeV and a mean penetration depth of 3.6 mm in soft tissue.⁽¹⁾ These physical properties of yttrium-90 allow for adequate radiation to the thickened and inflamed synovium, without exposing the knee joint and the adjacent tissue to excessive and prolonged radiation. In RSV, the radioactive colloidal particles are phagocytised by the synovium and by emitting local radiation to the synovial tissue. As a result of the irradiation, the synovial membrane in our patient became fibrotic and sclerotic. This leads to cessation of the inflammation as well as occlusion of the superficial capillaries in the synovium.⁽⁹⁾

There is a paucity of data on the use of RSV for warfarin-related haemarthrosis. We found only two patients described by Croot and Winfield in 2000.⁽¹⁰⁾ The first patient was a 77-year-old man, whose indication for anticoagulation was underlying atrial fibrillation and valvular heart disease. He had recurrent haemarthrosis despite tight control of his INR. Finally, after two sessions of RSV two months apart, he experienced no further bleeding for the next three years. The second patient was a 59-year-old man with seronegative inflammatory arthritis and ulcerative colitis. He was anticoagulated for intracardiac thrombus, which required his INR to be > 3.5 so as to prevent multiple episodes of transient ischaemic attacks. He was hospitalised for several weeks for recurrent left knee haemarthrosis, which was controlled with a single RSV.⁽¹⁰⁾ To our knowledge, our patient is the third case in which RSV successfully controlled the recurrent haemarthrosis for a period of time. As discontinuing the intake of warfarin was not an option, RSV brought a definite improvement to the quality of life in our patient.

RSV is used in chronic inflammatory arthritis such

as rheumatoid arthritis and osteoarthritis. It is also a well-established method in the management of recurrent haemarthrosis in haemophilia. Although recurrent haemarthrosis from warfarin use is uncommon, it can be both disabling to the patient and frustrating for the managing physicians when withdrawal of warfarin is not desirable. RSV is a feasible option in the management of such patients.

REFERENCES

1. Schneider P, Farahati J, Reiners C. Radiosynovectomy in rheumatology, orthopedics, and hemophilia. *J Nucl Med* 2005; 46 Suppl 1:48S-54S.
2. Markou P, Chatzopoulos D. Yttrium-90 silicate radiosynovectomy treatment of painful synovitis in knee osteoarthritis. Results after 6 months. *Hell J Nucl Med* 2009; 12:33-6.
3. Bridgman JF, Bruckner F, Bleehen NM. Radioactive yttrium in the treatment of rheumatoid knee effusions. Preliminary evaluation. *Ann Rheum Dis* 1971; 30:180-2.
4. Rozeboom S, Dörr U, Bihl H. [Radiosynovectomy for the treatment of rheumatoid arthritis of the elbow joint]. *Nuklearmedizin* 2001; 40:91-7. German.
5. Dawson TM, Ryan PF, Street AM, et al. Yttrium synovectomy in haemophilic arthropathy. *Br J Rheumatol* 1994; 33:351-6.
6. Rodriguez-Merchan EC, Wiedel JD, Wallny T, et al. Elective orthopaedic surgery for inhibitor patients. *Haemophilia* 2003; 9:625-31.
7. Palareti G, Leali N, Coccheri S, et al. Bleeding complications of oral anticoagulant treatment: an inception-cohort, prospective collaborative study (ISCOAT). Italian Study on Complications of Oral Anticoagulant Therapy. *Lancet* 1996; 348:423-8.
8. Silva M, Luck JV, Llinas A. Chronic Haemophilic Synovitis: The role of Radiosynovectomy. Montreal, Canada: World Federation of Haemophilia, 2004; 33 [online]. Available at: www.wfh.org/2/docs/Publications/Musculoskeletal_Physiotherapy/TOH-33_English_Synovectomy.pdf. Accessed March, 2010.
9. Kampen WU, Voth M, Pinkert J, Krause A. Therapeutic status of radiosynoviorthesis of the knee with yttrium [90Y] colloid in rheumatoid arthritis and related indications. *Rheumatology (Oxford)* 2007; 46:16-24.
10. Croot LM, Winfield J. Radiation synovectomy for warfarin-induced haemarthrosis. *Rheumatology (Oxford)* 2000; 39:570-1.