

# Colonic perforation caused by direct trauma during computed tomographic colonography performed via end colostomy

Teo J Y, Low O W, Ho K S

## ABSTRACT

We report the case of a woman with a history of abdominoperineal resection for cancer, who had an inadvertent perforation during screening computed tomographic colonography performed via end colostomy. Revision of the stoma was promptly performed, which prevented a full laparotomy. We reviewed the literature on the subject and found that such perforations may be more common than previously thought. With appropriate precautions, such occurrences can be minimised in the future.

**Keywords:** complications, computed tomographic colonography, perforation, virtual colonoscopy

*Singapore Med J 2011; 52(12): e248-e250*

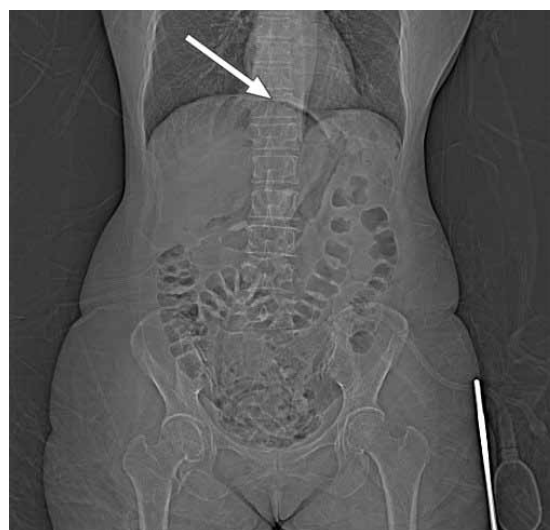## INTRODUCTION

Computed tomographic colonography (CTC) has been advocated as a safer alternative to colonoscopy for screening colorectal lesions. We present the first documented case of a colonographic perforation that occurred via direct trauma during intubation of an end colostomy. The management of this case and a review of the relevant literature are presented.

## CASE REPORT

A 59-year-old Chinese woman with a history of abdominoperineal resection for rectal cancer 28 years ago was scheduled for CTC. A previous attempt at colonoscopy screening five years earlier via end colostomy had failed due to acute colonic angulation, likely caused by intraperitoneal adhesions. A barium enema had also failed, as the barium could not be retained. Eventually, CTC was successfully performed, and the outcome was reported as normal.

A mechanical bowel preparation was administered the day before CTC was performed. The end colostomy was intubated with a 24F Foley catheter, but some resistance was encountered. The catheter



**Fig. 1** Prone scanogram shows a poorly distended colon and the presence of pneumoperitoneum (arrow).

was subsequently withdrawn and replaced with a 16F catheter that was inflated with 10 ml of air. The initial supine scanogram performed after insufflation with a small amount of air showed suboptimal distension of the colon. Subsequent insufflation of the colon was performed manually with 2 L of air, and the prone scanogram showed the presence of free gas within the peritoneal cavity (Fig. 1). Supine computed tomography (CT) was performed to document the site of perforation. Although the patient did not experience any pain, the images revealed gross pneumoperitoneum and that the catheter balloon had been inflated within the peritoneal cavity just below the abdominal wall (Fig. 2).

The referring surgeon was immediately notified. Intravenous antibiotics were started and the Foley catheter was left *in situ* in order to provide a tamponade effect and to help identify the site of perforation. The patient was immediately taken to the operating theatre. Intraoperatively, the stoma was first taken down via an elliptical peristomal incision. The Foley catheter had exited the colonic wall at an oblique angle, resulting in a 2 cm × 4 cm defect. No soilage was observed. The

Department of  
General Surgery,  
Singapore General  
Hospital,  
Outram Road,  
Singapore 169608

Teo JY, MBBS,  
MRCSE  
Registrar

Low OW, MBBS  
House Officer

Department of  
Colorectal Surgery

Ho KS, MBBS,  
MMed, FRCSE  
Senior Consultant

**Correspondence to:**  
Dr Teo Jin-Yao  
Tel: (65) 6321 4051  
Fax: (65) 6220 9323  
Email: the\_gentleman82  
@hotmail.com

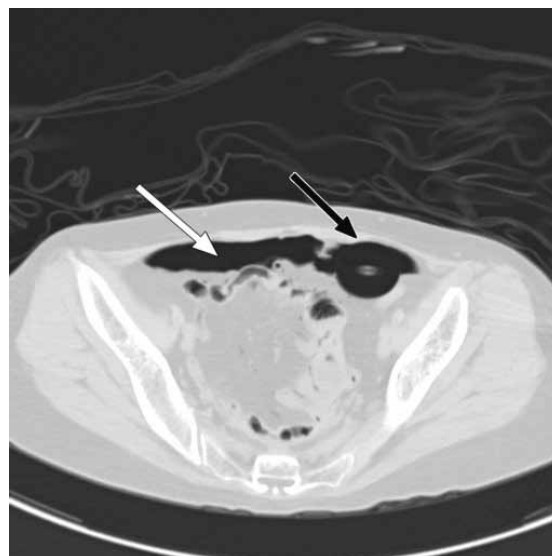
colon was noted to have descended into the pelvis, where there were dense adhesions, before looping back up to the left hypochondrium. A transection of the colon was performed just proximal to the site of perforation and the stoma refashioned. The patient was maintained on intravenous antibiotics postoperatively and made an uneventful recovery. She was discharged on postoperative Day 5.

## DISCUSSION

CTC was first described in 1994 by Vining et al.<sup>(1)</sup> Since then, its use has become more widespread as a screening tool, either as a first-line modality or when conventional fibre-optic colonoscopy has been unsuccessful. Although originally touted as a rapid, non-invasive and safer alternative that could potentially replace fibre-optic colonoscopy, two cases of CTC-associated perforation were first reported in the literature in 2004.<sup>(2,3)</sup> Since then, perforation during CTC has become a well-recognised complication of the procedure, with a perforation rate of 0.05% reported in the two largest multicentre series to date.<sup>(4,5)</sup> This is comparable to the perforation rate of conventional colonoscopy, which has been estimated to be 0.03%–0.65% for diagnostic and 0.07%–2.14% for therapeutic colonoscopies.<sup>(6–10)</sup> However, many CTC perforations are asymptomatic and can be treated conservatively. In fact, the authors of a UK survey on CTC opined that many of these asymptomatic perforations represent microperforations that are picked up ‘incidentally’ due to the high sensitivity of CT for detecting pneumoperitoneum. They further stated that when comparing CTC to conventional colonoscopy, the symptomatic perforation rate of CTC, which is 0.03%, should be quoted instead.<sup>(4)</sup>

CTC perforations are commonly attributed to the presence of previously undiagnosed obstructing lesions (e.g. stricture or tumour), bowel wall abnormalities (e.g. diverticulosis or inflammatory bowel disease), or over-insufflation in the presence of a competent ileocaecal valve leading to caecal perforation. None of these commonly cited factors were present in our patient. Furthermore, these factors are associated with perforation secondary to pneumatic insufflation and not direct trauma, as observed in our patient. The dense pelvic adhesions observed during surgery and the resultant distortion of normal anatomy were the contributing factors in our patient.

To the best of our knowledge, this is the first reported case of perforation caused by direct trauma from the insufflation catheter, during CTC performed via a stoma. This case highlights several important points.



**Fig. 2** CT image shows gross pneumoperitoneum (white arrow) and the Foley catheter balloon inflated outside the bowel wall (black arrow).

Firstly, in cases where difficult or abnormal anatomy is anticipated, or when radiological procedures (CTC or barium studies) are performed via a colostomy, care must be taken. Secondly, standard precautions should include careful insufflation of air to avoid over-distension, gentle passage of the catheter to minimise direct trauma and adequate bowel preparation. In addition, the referring surgeon should always indicate any previous difficulties encountered during conventional colonoscopy, and the attending radiologist should as a matter of course perform manual digitation of the stoma to determine beforehand the direction in which to angulate the catheter. In these cases, it may be beneficial to insert the catheter under direct fluoroscopic visualisation, as done during conventional double-contrast barium enemas, in order to avoid ‘blind’ passage of the catheter.

In addition, prompt recognition of complications and immediate institution of treatment are essential. Our patient was spared the morbidity of a full laparotomy, and made a fast and uncomplicated recovery. Lastly, in counselling patients undergoing CTC, special care must be taken to mention the risk of colonic perforation. Furthermore, the view that CTC is a completely non-invasive and risk-free alternative to conventional colonoscopy should be revised.

While CTC remains an important imaging modality in our armamentarium for screening both symptomatic and asymptomatic patients, due consideration must be given when performing the procedure, especially when abnormal or altered anatomy is present. Proper patient selection and counselling as well as rapid recognition of complications are essential.

**REFERENCES**

1. Vining DJ, Gelfand DW, Bechtold RE, et al. Technical feasibility of colon imaging with helical CT and virtual reality (abstr). *AJR Am J Roentgenol* 1994; 162(Suppl):104.
2. Kamar M, Portnoy O, Bar-Dayyan A, et al. Actual colonic perforation in virtual colonoscopy: report of a case. *Dis Colon Rectum* 2004; 47:1242-4.
3. Coady-Fariborzian L, Angel LP, Procaccino JA. Perforated colon secondary to virtual colonoscopy: report of a case. *Dis Colon Rectum* 2004; 47:1247-9.
4. Burling D, Halligan S, Slater A, Noakes MJ, Taylor SA. Potentially serious adverse events at CT colonography in symptomatic patients: national survey of the United Kingdom. *Radiology* 2006; 239:464-71.
5. Sosna J, Blachar A, Amitai M, et al. Colonic perforation at CT colonography: assessment of risk in a multicenter large cohort. *Radiology* 2006; 239:457-63.
6. Nelson RL, Abcarian H, Prasad ML. Iatrogenic perforation of the colon and rectum. *Dis Colon Rectum* 1982; 25:305-8.
7. Macrae FA, Tan KG, Williams CB. Towards safer colonoscopy: a report on the complications of 5000 diagnostic or therapeutic colonoscopies. *Gut* 1983; 24:376-83.
8. Jentschura D, Raute M, Winter J, et al. Complications in endoscopy of the lower gastrointestinal tract. Therapy and prognosis. *Surg Endosc* 1994; 8:672-6.
9. Sieg A, Hachmoeller-Eisenbach U, Eisenbach T. Prospective evaluation of complications in outpatient GI endoscopy: a survey among German gastroenterologists. *Gastrointest Endosc* 2001; 53:620-7.
10. Tran DQ, Rosen L, Kim R, et al. Actual colonoscopy: what are the risks of perforation? *Am Surg* 2001; 67:845-7.