

An unusual course of the thoracic duct in relation to the vertebral vessels

Kaur D¹, MBBS, MS, Jain M¹, MBBS, MS, Dhall U¹, MBBS, MS, Singh K², MBBS, MD

ABSTRACT A variation in the course of the thoracic duct was found in the cervical portion of a male cadaver during routine dissection of the head and neck region for undergraduate students. The thoracic duct, while arching laterally above the clavicle, was coursing posterior to the vertebral vein but anterior to the vertebral artery; it normally passes anterior to both the vertebral vein and artery. To the best of our knowledge, this variation in relation to the vertebral vein has not yet been reported. In addition, after coursing posterior to the vertebral vein, the thoracic duct divided into two branches that drained separately, one at the angle between the internal jugular vein and subclavian vein, and the other into the subclavian vein. Knowledge of these variations is essential in order to prevent injury to the thoracic duct while performing surgeries at the root of the neck.

Keywords: internal jugular vein, subclavian vein, thoracic duct, variation, vertebral vein
Singapore Med J 2012; 53(1): e1–e2

INTRODUCTION

The thoracic duct is the largest lymph vessel that extends from the second lumbar vertebra to the root of the neck. Near the lower border of the 12th thoracic vertebra, it passes through the aortic aperture of the diaphragm, and then ascends through the posterior mediastinum between the descending thoracic aorta on its left and azygous vein on its right. At the level of the fifth thoracic vertebral body, the duct gradually inclines to the left, enters the superior mediastinum and ascends to the thoracic inlet along the left border of the oesophagus. Passing into the neck, it arches laterally at the level of the seventh cervical vertebra. Its arch rises 3 cm or 4 cm above the clavicle and curves anterior to the vertebral artery and vein, the left sympathetic trunk, the thyrocervical artery or its branches, the left phrenic nerve and the medial border of scalenus anterior. It passes posterior to the left common carotid artery, vagus nerve and internal jugular vein, and finally ends by opening into the junction of the left subclavian and internal jugular vein. However, the duct may open into either of the great veins.⁽¹⁾ Variations in drainage pattern are often observed^(2–4) but have gained little attention. Knowledge of these variations is valuable in surgeries to be performed at the root of the neck.

CASE REPORT

An embalmed male cadaver was dissected in the Department of Anatomy of the Maharaja Agrasen Medical College in Agroha, Haryana, India. During a routine dissection of the lower portion of the neck at the thoracic inlet of the left side for undergraduate students, the skin, platysma muscle, investing layer of cervical fascia and superficial nerves were removed. The sternocleidomastoid muscle was then cut at the sternal and clavicular attachment and reflected upwards to reveal the structures at the thoracic inlet.

During cadaveric dissection, we noticed an unusual variation in the cervical portion of the thoracic duct. When the lower part of the neck was dissected, the terminal part of the thoracic duct was found to divide into two branches that drained separately; one drained at the angle between the internal jugular vein and subclavian vein and the other drained into the subclavian vein. On further careful dissection at the thoracic inlet, the course of the thoracic duct was traced in the neck. The internal jugular vein was cut and retracted downwards. It was observed that the thoracic duct, as it appeared in the thoracic inlet after traversing through the posterior and superior mediastinum, was arching laterally above the clavicle and curved anterior to the vertebral artery (Fig. 1a), left sympathetic trunk and thyrocervical artery but posterior to the vertebral vein (Fig. 1b). As it was coursing posterior to the vertebral vein, it divided into two branches; one was draining at the angle between the internal jugular vein and subclavian vein, and the other into the subclavian vein.

DISCUSSION

Embryologically, the thoracic duct is a bilateral structure that develops from the right and left lymphatic vessels. It comprises the caudal part of the right vessel, a transverse anastomosis between the right and left vessel and the cranial part of the left vessel.⁽¹⁾ Development of the thoracic duct is basically a complex process; the aetiology that results in this unusual relationship with the vertebral vein is uncertain.⁽⁵⁾ However, it may be the result of the developmental anomaly of the vertebral vein rather than the thoracic duct.

Variations in the cervical portion of the thoracic duct and its duplication have been reported from time to time. The thoracic duct duplicates or triplicates itself in 10%–40% of the population, as observed in different studies.^(1–3) Akcali et al reported two

¹Department of Anatomy, Maharaja Agrasen Medical College, Haryana, India, ²Department of Pathology

Correspondence: Dr Dalbir Kaur, Assistant Professor, Department of Anatomy, Maharaja Agrasen Medical College, Agroha Hisar 125047, Haryana, India. dalbirshelly@rediffmail.com

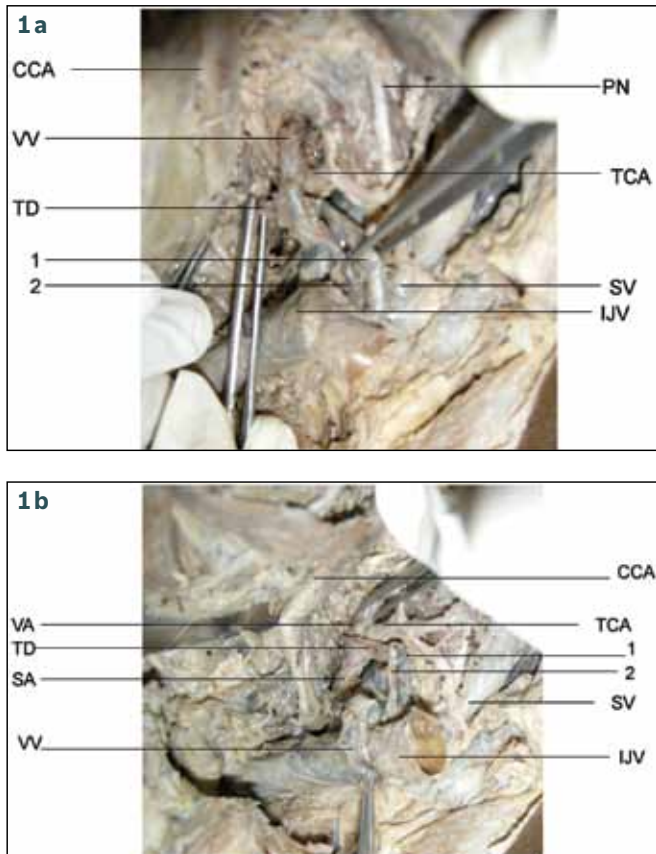


Fig. 1 Photographs show the relationship of the terminal part of the thoracic duct with the (a) vertebral vein and (b) vertebral artery. VV: vertebral vein; VA: vertebral artery; TD: thoracic duct; 1 and 2: branches of thoracic duct at the termination; CCA: common carotid artery; TCA: thyrocervical artery; SV: subclavian vein; IJV: internal jugular vein (retracted downwards); SA: subclavian artery; TCA: thyrocervical artery

anatomic variations.⁽⁴⁾ In the first case, there were two different lymphatic drainage systems. However, in the second case, the thoracic duct was found to be bifid at two different levels. Rare connection between the thoracic duct and the inferior vena cava has also been reported.⁽⁶⁾ In the present case, the thoracic duct was terminated by two branches and had an unusual course in relation to the vertebral vein. To the best of our knowledge, such a condition has not yet been reported.

Thoracic duct injury is a rare but serious complication that can occur following neck surgeries. The reported incidence of thoracic duct injury in such surgeries is 1%–2.5% of all cases, resulting in

high mortality rates in untreated patients.⁽⁷⁾ The chylous cyst of the neck secondary to traumatic disruption of the thoracic duct⁽⁸⁾ and thoracic duct ligation in chylous fistula have been reported.⁽⁹⁾ Injury to the thoracic duct can occur following hyperextension of the cervical vertebral column and fracture dislocation of the spine.⁽¹⁰⁾

Laceration of the thoracic duct during catheterisation of the subclavian vein can lead to a chyle leak despite care and attention given by the surgeon. Therefore, care should be taken in identifying and protecting the main thoracic duct during surgeries at the root of the neck, for example, oesophagectomy.⁽⁹⁾ Thoracic duct drainage has been used in inevitable ascites⁽¹¹⁾ and in immunosuppressive therapy in kidney transplantation.⁽¹²⁾

Knowledge about such variations of the thoracic duct and its relation to the vertebral vein may decrease injury to the thoracic duct in surgical procedures and prevent complications such as chylothorax.

REFERENCES

1. Standring S, Shah P. Gray's Anatomy. The Anatomical Basis of Clinical Practice. 39th ed. New York: Elsevier Churchill Livingstone, 2005.
2. Kinnaert P. Anatomical variations of the cervical portion of the thoracic duct in man. *J Anat* 1973; 115:45-52.
3. Zorzetto NL, Ripari W, De Freitas V, Seullner G. Anatomical observations on the ending of the human thoracic duct. *J Morphol* 1977; 153:363-9.
4. Akcali O, Kiray A, Ergur I, Tetik S, Alici E. Thoracic duct variations may complicate the anterior spine procedures. *Eur Spine J* 2006; 15:1347-51.
5. Van der Putti SC, Van Limborgh J. The embryonic development of the lymphatic system in man. *Acta Morphol Neerl Scand* 1980; 18:323-35.
6. Ranade AV, Rai R, Prabhu LV, Kumaran M. A rare lymphatico-venous communication associated with duplication of thoracic duct. *Int J Morphol* 2006; 24:155-8.
7. Hehar SS, Bradley PJ. Management of chyle leaks. *Curr Opin Otolaryngol Head Neck Surg* 2001; 9:120-5.
8. Adhikesavan LG, Ayoub WT, Schumacher HR. Misdiagnosis of a chylous cyst as chest wall gouty tophus: a case of true pseudogout. *Arthritis Rheum* 2007; 56:3854-7.
9. Van Natta TL, Nguyen AT, Benharash P, French SW. Thoracoscopic thoracic duct ligation for persistent cervical chyle leak: utility of immediate pathologic confirmation. *JSL* 2009; 13:430-2.
10. Nair SK, Petko M, Hayward MP. Aetiology and management of chylothorax in adults. *Eur J Cardiothorac Surg* 2007; 32:362-9.
11. Dumont AE, Mulholland J H. Alterations in thoracic duct lymph flow in hepatic cirrhosis: significance in portal hypertension. *Ann Surg* 1962; 156:668-75.
12. Franksson C, Blomstrand R. Drainage of the thoracic lymph duct during homologous kidney transplantation in man. *Scand J Urol Nephrol* 1967; 1:123-31.