

Psoriasiform dermatitis in a case of newly diagnosed locally advanced pyriform sinus tumour: Bazex syndrome revisited

Koh WL¹, MBBS, Ang CC¹, MBBS, MRCP, Lim SPR¹, MRCP, FAMS

ABSTRACT Acrokeratosis paraneoplastica of Bazex is a rare but important paraneoplastic dermatosis, usually manifesting as psoriasiform rashes over the acral sites. It often precedes diagnosis of the associated malignancy, usually that of upper aerodigestive tract squamous cell carcinoma. We present the case of a patient with a newly diagnosed pyriform sinus tumour and associated acrokeratosis paraneoplastica. To the best of our knowledge, this is the first reported case in the local literature.

Keywords: acrokeratosis paraneoplastica of Bazex, carcinoma, paraneoplastic dermatosis
Singapore Med J 2012; 53(1): e12–e14

INTRODUCTION

Acrokeratosis paraneoplastica of Bazex is a rare paraneoplastic dermatosis associated with upper aerodigestive tract carcinomas. We present the case of a patient with a newly diagnosed pyriform sinus tumour and associated acrokeratosis paraneoplastica.

CASE REPORT

A 61-year-old Indian man was referred to the surgical department for evaluation of a right-sided neck mass. He had multiple strokes, a previous myocardial infarction with a left ventricular clot that required anticoagulation, hypertension and hyperlipidaemia. At the time of presentation, he was residing in a nursing home. As the patient was unable to provide a history, the duration of the right-sided neck mass was unknown. He was referred to our dermatology department for evaluation of generalised non-pruritic scaly rashes that were noted during his admission.

The patient was cachectic and had a 4 cm × 4 cm tumour located at the anterior border of the right sternocleidomastoid muscle. It was firm, non-mobile and non-tender (Fig.1). Skin findings included scaly scalp dermatitis and thin scaly psoriasiform plaques over the brows, ears and tip of the nose (Fig. 1), the extensor surfaces of the upper limbs (Fig. 2), the knees and shins (Fig. 3). Hyperkeratosis and superficial desquamation were observed over the bilateral palms (Fig. 4). The patient did not have any plantar keratoderma, and his nails were unaffected.

Computed tomography (CT) of the neck revealed a 5.0 cm × 4.0 cm mass extending from the right pyriform sinus to the right supraglottic region, which was associated with erosion of the right cricoid cartilage and was encasing the right internal carotid artery. There was also a large heterogeneous mass in the right carotid space measuring 5.5 cm × 3.6 cm, which was suspicious for lymph node metastasis (Fig. 5). Fine needle aspiration cytology

of the right-sided neck mass showed malignant squamous cells. A diagnostic nasal endoscopy revealed a right pyriform sinus tumour involving the right aryepiglottic fold with a nodule extending over the vocal cords, thus causing supraglottic stenosis. Biopsies taken from the tumour showed an invasive and moderately to poorly differentiated squamous cell carcinoma. CT of the thorax, abdomen and pelvis for staging were grossly unremarkable. The patient was diagnosed with locally advanced squamous cell carcinoma of the right pyriform sinus with right cervical lymph node metastasis. In view of his comorbidities and poor functional status, he was treated with palliative radiotherapy. The psoriasiform dermatitis in the context of the above malignancy was clinically diagnosed as acrokeratosis paraneoplastica of Bazex, and a skin biopsy was not performed. The patient was treated with topical steroids and keratolytics.

DISCUSSION

Acrokeratosis paraneoplastica was first described by Bazex in 1965 in a patient with pyriform sinus tumour and cervical metastases.⁽¹⁾ This condition should not be confused with Bazex-Dupré-Christol syndrome (also known as Bazex syndrome), which is an inherited disease characterised by follicular atrophoderma, congenital hypotrichosis and multiple basal cell carcinomas.⁽²⁾ Acrokeratosis paraneoplastica of Bazex is recognised as a rare paraneoplastic phenomenon, in the same vein as other noteworthy paraneoplastic cutaneous manifestations of underlying malignancies such as the heliotrope rashes of adult dermatomyositis (associated with multiple solid organ cancers and in Singapore's context, nasopharyngeal carcinoma), acanthosis nigricans (associated with adenocarcinomas) and acquired ichthyosis (associated with Hodgkin's disease and other lymphomas), among others.⁽³⁾ In 2006, Karabulut et al found approximately 140 cases of acrokeratosis paraneoplastica in the literature.⁽²⁾

¹Department of Dermatology, Changi General Hospital, Singapore

Correspondence: Dr Koh Wei Liang, Medical Officer, Department of Dermatology, Changi General Hospital, 2 Simei Street 3, Singapore 529889. koh_wei_liang@hotmail.com

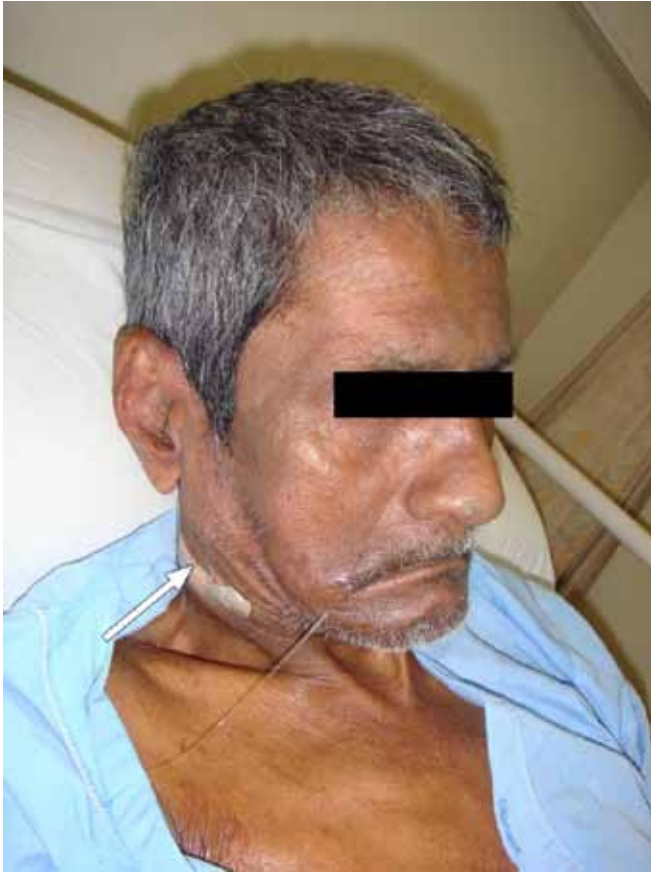

Fig. 1 Photograph shows a right-sided neck mass (arrow showing site of fine needle aspiration cytology) and thin scaly psoriasiform plaques over the brows, helix of the right ear and tip of the nose.

The cutaneous findings of acrokeratosis paraneoplastica of Bazex evolve through three stages.⁽⁴⁾ In the first stage, erythematous psoriasiform plaques are found on the fingers, toes, helices of ears and nose. Nail folds are usually involved, leading to nail dystrophy. The associated tumour is frequently asymptomatic at this stage. In the second stage, the skin eruption spreads to the palms and soles, with development of palmoplantar keratoderma. The associated tumour could display local symptoms at this stage. In the third stage, if the tumour remains untreated, the psoriasiform rashes could extend to the trunk and limbs. The histopathological findings are nonspecific and may include hyperkeratosis, parakeratosis, acanthosis, isolated necrosis of keratinocytes and a perivascular lymphohistiocytic inflammatory infiltrate. Rare features include dyskeratotic keratinocytes, vacuolar degeneration, band-like infiltrate and melanin incontinence.^(4,5) Immunofluorescence studies of lesional skin usually yield negative results.⁽⁵⁾

Carcinomas of the upper aerodigestive tract (the larynx, pharynx, trachea, bronchus and the oesophagus) are found in more than half of the cases reported in the literature. Associated neoplasms in other locations (skin, breast, genitourinary tract, liver, colon, Hodgkin's lymphoma) have also been reported. In some cases, the primary sites of malignancies were unknown.^(2,5) Clinically, the psoriasiform rashes of acrokeratosis paraneoplastica of Bazex precede the diagnosis of the malignancy in 65%–70% of cases, occur simultaneously in 15%–25% of

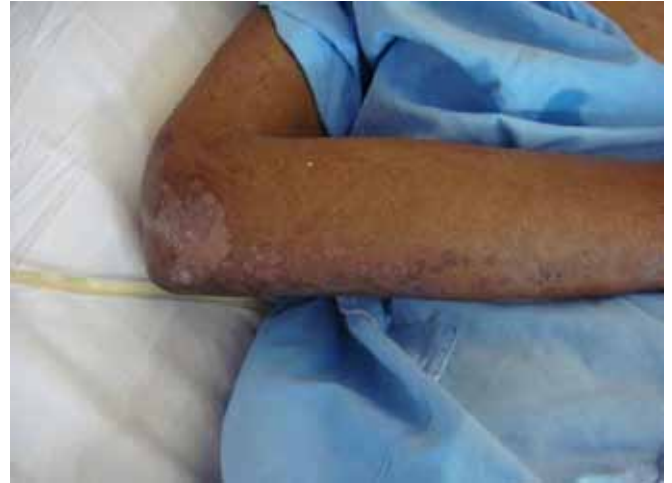

Fig. 2 Photograph shows thin psoriasiform plaques on the extensor surface of the right forearm.

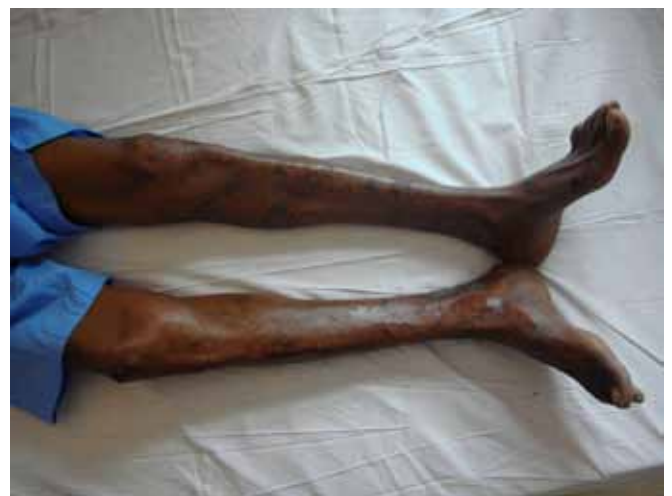

Fig. 3 Photograph shows thin psoriasiform plaques over the knees and shins.

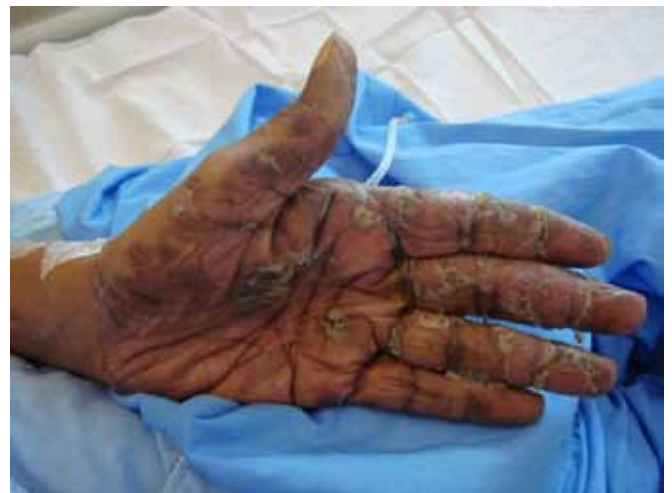

Fig. 4 Photograph shows desquamation over the left palm.

cases and develop following diagnosis of malignancy in 10%–15% of cases.⁽⁴⁾

The pathogenesis of acrokeratosis paraneoplastica of Bazex is unclear. One postulated mechanism is molecular mimicry, where the immune system is activated against the skin due to cross-reactivity between antigens found in the tumour and the skin. Another postulated mechanism is the secretion of factors by

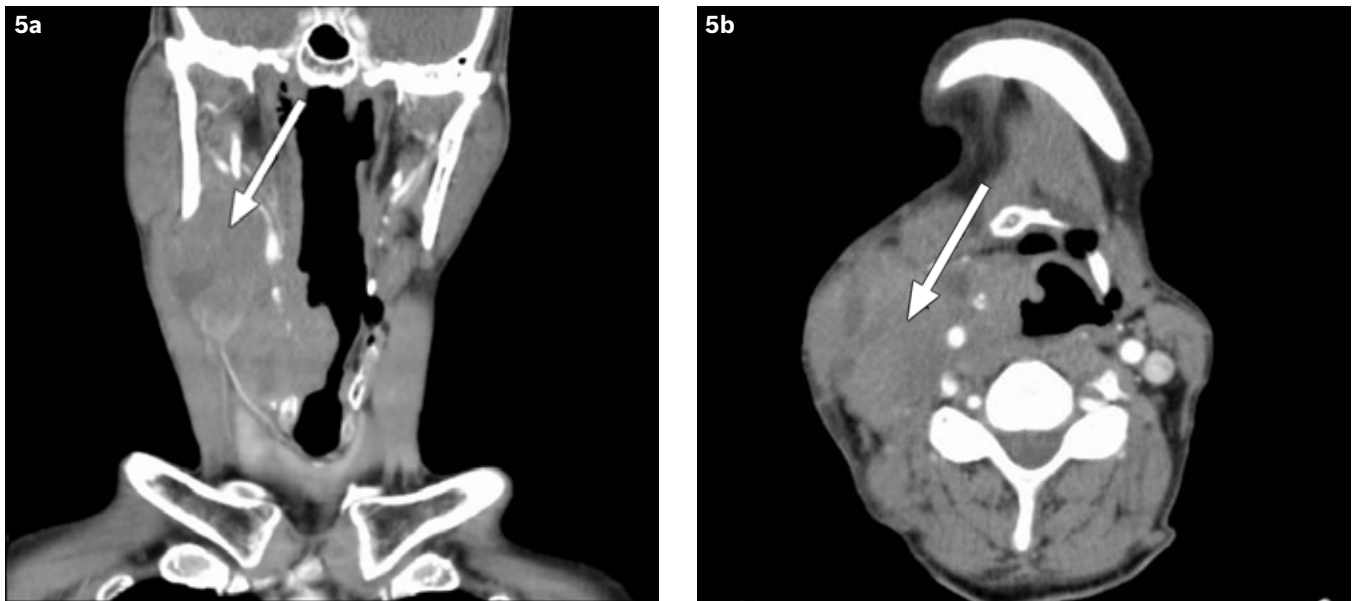


Fig. 5 a) Coronal and (b) axial CT images show a large heterogeneous mass in the right carotid space, suspicious for lymph node metastasis (arrows).

tumour cells, such as epidermal growth factor, transforming growth factor- α and insulin-like growth factor, which may play a role in the pathogenesis of this hyperproliferative paraneoplastic dermatosis.⁽²⁾

Treatment of skin lesions of acrokeratosis paraneoplastica of Bazex is often unsatisfactory, unless the associated malignancy is treated. Some of the treatments reported in the literature include topical and systemic steroids, topical vitamin D analogues, etretinate, salicylic acid and psoralen plus ultraviolet A, with variable results. Nail changes usually persist, even after treatment of the underlying associated malignancy. Reappearance of skin lesions after resolution may signify a recurrence of tumour.⁽⁵⁾

To our knowledge, this is the first case of acrokeratosis paraneoplastica of Bazex described in a patient with pyriform sinus tumour in the local literature, the same type of tumour in the patient whom Bazex et al made the association with in 1965. This is a rare but important paraneoplastic dermatosis to recognise, as skin findings usually precede symptoms of the associated

malignancy, unlike that of our patient, giving a chance to detect early-stage occult malignancy with ensuing higher rates of cure.

REFERENCES

1. Bazex A, Salvador R, Dupré A, Christol B. [Syndrome paranéoplasique à type d'hyperkératose des extrémités. Guérison après le traitement de l'épithélioma laryngé]. *Bull Soc Fr Dermatol Syphiligr* 1965; 72:182. French.
2. Karabulut AA, Sahin S, Sahin M, Ekşioğlu M, Ustün H. Paraneoplastic acrokeratosis of Bazex (Bazex's syndrome): report of a female case associated with cholangiocarcinoma and review of the published work. *J Dermatol* 2006; 33:850-4.
3. Chan HL. Markers of malignancy (carcinomas). In: Chan HL. *Cutaneous Clues to Systemic Diseases*. Singapore: Singapore University Press, 1986: 1-10.
4. Sharma V, Sharma NL, Ranjan N, Tegta GR, Sarin S. Acrokeratosis paraneoplastica (Bazex syndrome): case report and review of literature. *Dermatol Online J* 2006; 12:11.
5. Valdivielso M, Longo I, Suárez R, Huerta M, Lázaro P. Acrokeratosis paraneoplastica: Bazex syndrome. *J Eur Acad Dermatol Venereol* 2005; 19:340-4.