

# Arthroscopic debridement of intercarpal ligament and triangular fibrocartilage complex tears

Tan SWJ<sup>1</sup>, MRCS, FAMS, Ng SW<sup>2</sup>, MBBS, FRCS, Tan SH<sup>1</sup>, FRCS, FAMS, Teoh LC<sup>3</sup>, FRCS, FAMS

**INTRODUCTION** Wrist arthroscopy has evolved since its inception to become an essential diagnostic and therapeutic tool for the management of various wrist disorders. Our study aimed to examine the outcomes of arthroscopic debridement in the treatment of scapholunate (SL), lunotriquetral (LT) and triangular fibrocartilage complex (TFCC) tears.

**METHODS** We conducted a retrospective review of 68 consecutive wrist arthroscopies performed at our institution between January 2000 and July 2005. All the patients complained of wrist pain, which often interfered with their daily activities, work or sports. A standard arthroscopic technique was employed in all. Any intercarpal ligament or TFCC tears found were debrided.

**RESULTS** There were 42 patients with TFCC tears, 58 with SL tears and 49 with LT tears. At a mean follow-up time of 16.6 months, 85.3% of the patients reported an improvement in symptoms and 27.9% had improved range of motion. Grip strength improved by 11.8%. All except two patients returned to their original activities. Outcome following arthroscopic debridement was determined using the Mayo Modified Wrist Score. Based on the postoperative wrist scores of 47 patients, 24 were rated excellent, 17 good, four fair and two poor. By comparing the pre- and postoperative wrist scores of 31 patients, we were able to demonstrate significant improvement in patients who underwent wrist arthroscopies.

**CONCLUSION** Our study demonstrated that there is a definite role for arthroscopic debridement in the management of SL, LT and TFCC tears.

*Keywords: arthroscopic debridement, ligament, triangular fibrocartilage complex*  
*Singapore Med J 2012; 53(3): 188–191*

## INTRODUCTION

Wrist arthroscopy has progressed from a newly described technique in the 1970s to become an integral tool for surgeons treating various wrist disorders.<sup>(1-3)</sup> It is useful in defining the patterns, combinations and extent of soft tissue injuries, which are often underdiagnosed.<sup>(4)</sup> In treating patients with chronic wrist pain recalcitrant to conservative treatment with wrist arthroscopy, we found many patients having concomitant intercarpal ligament as well as triangular fibrocartilage complex (TFCC) injuries. We proceeded to perform simple debridement in these cases. The purpose of this study was to evaluate the efficacy of arthroscopic debridement alone in patients who were treated for suspected intercarpal ligament and TFCC injuries.

## METHODS

The records of 68 consecutive patients who underwent wrist arthroscopy between January 2000 and July 2005 at our institution were retrospectively reviewed. There were 46 men and 22 women in the study. The mean age of the patients was 32 (range 14–59) years. The right wrist was involved in 45 patients and the left in 23. The dominant hand was involved in 45 patients. All the patients complained of mechanical wrist pain, which often interfered with their daily activities, work or sports, and it was

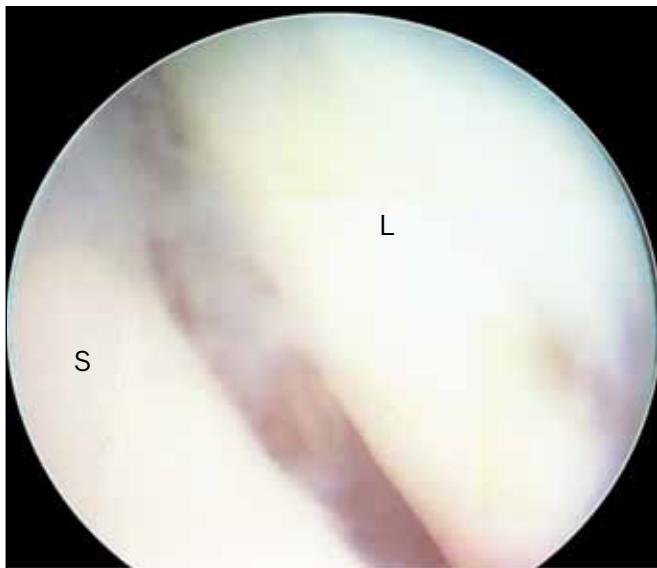unresponsive to conservative treatment, including non-steroidal anti-inflammatory medications, steroid injections, rest and splinting. The mean duration of conservative treatment was seven months. Four patients were involved in workers' compensation cases.

Pre-operative studies included plain radiographs in all patients, arthrograms in 50 and magnetic resonance (MR) imaging in 15 patients. The radiologists noted 25 possible TFCC tears, 12 possible scapholunate (SL) tears and 17 possible lunotriquetral (LT) tears on arthrograms. Arthrograms were negative in 12 patients. On the other hand, 11 patients had positive MR imaging findings: eight TFCC lesions, two SL lesions and two LT lesions. Four patients had normal MR imaging findings. None of the patients showed radiographic evidence of static instability or arthritis.

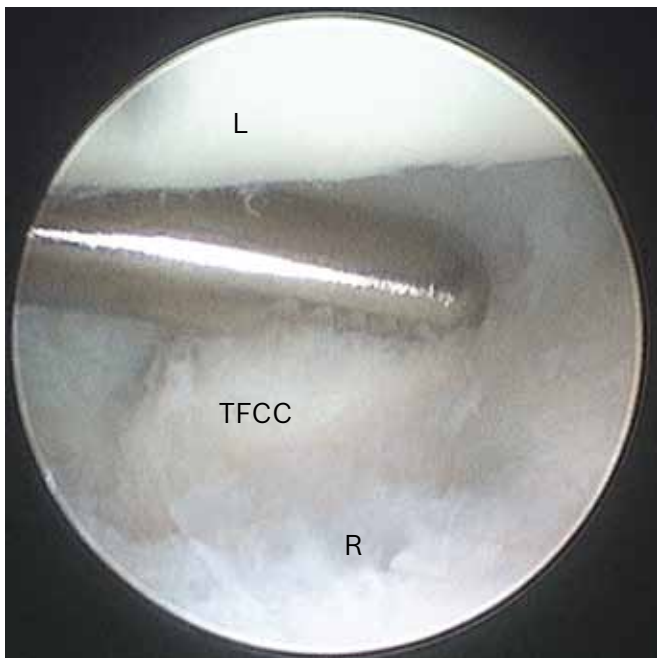
All wrist arthroscopies were performed using the standard technique, under general or regional anaesthesia.<sup>(2)</sup> Traction of 5–10 kg was applied via finger traps to provide adequate visualisation. This was followed by establishment of the 3-4 portal for camera placement, the 6R portal for instrumentation and a portal 1 cm distal to the 3-4 portal for midcarpal arthroscopy (Fig. 1) in all cases. Any TFCC tears found were debrided back to a stable rim by a small punch and shaver inserted through the 6R portal (Fig. 2). SL and LT tears were debrided back to bleeding bone

<sup>1</sup>Department of Hand Surgery, <sup>2</sup>Department of Plastic, Reconstructive and Aesthetic Surgery, Singapore General Hospital, <sup>3</sup>Department of Orthopaedic Surgery, Tan Tock Seng Hospital, Singapore

**Correspondence:** Dr Tan Siau Woon Jacqueline, Associate Consultant, Department of Hand Surgery, Singapore General Hospital, Outram Road, Singapore 169608. [jaceug@yahoo.com](mailto:jaceug@yahoo.com)



**Fig. 1** Arthroscopic image of midcarpal joint shows a scapholunate gap of Geissler Grade III instability. (S: scaphoid; L: lunate)



**Fig. 2** Arthroscopic image of radiocarpal joint shows debridement of a central TFCC tear. (L: lunate; R: radius; TFCC: triangular fibrocartilage complex)

via the 6R portal. Percutaneous fixation was not performed on any of the patients. Synovectomy and debridement of chondral defects were also performed, where necessary.

Postoperatively, the wrist was placed in a brace for six weeks, and the patient was started on occupational therapy for range of motion and grip-strengthening exercises shortly after surgery. The average postoperative follow-up interval was 16.6 (range 6–54) months. The results of arthroscopic debridement were tabulated using the Mayo Modified Wrist Score (Table I), which was based on the assessment of pain, work status, range of motion and grip strength at the time of the final follow-up.<sup>(5)</sup> The scores were categorised as follows: excellent 91–100; good 80–90; fair 65–79; and poor < 65 or any circumstance in which the patient required an additional procedure. A total of 47 out of the 68 patients had

**Table I. Mayo Modified Wrist Score.<sup>(5)</sup>**

Parameter	Score
<b>Pain</b>	
No pain	25
Mild occasional	20
Moderate	15
Severe	0
<b>Work status</b>	
Regular job	25
Restricted job	20
Able to work but unemployed	15
Unable to work due to pain	0
<b>Range of motion</b>	
> 120°	25
100°–119°	20
90°–99°	15
60°–89°	10
30°–59°	5
0°–29°	0
<b>Grip strength (% of normal)</b>	
90–100	25
75–89	15
50–74	10
25–49	5
0–24	0

**Table II. Mechanism of injury (n = 53).**

Mechanism	No. (%)
Fall on outstretched hand	26 (49.0)
Sporting activities	11 (20.8)
Twisting injuries	4 (7.5)
Struck by object	3 (5.7)
Repetitive strain	3 (5.7)
Miscellaneous (traction, lifting)	6 (11.3)

their postoperative wrist scores calculated. Statistical analysis was performed using student's *t*-test for comparison of pre- and postoperative values. A *p*-value < 0.05 was considered to be statistically significant.

## RESULTS

In all, 53 (77.9%) patients reported a history of specific wrist injury. The mechanisms of injury are shown in Table II, with the most common being fall on outstretched hand. Among the 68 patients who underwent wrist arthroscopy, 27 had distal ulna tenderness, 25 had tenderness over the SL interval and nine had tenderness over the LT interval. During stress testing, 27 patients showed a positive Watson scaphoid shift test and six patients showed a positive LT ballotment test.

Arthroscopy revealed 58 (85.3%) patients with SL tears and 49 (72.1%) patients with LT tears. Based on the arthroscopic classification of carpal instability by Geissler et al,<sup>(6)</sup> there were two Type I, 33 Type II, 19 Type III and four Type IV SL tears. Arthroscopic evaluation also revealed one Type I, 28 Type II, 17 Type III and three Type IV LT tears. On the other hand, 42 patients were found to have TFCC tears, of which 35 were central and seven were radial-sided. Other findings included synovitis

and chondral lesions such as lunate chondromalacia. Out of the 68 patients, 13 (19.1%) had either isolated SL or TFCC tears. 29 (42.7%) patients had double pathologies and 26 (38.2%) had all three pathologies.

In terms of pain score, our patients benefitted the most from arthroscopy. Pre-operatively, wrist pain was present in all 68 patients, with most complaining of moderate pain. Postoperatively, 58 (85.3%) patients reported an improvement in symptoms, while the pain remained unchanged in eight (11.8%) patients and worsened in two (2.9%). 19 (27.9%) patients reported an improvement in range of motion. Grip strength, measured with a Jamar dynamometer, was shown to have improved by 11.8% after surgery. The mean grip strength for the affected wrist pre- and postoperatively was 25.5 kg and 28.5 kg, respectively. These differences were statistically significant ( $p < 0.05$ ). All except two patients returned to their original activities. On the average, the patients rested for 2.6 months before returning to work.

Based on the postoperative wrist scores of 47 patients, the clinical results of arthroscopic debridement were excellent in 24 (51.1%) patients, good in 17 (36.2%), fair in four (8.5%) and poor in two (4.2%). In patients with isolated SL or TFCC injuries, good or excellent results were obtained in eight out of ten patients. Good or excellent results were obtained in 18 out of 20 patients with two pathologies, and 15 out of 17 patients with all three pathologies. Table III shows the breakdown of the postoperative wrist scores in these patients, according to their arthroscopic diagnoses. In addition, 31 patients in this group had their pre-operative scores calculated. The mean pre- and postoperative wrist scores were 73 and 87, respectively, indicating significant improvement ( $p < 0.05$ ).

There were few short-term complications after arthroscopy. Two patients developed paraesthesia in the distribution of the dorsal cutaneous branch of the ulnar nerve. The symptoms eventually resolved by one month and nine months in each of the patients. No wound infections, synovial fistulas, complex regional pain syndrome or hypertrophic scars were noted. Two patients required secondary procedures. One patient with Geissler Type II SL tear and radiocarpal synovitis sustained a fall on the affected limb shortly after the procedure and continued to complain of pain in the affected wrist. He subsequently underwent a scaphotrapezotrapezoid fusion at six months, and his symptoms resolved completely six months later. Another patient with combined Geissler Type II SL and central TFCC tears sustained an undisplaced fracture of the right radial styloid five months before the wrist arthroscopy. During the wrist arthroscopy, there was already Grade 4 chondral erosions of the lunate and scaphoid fossas of the radius, in addition to chondral lesions of the capitate, as well as extensive synovitis involving the radiocarpal and mid-carpal joints. However, there was no radiographic evidence of arthritis prior to the procedure. Three months post arthroscopy, the patient continued to complain of persistent right wrist pain and subsequently underwent wrist fusion with AO plate and iliac crest bone grafting.

**Table III. Breakdown of postoperative wrist scores in patients with combined injuries.**

Type of injury	No. with postop wrist scores	Post-op wrist score			
		Excellent	Good	Fair	Poor
SL only (n = 9)	7	3	2	1	1
TFCC only (n = 4)	3	2	1	-	-
SL, TFCC (n = 6)	4	-	3	-	1
SL, LT (n = 17)	13	7	6	-	-
LT, TFCC (n = 6)	3	1	1	1	-
SL, LT, TFCC (n = 26)	17	11	4	2	-

SL: scapholunate; TFCC: triangular fibrocartilage complex; LT: lunotriquetral

## DISCUSSION

Wrist arthroscopy has a valuable role in the treatment of chronic wrist pain.<sup>(7)</sup> It allows for direct visualisation of the radiocarpal and midcarpal joints, and therefore, identification of various partial lesions in the wrist, such as ligament attenuations and chondromalacia that are not apparent on other imaging modalities.<sup>(8,9)</sup> Many surgeons regard it as the gold standard investigation in the diagnosis of carpal instability, especially since it can pick up intercarpal ligament tears and reveal intra-articular abnormalities.<sup>(9,10)</sup> The main issue with wrist arthroscopy is that not all abnormalities detected during the procedure are the cause of the patient's symptoms. Evaluation of the outcomes of treatment becomes complicated since treatment of concomitant lesions may result in the alteration of symptoms.

Wrist arthroscopy also allows one to treat the pathology during the same setting. Its disadvantages are the surgical risks, the need for regional or general anaesthesia and the high cost. There are several reports on the application of wrist arthroscopy as a therapeutic modality in the treatment of intercarpal ligament and TFCC injuries. Few studies, however, have examined the outcomes of arthroscopic debridement alone.<sup>(11-16)</sup> The purpose of this paper was to assess the outcomes of debridement alone in patients who were found to have intercarpal ligament and TFCC tears during wrist arthroscopy. There is currently no arthroscopic procedure described to directly repair SL or LT ligament injuries, although some cadaveric work on arthroscopic repair of the SL ligament exists.<sup>(17)</sup> Indirect procedures, including debridement, ligament reconstruction and limited wrist arthrodesis, may be beneficial. The main disadvantage of the latter two procedures is the need for prolonged splinting, which may result in wrist stiffness. Arthroscopic debridement alone for intercarpal ligament tears has been proven to be clinically effective.<sup>(11,12)</sup> This is due to the stabilising effect of scar tissue formation in the debrided area after the procedure, which contributes to the strength of the remaining ligament.<sup>(5,11)</sup> Debridement of these intercarpal tears can also achieve pain relief in patients with these injuries.<sup>(5,11,12)</sup>

Weiss et al<sup>(11)</sup> examined the role of arthroscopic debridement alone for complete and incomplete intercarpal ligament tears in 43 wrists at a mean follow-up time of 27 months. In his study, 85%

of patients with incomplete SL tears reported symptomatic relief compared to 67% of patients with complete SL tears. The authors also noted pain relief with arthroscopic debridement alone in all six patients with partial LT tears and seven of the nine patients with complete ligament disruption. No statistically significant deterioration in radiographs was found. The results suggested that intercarpal ligament tears may be treated from a symptomatic standpoint by debridement alone for at least several years.<sup>(11)</sup>

Ruch and Poehling<sup>(12)</sup> studied the outcomes of 14 patients with chronic mechanical wrist pain who had undergone arthroscopic debridement and early mobilisation for the treatment of isolated partial SL and LT ligament injuries. Out of the 14 patients, 13 were reported to be highly satisfied with the excellent relief of painful crepitant symptoms and early return of wrist function.<sup>(12)</sup> Westkaemper et al<sup>(5)</sup> used arthroscopic debridement alone to treat 23 patients with SL ligament tears (21 partial and two complete) and five patients with LT ligament tears, and reported excellent or good results in 86% of the patients with SL ligament tears and poor results in four of the five patients with LT ligament tears.<sup>(5)</sup>

The specific treatment of an established TFCC lesion is determined first by the site, followed by its origin. For centrally and radially located tears that do not have the potential to heal due to poor vascular anatomy, treatment consists of debridement.<sup>(13-15)</sup> Partial debridement has been proven to be effective biomechanically and clinically.<sup>(14,15,18)</sup> Excision of the central two-thirds of the TFCC with maintenance of the volar and dorsal radioulnar ligaments as well as ulnocarpal ligaments does not appear to significantly affect the biomechanical constraining capacity of the TFCC on the distal radioulnar joint.<sup>(16)</sup>

Minami et al<sup>(16)</sup> retrospectively reviewed 11 wrists with post-traumatic TFCC tears and five with degenerative TFCC tears, and reported excellent postoperative results of arthroscopic debridement of post-traumatic tears. However, arthroscopic partial excision of degenerative tears showed limited results. In addition, it was noted that positive ulnar variance and concomitant LT ligament tears were associated with poor clinical outcomes.<sup>(16)</sup> Westkaemper et al, who used arthroscopic debridement alone to treat 28 patients with TFCC tears, obtained 78% good or excellent results in their series.<sup>(5)</sup> Osterman and Terrill also reported excellent results with limited TFCC debridement in the avascular region.<sup>(14,15)</sup>

In our series, good or excellent results were obtained with arthroscopic debridement alone in 87.3% of the patients. 85.3% reported an improvement in pain scores and 27.9% had improved

range of motion. Grip strength improved by 11.8%, and except for two, all the patients returned to their original activities. Our results further confirmed the usefulness of arthroscopic debridement of partial and complete intercarpal ligamentous tears and TFCC tears. Based on the analysis of our series and reviews of the literature, we conclude that arthroscopic debridement of the wrist has a favourable impact on the outcomes, especially in relieving wrist pain, and results in few complications. The limitation of the studies cited (including ours) is the short follow-up time. A longer follow-up study is necessary to determine the ultimate efficacy of this procedure in the treatment of these injuries.

## REFERENCES

1. Chen YC. Arthroscopy of the wrist and finger joints. *Orthop Clin North Am* 1979; 10:723-33.
2. Kelly EP, Stanley JK. Arthroscopy of the wrist. *J Hand Surg Br* 1990; 15:236-42.
3. Monaghan BA. Uses and abuses of wrist arthroscopy. *Tech Hand Up Extrem Surg* 2006; 10:37-42.
4. Jones WA, Lovell ME. The role of arthroscopy in the investigation of wrist disorders. *J Hand Surg Br* 1996; 21:442-5.
5. Westkaemper JG, Mitsionis G, Giannakopoulos PN, Sotereanos DG. Wrist arthroscopy for the treatment of ligament and triangular fibrocartilage complex injuries. *Arthroscopy* 1998; 14:479-83.
6. Geissler WB, Freeland AE, Savoie FH, McIntyre LW, Whipple TL. Intra-articular soft-tissue lesions associated with an intra-articular fracture of the distal end of the radius. *J Bone Joint Surg Am* 1996; 78:357-65.
7. Koman LA, Poehling GG, Toby EB, Kammire G. Chronic wrist pain: indications for wrist arthroscopy. *Arthroscopy* 1990; 6:116-9.
8. Rettig MR, Amadio PC. Wrist arthroscopy. Indications and clinical applications. *J Hand Surg Br* 1994; 19:774-7.
9. Morley J, Bidwell J, Bransby-Zachary M. A comparison on the findings of wrist arthroscopy and magnetic resonance imaging in the investigation of wrist pain. *J Hand Surg Br* 2001; 26:544-6.
10. Schädel-Hopfner M, Iwinska-Zelder J, Braus T, et al. MRI versus arthroscopy in the diagnosis of scapholunate ligament injury. *J Hand Surg Br* 2001; 26:17-21.
11. Weiss AP, Sachar K, Glowacki KA. Arthroscopic debridement alone for intercarpal ligament tears. *J Hand Surg Am* 1997; 22:344-9.
12. Ruch DS, Poehling GG. Arthroscopic management of partial scapholunate and lunotriquetral injuries of the wrist. *J Hand Surg Am* 1996; 21:412-7.
13. Palmer AK. Triangular fibrocartilage disorders: injury patterns and treatment. *Arthroscopy* 1990; 6:125-32.
14. Osterman AL. Arthroscopic debridement of triangular fibrocartilage complex tears. *Arthroscopy* 1990; 6:120-4.
15. Osterman AL, Terrill RG. Arthroscopic treatment of TFCC lesions. *Hand Clin* 1991; 7:277-81.
16. Minami A, Ishikawa J, Suenaga N, Kasashima T. Clinical results of treatment of triangular fibrocartilage complex tears by arthroscopic debridement. *J Hand Surg Am* 1996; 21:406-11.
17. Stuffmann ES, McAdams TR, Shah RP, Yao J. Arthroscopic repair of the scapholunate interosseous ligament. *Tech Hand Up Extrem Surg* 2010; 14:204-8.
18. Palmer AK, Werner FW, Glisson RR, Murphy DJ. Partial excision of the triangular fibrocartilage complex. *J Hand Surg Am* 1988; 13:391-4.