

# An unusual case of adult onset progressive heterotopic ossification suggesting a variant form of fibrodysplasia ossificans progressiva

JASB *Jayasundara*<sup>1</sup>, MBBS, MRCS, GL *Punchihewa*<sup>1</sup>, MS, FRCS, DS *de Alwis*<sup>1</sup>, MS, MRCS

**ABSTRACT** Progressive heterotopic ossification (HO) is a rare disease of genetic inheritance. Fibrodysplasia ossificans progressiva (FOP) is an identified debilitating subcategory in which anomalous ossification usually begins in childhood. Congenital big toe anomalies and specific patterns of progression of ossification confirm the classic disease. Adult onset disease is extremely rare. The mechanism of disease progression is still unclear, and there is no consensus on the treatment modalities. We report a 47-year-old man with adult-onset progressive HO around the bilateral pelvic and shoulder girdles and thoracolumbar spine, which suggested a variant form of FOP. Although surgical excision is considered counterproductive in FOP, our patient showed improvement in his shoulder movement following surgery. Other management strategies, including surgery around the hips, indomethacin prophylaxis, irradiation and bisphosphonate therapy, did not improve his range of movement or disease progression.

*Keywords:* fibrodysplasia ossificans progressiva, progressive osseous heteroplasia  
Singapore Med J 2012; 53(4): e83–e86

## INTRODUCTION

Heterotopic ossification (HO) is a pathological process of lamellar bone formation in non-osseous tissues. Surgery- or trauma-related HO occurs as a localised disease.<sup>(1,2)</sup> Neurogenic HO is a complication of cerebral or spinal cord injuries and diseases.<sup>(1,2)</sup> Hereditary HO is a rare disease of genetic inheritance that usually begins in childhood, and has at least three distinct subcategories, namely fibrodysplasia ossificans progressiva (FOP), progressive osseous heteroplasia (POH) and Albright's osteodystrophy (AO).<sup>(1-3)</sup> The literature on idiopathic adult-onset progressive HO is limited.<sup>(4,5)</sup> We report an unusual case of adult-onset progressive HO around the bilateral pelvic and shoulder girdles and thoracolumbar spine, with no history of trauma, surgery or neurological disease.

## CASE REPORT

In January 2004, a 47-year-old Sri Lankan man presented with progressive restriction of movements of all the girdles over a period of one year. He was a bus conductor who played non-professional football. Starting from the hips, followed by the shoulders, the disease first affected his leisure sport, then his occupation and subsequently his daily routines. Systemic flare-up features were not manifested during this period. There was no significant past illness, trauma, or family history. The patient was able to walk a short distance with difficulty. Hip, knee and shoulder movements were restricted bilaterally. The left hip was almost completely ankylosed and right hip abduction was restricted. Multidirectional limitation of shoulder movements was noted bilaterally, and submuscular hard

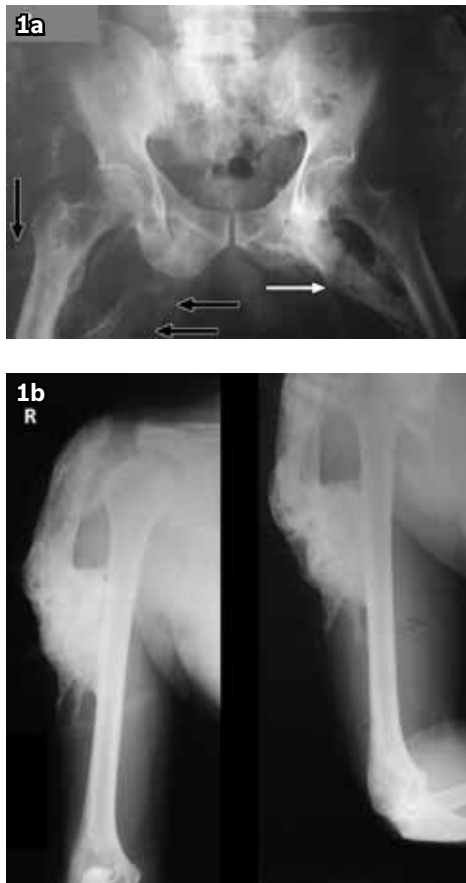masses were palpable around all affected joints. There were no cutaneous and subcutaneous ossifications. Skeletal anomalies such as hallux valgus, shortened big toes and hypoplastic thumbs were not observed. Plain radiographs showed Brookers' Grade 4 HO involving bilateral adductor compartments of the hips, abductors of the shoulders, and to a lesser extent, ossification in other peri-articular muscle compartments (Figs. 1a & b).<sup>(6)</sup> The patient's serum calcium, phosphate, alkaline phosphatase, parathyroid hormone levels and erythrocyte sedimentation rate were all normal.

Between March 2004 and February 2006, the patient underwent four surgical resections, one joint at a time, with a 4–8 month gap between the procedures. Surgeries were carried out to achieve adequate ossific mass excision in order to regain reasonable mobility. All excised masses consisted of mature bone. Left hip and thigh surgery was complicated by deep wound infection. Postoperatively, active joint movements were encouraged within tolerable pain limits after 4–5 days. Postoperative indomethacin prophylaxis was provided, but continuation beyond two weeks was not possible due to endoscopy-proven gastritis.

Following the surgeries, the patient gained objective improvement in range of movements in the affected joints over a period of about 6–9 months. However, progressive re-ossification, mainly around the hips, gradually impaired his mobility. Re-ossification was minimal around the shoulders, and range of joint movements did not deteriorate as at the hips. A course of bisphosphonate therapy (intravenous pamidronate 30 mg/day for three days, followed by oral alendronic acid 30 mg/day for

<sup>1</sup>Orthopaedic Unit, National Hospital of Sri Lanka, Colombo, Sri Lanka

**Correspondence:** Dr JASB Jayasundara, 4/7D, First Lane, Ananda Maithrie Mawatha, Maharagama 10280, Sri Lanka. [bingumal@sltnet.lk](mailto:bingumal@sltnet.lk)



**Fig. 1** (a) Pre-operative anteroposterior radiograph of the pelvis (taken in 2004) shows predominant heterotopic ossification at the adductor compartment of the left hip (white arrow) and to a lesser degree, ossification around the right hip (black arrows). (b) Pre-operative anteroposterior and lateral radiographs of the right shoulder (also taken in 2004) show heterotopic ossification predominantly affecting the abductor muscles.

three months) in 2008 failed to halt the progression of the disease. Nerve conduction studies performed in August 2009 revealed diffuse asymmetrical sensory motor conduction anomalies affecting the left ulnar nerve and bilateral common peroneal nerves, due to compression caused by ossific masses.

By January 2010, the patient had become bedridden due to a 'turning-to-stone' like fixation of the hips, knees and thoracolumbar spine. Range of movements at the shoulders was near normal. Cervical spine, temporomandibular joint as well as joints distal to the elbows and knees were also unaffected. Computed tomography confirmed a large ossific mass in the right thigh extending from the ankylosed hip to the knee, thus entrapping the femoral vessels. The left hip was also fixed, and less extensive ossific masses were observed in the left thigh. Another large ossific mass was found over the anterior aspect of the spine, extending from the mid-thoracic vertebrae to the sacrum. Residual bony masses were seen around the shoulder girdles bilaterally (Fig. 2 a–c). In February 2010, the patient underwent another surgical resection of the ossific masses in the right thigh due to impending pressure necrosis of the overlying soft tissues and skin. Surgery was followed by prophylactic external beam radiotherapy, with a total dose of 2,600 centigray in 13 fractions over 20 days.

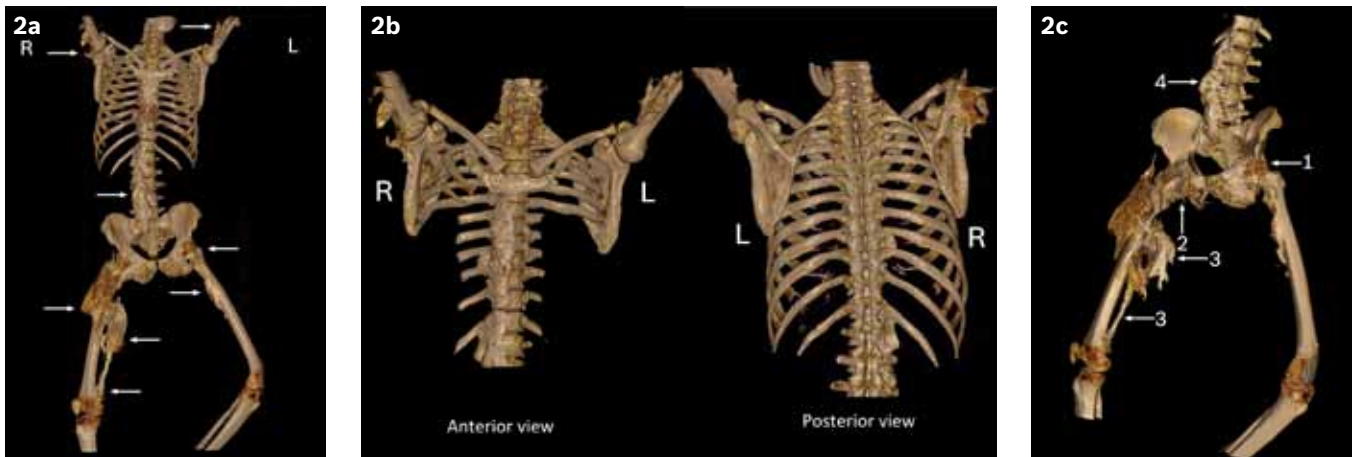
Histopathology of the excised tissues revealed mature lamellar bone formation, confirming HO with surrounding severe muscular atrophy. There were no dysplastic changes, intervening cartilages or evidence of endochondral ossification. The presence of a thin rim of fibroblasts with fibrous tissue adjacent to the bone favoured intramembranous ossification (Fig. 3). The patient was able to move both the upper limbs and eat on his own at the time of writing. His hips, knees and thoracolumbar spine were still completely ankylosed. Other than the success achieved by surgery around the shoulder girdles, none of the other management options improved his mobility.

## DISCUSSION

Acquired HO could be traumatic, surgical or neurogenic in origin. A less frequent hereditary disease category exists with several sub-varieties.<sup>(1–3)</sup> FOP is almost always associated with congenital skeletal anomalies such as hallux valgus and hypoplastic big toes.<sup>(3,7)</sup> The disease usually strikes during the first decade of life. Three large case series have described the average age of onset as 3, 5 and 4.6 years (range birth to 25 years).<sup>(7–9)</sup> Almost universally, the ossification process begins in the upper paraspinal muscles and then spreads from dorsal to ventral, axial to appendicular, cranial to caudal and proximal to distal sites.<sup>(3,8,9)</sup> Characteristic congenital malformations of the big toes and progressive HO in characteristic anatomic pattern are the defining clinical features of classic FOP.<sup>(10)</sup> In addition, there are several common variables and atypical features seen in FOP patients.<sup>(11)</sup> In a recent review, Kaplan et al subdivided 112 FOP cases into classic (n = 91), FOP-plus sporadic (n = 8) and FOP-variant (n = 13) cases.<sup>(11)</sup> Classic cases were diagnosed in the presence of both defining clinical features, while FOP-plus cases were diagnosed based on the presence of both classic features and one or more atypical features. The presence of major variations in one or both classic defining features was definitive of FOP-variant cases, and thus far, few reports on such atypical/variant cases exist in the literature.<sup>(11,12)</sup> Histology of the mature lesions of FOP would favour a process of endochondral ossification.<sup>(3,8,9,13)</sup>

Cases of POH are even rarer; since its first identification in 1994 to 2007, only 19 cases have been reported.<sup>(5)</sup> POH is characterised by dermal ossification in infancy. Ectopic ossification manifests in the skin, muscle and connective tissue in a scattered, asymmetrical manner with superficial to deep progression.<sup>(3,14)</sup> The disease predominantly affects females.<sup>(3,14)</sup> AO is associated with bradydactyly, gonadotrophin resistance, hypothyroidism and pseudohypoparathyroidism.<sup>(3)</sup> Progressive deep connective tissue ossification and severe limitation of mobility are not seen in AO. Both POH and AO would have predominant intramembranous-type ossification.<sup>(3)</sup>

Our patient had no prior history of trauma, surgery or neurological insult that could have resulted in the development of HO. The absence of bradydactyly, endocrine deficiencies and cutaneous ossification with the presence of severe progressive disease also excludes AO. Moreover, the extensive deep tissue

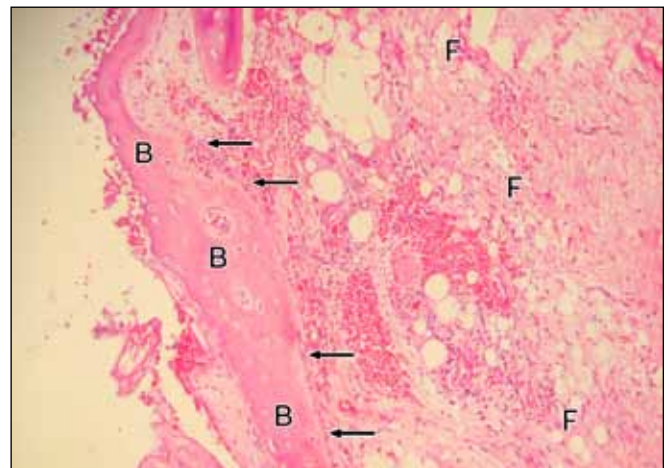


**Fig. 1** 3-D reconstructive CT images (a) Affected areas (anterior view) show ossific masses around the hips, thighs, shoulders and at the anterior aspect of the thoracolumbar spine (arrows); (b) Thoracic spine and shoulders (anterior and posterior views) show ossific masses over the anterior aspect of the thoracolumbar spine and residua around the bilateral shoulders. The lower part of the rib cage has been subtracted in the anterior view for clarity. Also note the sparing of the cervical spine and paraspinous muscles; (c) Lumbar spine, pelvis and femora (left oblique view) show ankylosing ossific masses around both hips (arrows 1 & 2), large ossific masses in the right thigh (arrow 3) and an ossific mass at the anterior aspect of the thoracolumbar spine (arrow 4).

ossification, absence of skin rashes or subcutaneous ossification, a near-symmetrical disease pattern and delayed onset precluded a diagnosis of POH. The severity of the patient's ossifications suggested FOP. The absence of characteristic big toe abnormalities and characteristic pattern of progression of ossification excluded a diagnosis of classic FOP. However, the near-symmetrical extensive HO of deep muscles in proximal to distal pattern makes a clinical diagnosis of FOP-variant possible.

Diagnosis of FOP is mainly clinical, with supportive radiological evidence.<sup>(13)</sup> Erythrocyte sedimentation rate, alkaline phosphatase levels and urinary fibroblast growth factor level may be elevated in flare-ups of the disease.<sup>(13)</sup> Diagnostic biopsy is not suggested due to the possible aggravation of ossification.<sup>(7,13)</sup> With the presence of phenotypic heterogeneity,<sup>(4,12)</sup> diagnosis may be difficult, especially in the absence of classic features. Initial misdiagnosis rates may be as high as 90%.<sup>(15)</sup> Following the recent identification of genetic changes leading to FOP,<sup>(10)</sup> genetic studies have been used for diagnostic purposes.<sup>(13)</sup> However, it is mainly used at the research level and is not freely available worldwide. Despite the absence of classical defining features of FOP, a clinical diagnosis of FOP-variant was possible in our patient on comparison with similar cases reported in the literature. However, the unavailability of facilities to perform specific genetic analysis was a limitation in our case.

The mechanism and pathophysiology leading to HO is still not fully understood. FOP was considered an important disease to understand the aetiopathogenesis of HO.<sup>(3)</sup> The discovery of genes responsible for FOP is a landmark in our understanding of the disease process of FOP and HO.<sup>(11)</sup> Shore et al, in their description of the mapping of FOP to chromosome 2q23-24 by linkage analysis in 2006,<sup>(10)</sup> identified an identical heterozygous mutation (617→ A; R206H) in the glycine-serine activation domain of Activin A type I receptor (ACVR1), which is a bone morphogenic protein type I receptor, in all affected individuals examined. All these patients had a phenotype consistent with classic FOP.



**Fig. 3** Photomicrograph shows mature bone (B) and fibro-fatty tissue (F). Rim of fibroblasts with fibrous tissue adjacent to bone (arrows) favours intramembranous ossification. Note the absence of cartilage or evidence of endochondral ossification (Haematoxylin & eosin, × 40).

Kaplan et al described the same mutation in the majority of FOP-plus patients and also identified novel ACVR1 mutations in atypical FOP cases.<sup>(11)</sup> Although hypothetical schemes on the pathophysiology of FOP have been created and animal models are currently being studied, the disease process is still not fully understood.<sup>(11)</sup> Therefore, there is no consensus on the modes of disease management.

Non-steroidal anti-inflammatory drugs (NSAIDs), especially indomethacin, or cyclo-oxygenase-2 antagonist therapy, bisphosphonate therapy, therapeutic irradiation and surgical excision are the main options for non-hereditary disease.<sup>(1)</sup> The best available option for established disease is surgical excision followed by irradiation or NSAIDs.<sup>(1)</sup> The management strategies of confirmed FOP differ from the management of acquired types of HO. Despite advances in understanding the pathophysiology of FOP, there are currently no therapies with scientifically proven benefit for prevention or treatment.<sup>(16)</sup> Medical interventions are only supportive.<sup>(13)</sup> Guidelines for symptomatic management of

flare-ups have been published, and highlight the anecdotal use of steroids in managing flare-ups.<sup>(13,16)</sup> NSAIDs, cyclo-oxygenase-2 inhibitors, leukotriene inhibitors, mast cell stabilisers and bisphosphonates have been used anecdotally in the management of chronic discomfort and on-going flare-ups.<sup>(13,16)</sup> Surgical removal of heterotopic bone is considered counterproductive, as it may lead to further ossification.<sup>(13)</sup>

In the absence of defining features of classic FOP, we had initially considered surgical resection as the option for symptomatic improvement in our patient. Postoperative prophylaxis was provided with indomethacin or irradiation, as in the management of other types of HO. Our patient gained an acceptable range of movements at the shoulders following surgery, with minimal recurrences. He did not develop aggravated, flared-up and painful ossific masses around the hips following the surgeries, although the disease progressed as rapidly as before. Our limited experience suggests that surgical resection was partially effective rather than counterproductive.

Anecdotal use of irradiation has been reported in FOP, but its efficiency has not been demonstrated.<sup>(13)</sup> Although the effect of pamidronate for symptomatic relief in FOP has also been described,<sup>(13)</sup> our patient did not show subjective or objective improvement in his symptoms with bisphosphonates.

In conclusion, this report describes a middle-aged male patient with no history of trauma or neurological disease who developed idiopathic adult onset progressive HO with a disease pattern suggestive of a variant form of FOP. Although surgical excision is believed to be counterproductive, our patient reported improvement in his shoulder movements after surgery. Other management strategies, including surgery around the hips, postoperative prophylaxis with indomethacin or irradiation and bisphosphonate therapy, did not improve his range of movements or slow down the progression of the disease.

## ACKNOWLEDGMENTS

We would like to thank Dr Janakie Fernando, Consultant Histopathologist, Dr Ama Liyadipita, Senior Registrar and Dr

Lakmali Kariyawasam, Registrar, Department of Histopathology, National Hospital, Colombo, Sri Lanka for their assistance in the preparation of this case report.

## REFERENCES

- Vanden Bossche L, Vanderstraeten G. Heterotopic ossification: a review. *J Rehabil Med* 2005; 37:129-36.
- Shehab D, Elgazzar AH, Collier BD. Heterotopic ossification. *J Nucl Med* 2002; 43:346-53.
- Kaplan FS, Glaser DM, Gannon FH, Shore EM. The molecules of immobility: Searching for the skeleton key. *Univ Pennsylvania Orthopaedic J* 1998; 11:59-66.
- Janoff HB, Tabas JA, Shore EM, et al. Mild expression of Fibrodysplasia ossificans progressiva: a report of 3 cases. *J Rheumatol* 1995; 22:976-8.
- Seror R, Job-Deslandre C, Kahan A. Progressive osseous heteroplasia: a rare case of late onset. *Rheumatology (Oxford)* 2007; 46:716-7.
- Brooker AF, Bowerman JW, Robinson RA, Riley LH Jr. Ectopic ossification following total hip replacement. Incidence and a method of classification. *J Bone Joint Surg Am* 1973; 55:1629-32.
- Connor JM, Evans DA. Fibrodysplasia ossificans progressiva. The clinical features and natural history of 34 patients. *J Bone Joint Surg Br* 1982; 64:76-83.
- Cohen RB, Hahn GV, Tabas JA, et al. The natural history of heterotopic ossification in patients who have fibrodysplasia ossificans progressiva. A study of forty-four patients. *J Bone Joint Surg Am* 1993; 75:215-9.
- Smith R, Athanasou NA, Vipond SE. Fibrodysplasia (myositis) ossificans progressiva: clinicopathological features and natural history. *QJM* 1996; 89:445-6.
- Shore EM, Xu M, Feldman GJ, et al. A recurrent mutation in the BMP type I receptor ACVR1 causes inherited and sporadic fibrodysplasia ossificans progressiva. *Nat Genet* 2006; 38:525-7.
- Kaplan FS, Xu M, Seemann P, et al. Classic and atypical fibrodysplasia ossificans progressiva (FOP) phenotypes are caused by mutations in the bone morphogenetic protein (BMP) type I receptor ACVR1. *Hum Mutat* 2009; 30:379-90.
- Virdi AS, Shore EM, Oreffo RO, et al. Phenotypic and molecular heterogeneity in Fibrodysplasia ossificans progressiva. *Calcif Tissue Int* 1999; 65:250-5.
- Kaplan FS. The International Clinical Consortium on FOP: The medical management of Fibrodysplasia ossificans progressiva: current treatment considerations. *Clin Proc Intl Clin Consort FOP* 2008; 3:1-85.
- Kaplan FS, Shore EM. Perspective Progressive osseous heteroplasia. *J Bone Miner Res* 2000; 15: 2084-94.
- Kitterman JA, Kantanie S, Rocke DM, Kaplan FS. Iatrogenic harm caused by diagnostic errors in fibrodysplasia ossificans progressiva. *Pediatrics* 2005; 116:e654-61.
- Glaser DL, Kaplan FS. Treatment considerations for the management of Fibrodysplasia ossificans progressiva. *Clin Rev Bone Miner Metab* 2005; 3:243-50.