

# Anatomical variations of the internal jugular vein: implications for successful cannulation and risk of carotid artery puncture

Thanaporn Lorchirachoonkul<sup>1</sup>, MBBS, MMed, Lian Kah Ti<sup>1</sup>, MBBS, MMed, Shivani Manohara<sup>1</sup>, MBBS, Soh Teng Lye<sup>2</sup>, MBBS, MMed, Sue-Anne Tan<sup>1</sup>, MBBS, MMed, Liang Shen<sup>3</sup>, PhD, Dave Song Chua Kang<sup>4</sup>, MBBS, MMed

**INTRODUCTION** Complications occur in over 15% of central venous cannulations, often a result of anatomical variations. This study aimed to determine the anatomical variations of the internal jugular vein (IJV), demonstrate the likely success of cannulation and assess the risk of carotid artery (CA) injury when catheterising the IJV using the external landmarks technique at various degrees of head rotation in the local population.

**METHODS** 100 elective cardiac surgical patients were prospectively enrolled. Simulated catheterisations were performed with patients placed in the Trendelenburg position. The standard landmark technique was used to identify anatomy. Simulations were done at six different degrees of rotation of the head: 0°, 30° and 60° for both right and left IJVs. Difficult catheterisation was defined as an IJV diameter < 7 mm.

**RESULTS** There was no thrombosed or absent IJV in any patient. Catheterisation was potentially difficult in 15% of patients at 30° head rotation and more difficult for the left IJV than the right (20% vs. 10%;  $p < 0.05$ ). The simulated needle hit the IJV in 82% of the attempts, but the needle was in the middle 80% of the vein only 70% of the time. Neck rotation increased the degree of overlap of the CA relative to the IJV from 20%–30% to 50%.

**CONCLUSION** Anatomical variations play a significant role in determining the success of IJV catheterisation as well as the incidence of catheterisation-associated complications. This study emphasises the importance of using ultrasonography to guide IJV catheterisation, even in patients with seemingly normal neck anatomy.

Keywords: carotid arteries, central venous catheterisation, jugular veins, ultrasonography  
Singapore Med J 2012; 53(5): 325–328

## INTRODUCTION

Central venous catheterisation is an extremely common procedure, with over 5 million catheterisations performed a year in the USA<sup>(1)</sup> and 200,000 a year in the UK's National Health Service.<sup>(2)</sup> At our institution, we perform 1,000 central venous catheterisations annually, most frequently in cardiac surgical patients. The most commonly used technique and insertion site is percutaneous catheterisation of the internal jugular vein (IJV) using a modification of the catheter-over-a-wire (Seldinger) technique.<sup>(3)</sup> This technique of catheterisation of the IJV is highly successful, with success rates reported in the 85%–99% range.<sup>(4)</sup>

However, over 15% of patients undergoing central venous catheterisation suffer complications.<sup>(1)</sup> Although serious immediate complications are infrequent, this procedure continues to contribute to morbidity and mortality. Complications can be divided into three categories: mechanical, thromboembolic and infectious. Anatomical variation may play a role in the genesis of mechanical complications. In Western populations, it has been reported that up to 12% of patients have significant anatomical variations, particularly small vein diameters, which may result in mechanical complications.<sup>(5,6)</sup> The incidence of such anatomical variations in the local population being unknown, we speculated

that the incidence may be higher given the smaller body size of Asians.

This study was undertaken to determine the anatomical variations pertinent to percutaneous central venous catheterisation of the IJV in our local patient population. We also aimed to determine the likely success of IJV cannulation and investigate the potential risk of carotid artery (CA) puncture when using the external landmarks technique to guide IJV cannulation for both the right and left IJVs at various degrees of head rotation.

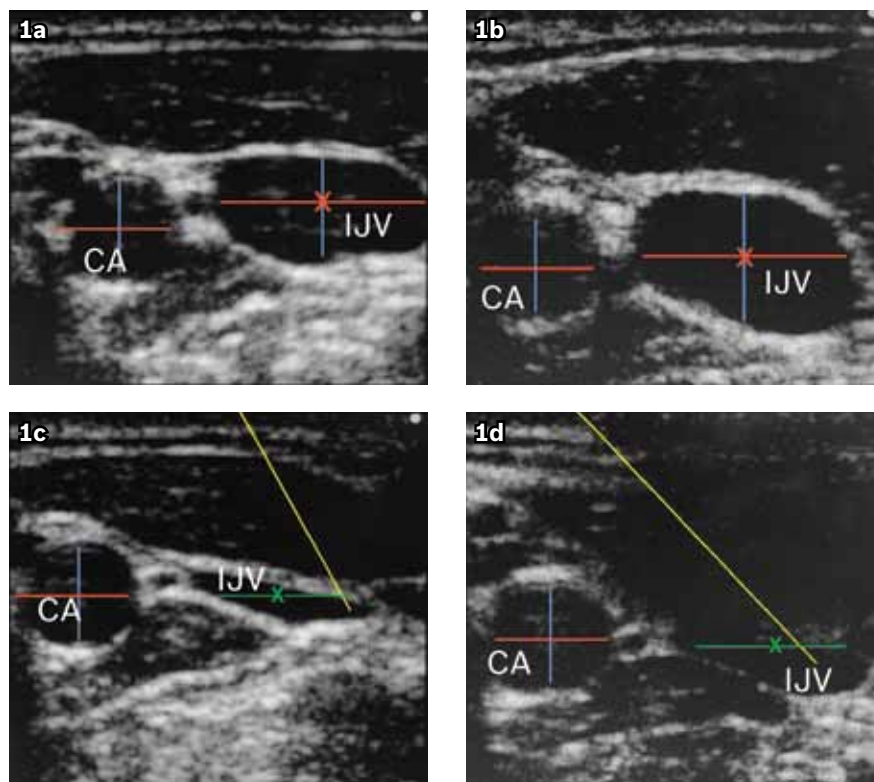
## METHODS

With the approval of the institutional review board and written informed consent from patients, 100 adult patients (age > 21 years) presenting for elective cardiac surgery requiring central venous catheterisation were recruited for the study. Patients who were haemodynamically unstable, with known abnormal neck anatomy, previous surgery or trauma involving the neck, or prior catheterisation of neck vessels were excluded.

Central venous catheterisation simulations were done in awake, non-sedated patients. Every patient had an intravenous line placed and would have typically received < 500 ml of crystalloid. Positioning of the patients was done in accordance with the central landmark technique first described by English

<sup>1</sup>Department of Anaesthesia, National University Hospital, <sup>2</sup>Department of Anaesthesia, Khoo Teck Puat Hospital, <sup>3</sup>Dean's Office, Yong Loo Lin School of Medicine, National University of Singapore, <sup>4</sup>National University Health System, Singapore

**Correspondence:** A/Prof Ti Lian Kah, Department of Anaesthesia, National University Hospital, 5 Lower Kent Ridge Road, Singapore 119074. [lian\\_kah\\_ti@nuhs.edu.sg](mailto:lian_kah_ti@nuhs.edu.sg)



**Fig. 1** (a–d) US images of the right IJV and right CA with head rotated to the left at 30° and 60°, respectively (red line: maximum diameter; blue line: AP diameter; yellow line: simulated needle path; green line: middle 80% of IJV; AP: anteroposterior; CA: carotid artery; IJV: internal jugular vein).

et al.<sup>(7)</sup> Each patient was placed in a moderate (15°) Trendelenburg position. The two heads (sternal and clavicular) of the sternocleidomastoid muscle were identified, and a mark was made at the apex of the triangle formed by the two heads at the level of the cricoid cartilage. Manoeuvres to increase the size of the neck vessels, such as the Valsalva manoeuvre or fluid loading, were not performed. The simulation was terminated if any patient encountered discomfort.

To simulate the needle path, a two-dimensional ultrasonography system with a 10–5 MHz 38-mm broadband linear array probe suitable for vascular imaging was used (180plus®; Sonosite Inc, Bothell, WA, USA). The ultrasonography probe was positioned at the typical needle-insertion point used in central vein catheterisation at 90° to the neck surface. The IJV was identified based on its morphological structure (thin-walled, oval or round shape) and compressibility. The CA was identified based on its morphological structure (thick-walled, round shape) and resistance to compression. Simulations were done in six positions: head at 0° (midline) and rotated to 30° and 60° from midline for both the right and left IJVs. The degree of head rotation was measured using a protractor by measuring the angle at which the tip of the nose was turned away from the midline. Care was taken to place the probe lightly to limit vessel compression during image acquisition. The images were saved and measured at a later time (Fig. 1).

At each position, the following were determined: (1) the size of the IJV (width and anteroposterior [AP] diameter); (2) the size of

**Table I. Demographics of the study group.**

Demographic	Mean (range)
Male gender (%)	84
Age (yrs)	55.7 (21–89)
Weight (kg)	65.6 (32–108)
Height (cm)	165.5 (140–180)
Body surface area (m <sup>2</sup> )	1.73 (1.12–2.26)
Body mass index (kg/m <sup>2</sup> )	23.8 (13.9–37.4)

the CA (width and AP diameter); (3) whether the simulated needle path intersected the IJV; (4) whether the simulated needle path intersected the middle 80% of the IJV; (5) the distance from skin to the middle of IJV (depth of IJV); and (6) the degree of overlap between the IJV and CA.

As it has previously been shown that vessel catheterisation is significantly more difficult when the vessels are  $\leq 7$  mm in diameter,<sup>(6)</sup> we assessed the potential difficulty of insertion as a dichotomous variable in which difficult catheterisation was defined when the width of the vein was  $\leq 7$  mm. The IJV widths at 30° head rotation on both the right and left sides were chosen to represent their respective sides, as this is the routine head rotation for standard cannulation at our institution.

Demographic and measurement data were analysed using the Statistical Package for the Social Sciences version 18.0 (SPSS Inc, Chicago, IL, USA). Linear mixed models with unstructured covariance for repeated measurements were used to analyse the six quantitative measurements of the right and left vessels at

Table II. Measurements of the IJV and CA.

Measurement	Mean (range)					
	Right midline	Right 30°	Right 60°	Left midline	Left 30°	Left 60°
IVJ width (mm)	13.4 ± 4.5 (1.6–25.0)	12.9 ± 4.4 (1.0–24.0)	13.0 ± 4.2 (1.7–24.0)	11.0 ± 4.4* (2.0–25.0)	11.0 ± 4.3* (2.7–24.0)	11.0 ± 4.3* (2.7–24.0)
AP diameter of IJV (mm)	8.5 ± 2.7	9.0 ± 2.9	9.1 ± 2.8	7.8 ± 2.7	8.2 ± 2.8	8.2 ± 2.8
Difficult IJV catheterisation (%)	9.0	10.0	8.0	19.0*	20.0*	20.0*
CA width (mm)	6.5 ± 1.5	6.5 ± 1.5	6.5 ± 1.5	6.4 ± 1.3	6.4 ± 1.3	6.4 ± 1.4
AP diameter of CA (mm)	6.5 ± 1.5	6.5 ± 1.5	6.5 ± 1.5	6.4 ± 1.4	6.4 ± 1.4	6.4 ± 1.4

\*  $p < 0.05$  as compared to measurements of the right IJV.

AP: anteroposterior; CA: carotid artery; IJV: internal jugular vein

Table III. Path of the simulated needle and relevant anatomy.

Detail	Right midline	Right 30°	Right 60°	Left midline	Left 30°	Left 60°
Depth of IJV (mm)	14.8 ± 3.2	13.9 ± 3.5	14.0 ± 3.4	13.8 ± 3.3	13.2 ± 3.3	13.2 ± 3.3
<b>Location of CA relative to IJV</b>						
Medial, deep (%)	81	78	73	83	75	73
Central, deep (%)	7	12	16	6	16	18
Lateral, deep (%)	1	1	1	1	2	3
Mean overlap of IJV with CA (mm)	2.8 ± 2.2	4.3 ± 2.3	4.8 ± 2.5	3.3 ± 2.1*	5.0 ± 2.3*	5.3 ± 2.3*
Percentage overlap of IJV with CA (mean [95% CI])	22 (18–26)	36 (32–41)	39 (34–43)	33* (28–37)	49* (43–54)	52* (47–57)

\*  $p < 0.05$  as compared to corresponding degree of neck rotation of the right IJV.

CA: carotid artery; IJV: internal jugular vein

different degrees of neck rotation. For qualitative data analysis, a generalised estimating equation utilising an unstructured working correlation matrix and binary responses was adopted. For both analyses, the Bonferroni adjustment was applied to allow for pair-wise comparisons and to account for multiple comparisons. Overall comparison of the right and left vessels for predicted difficult catheterisation was performed using the paired  $t$ -test. The level of significance was defined as  $p < 0.05$ .

## RESULTS

100 patients participated in the study. In general, the demographics of the study population reflected those of patients presenting for cardiac surgery, namely an older and predominantly male population (Table I). 74 patients were Chinese, 18 were Malay and eight were Indian. The patients were generally small in size (mean height 165 cm; mean weight 65 kg). Less than 5% of the population was obese, which is based on the World Health Organization definition of obesity for the Asian population of a BMI  $\geq 27.5$  kg/m<sup>2</sup>.<sup>(8)</sup>

We were able to visualise the IJV and CA on ultrasonography in all the studied neck positions in every patient. There was no absent or thrombosed IJV visualised. At a 30° head rotation, the potential for difficult catheterisation was 15%. The difficulty was greater when catheterisation of the left IJV was simulated as compared to the right (20% vs. 10%;  $p < 0.05$ ). The right IJV was significantly wider and had a larger AP diameter compared to the left IJV (Table II). Head rotation did not significantly influence the size of the IJV or the potential for difficult catheterisation. CAs were similar in size on both sides and were not affected by head rotation.

Using the standard external landmark technique, the simulated needle would have hit the IJV in 82% of the attempts. However, the needle was in the middle 80% of the vein in only 70% of these attempts. The average distance between the skin and the middle of the IJV was only 14 mm. These measurements did not significantly change between sides or with head rotation (Table III). Head rotation, however, did have an influence on the position of the CA relative to the IJV. On both sides, as the head was rotated further from the midline, the amount of overlap between the IJV and CA increased from 2–3 mm to ~5 mm, which corresponded with an increased percentage overlap from 20%–30% to as much as 50% (Table III).

## DISCUSSION

The anatomical variation in our population showed similarity to that of Western populations. In a study originating from the USA, 9.4% of patients had anatomical features of IJV that would make central venous catheterisation insertion difficult.<sup>(5)</sup> In this study by Denys and Uretsky, 5% of patients had IJV widths  $< 7$  mm and another 4.4% had either thrombosed or absent IJV.<sup>(5)</sup> In a European study involving ultrasonography-guided IJV catheterisation in 493 patients, Mey et al reported that 12.1% of patients had IJV diameters  $\leq 7$  mm.<sup>(6)</sup> In these patients, the small vein diameter was associated with a catheterisation failure rate of 14.9% and a complication rate of 8.5%. This compared to a failure rate of 3.9% and a complication rate of 3.8% in patients with IJV diameters  $> 7$ –10 mm. In comparison, we found that 15% of our patients had IJVs with widths  $\leq 7$  mm. However, when we considered only the right IJV, 10% of our patients had IJV diameters  $\leq 7$  mm, which is similar in frequency to that of

the Western studies mentioned above, despite the smaller body sizes of our patients. We had no patients with thrombosed or absent IJV.

The right IJV was as big as or bigger than the left IJV in 74% of our patients. This is fortuitous, as the right IJV offers a straighter and more direct path to the superior vena cava and right atrium. The apex of the right lung is also lower than the left, which decreases the risk of creating a pneumothorax as compared to the left IJV. It is also potentially possible to injure the thoracic duct during left IJV catheterisation. The right IJV is a more familiar site for catheterisation for most clinicians, and having a bigger target certainly increases the odds of successful catheterisation. However, this also means that having to switch to the left IJV after unsuccessful right IJV catheterisation would present even greater difficulty for clinicians, something that many clinicians would have experienced in their clinical practice. In this study, the percentage of potentially difficult catheterisation of the left IJV was twice that of the right IJV.

Even if the size of the IJV were adequate, one cannot rely on the external landmark technique alone for successful catheterisation. Firstly, the expected relationship between IJV and CA, namely that the CA is medial and deep to the IJV, was only true 73%–83% of the time. This exposes 20%–25% of patients to the possibility of CA puncture even if a technically perfect catheterisation attempt based on anatomical landmarks is performed. Secondly, the simulated needle path intersected the middle 80% of the IJV in only 70% of the attempts. We believe that needling the middle 80% of the vein is important because the insertion of the guide-wire would more likely be successful when this occurs. In our anecdotal experience, missing the middle 80% occasionally results in an inability to thread the guide-wire despite being able to aspirate blood well. This study also showed how shallow the IJV is in most patients, with the centre of the IJV averaging 14 mm below the skin. With the AP diameter of the IJV typically only 7–9 mm in the supine patient, it would be easy to puncture structures below the IJV once the needle depth is greater than 20 mm. Indeed, with the use of ultrasonography for reducing direct CA punctures, there have been increased concerns about complications arising from posterior wall penetration by needles.<sup>(9,10)</sup> This risk is compounded by over-rotation of the head and neck.

In our study, we have shown that rotation to 60° significantly increased the overlap of the IJV over the CA. These findings concur with reports in the literature<sup>(11)</sup> and reinforce the need to avoid excessive head and neck rotation during IJV catheterisation. The findings of this study support the routine use of ultrasonography to guide IJV catheterisation. In the UK, the National Institute for Clinical Excellence recommends the use of ultrasonography guidance in all elective patients.<sup>(2)</sup> Despite the wealth of intuitive and inferential data on the benefits of using ultrasonography, such as that presented in this report, its routine use is encouraged but

not mandatory in our institution. The use of ultrasonography devices would help clinicians identify patients with potentially difficult catheterisation and institute appropriate management strategies. These strategies may include attempts to increase the size of the IJV by increasing the Trendelenburg tilt, getting the patient to do a Valsalva breath-hold or simply by giving fluids. Another strategy would be to have an experienced clinician perform potentially difficult catheterisations, as this has also been shown to increase the chances of successful catheterisation and decrease the associated complications.<sup>(7)</sup> Alternatively, clinicians may look for other sites for catheterisation such as the subclavian or femoral veins.

In conclusion, anatomical variations may potentially play a significant role in determining the success of IJV catheterisation and in reducing catheterisation-associated complications. We have shown that anatomical variations that make it more difficult to catheterise the IJV and increase the risk of CA puncture are not uncommon in patients who appear to have anatomically normal necks. The right IJV is easier to catheterise than the left IJV, and care should be taken not to rotate the head and neck beyond 30° from the midline. It is also important to note the depth of needle insertion, as the IJV was found to be very superficial in our patients. Most importantly, the findings of this study support the use of ultrasonography to guide catheterisation in every patient, not only to identify difficult anatomical variations but also to increase the likelihood of a successful cannulation with reduced complication risks.

## REFERENCES

1. McGee DC, Gould MK. Preventing complications of central venous catheterisation. *N Engl J Med* 2003; 348:1123–33.
2. National Institute for Clinical Excellence. Guidance on the use of ultrasound locating devices for placing central venous catheters. Technology Appraisal Guidance No. 49, September 2002 [online]. Available at: [guidance.nice.org.uk/TA49/Guidance/pdf/English](http://guidance.nice.org.uk/TA49/Guidance/pdf/English). Accessed August 1, 2011.
3. Higgs ZCJ, Macafee DAL, Braithwaite BD, Maxwell-Armstrong CA. The Seldinger technique: 50 years on. *Lancet* 2005; 366:1407–9.
4. Karakitsos D, Labropoulos N, De Groot E, et al. Real-time ultrasound-guided catheterisation of the internal jugular vein: a prospective comparison with the landmark technique in critical care patients. *Crit Care* 2006; 10:R162.
5. Denys BG, Uretsky BF. Anatomical variations of internal jugular vein location: impact on central venous access. *Crit Care Med* 1991; 19:1516–9.
6. Mey U, Glasmacher A, Hahn C, et al. Evaluation of an ultrasound-guided technique for central venous access via the internal jugular vein in 493 patients. *Support Care Cancer* 2003; 11:148–55.
7. English IC, Frew RM, Pigott JF, Zaki M. Percutaneous cannulation of the internal jugular vein. *Thorax* 1969; 24:496–7.
8. WHO Expert Consultation. Appropriate body-mass index for Asian populations and its implications for policy and intervention strategies. *Lancet* 2004; 363:157–63.
9. Blaivas M, Adhikari S. An unseen danger: frequency of posterior wall penetration by needles during attempts to place internal jugular vein central catheters using ultrasound guidance. *Crit Care Med* 2009; 37:2345–9.
10. Levitov AB, Aziz S, Slonim AD. Before we go too far: ultrasound-guided central catheter placement. *Crit Care Med* 2009; 37:2473–4.
11. Sulek CA, Gravenstein N, Blackshear RH, Weiss L. Head rotation during internal jugular vein cannulation and the risk of carotid artery puncture. *Anesth Analg* 1996; 82:125–8.