

Hybrid surgical management of a saccular aneurysm of the internal jugular vein

Weiliang *Chua*¹, MBBS, MRCS, Germaine *Xu*², MBBS, MRCS, Shin Chuen *Cheng*³, MBBS, FRCS

ABSTRACT Internal jugular vein saccular aneurysms are rare. Surgical management is indicated when there is a risk of rupture. We recommend a hybrid procedure combining endovascular and open techniques. We report the case of a 77-year-old female patient with a saccular aneurysm of the internal jugular vein, which was excised with combined endovascular and vascular techniques.

Keywords: internal jugular vein, saccular aneurysm
Singapore Med J 2012; 53(5): e90–e91

INTRODUCTION

Saccular aneurysms of the internal jugular vein (IJV) are rare, as opposed to fusiform aneurysms found in the paediatric population. Accurate diagnosis may be obtained with contrast-enhanced computed tomography (CT) imaging and digital subtraction venograms. Surgical management is recommended due to the rare but serious complication of rupture or pulmonary embolism. Indications for operative interventions for a saccular aneurysm of the IJV include the risk of rupture, compressive symptoms or thrombus within the aneurysm. A hybrid procedure, including open and endovascular techniques, is recommended so as to minimise intra-operative blood loss and limit dissection required around the neck region.

CASE REPORT

A 77-year-old woman presented to the general surgical outpatient department with a six-month history of a palpable mass in the right posterior triangle of the neck. The mass was 6 cm in diameter along the lower half of the posterior border of the right sternocleidomastoid muscle. Clinical examination revealed that the mass was compressible, filled up upon lying down and reduced in size while sitting upright. Contrast-enhanced CT imaging of the neck was performed, which revealed a saccular venous aneurysm of 6 cm diameter arising from the junction of the right subclavian vein (SCV) and IJV (Fig. 1). The patient denied any history of trauma, neck surgery or vessel cannulation.

Surgery was offered to the patient due to the risk of rupture and discomfort over the lump. A planning digital subtraction venogram confirmed that the feeding vessels were arising from the IJV, in close proximity to the proximal SCV (Fig. 2). No thrombus was seen within the aneurysm sac. During the operation, an uphill puncture of the right common femoral vein was made. An endovascular balloon (6 mm × 40 mm) was used

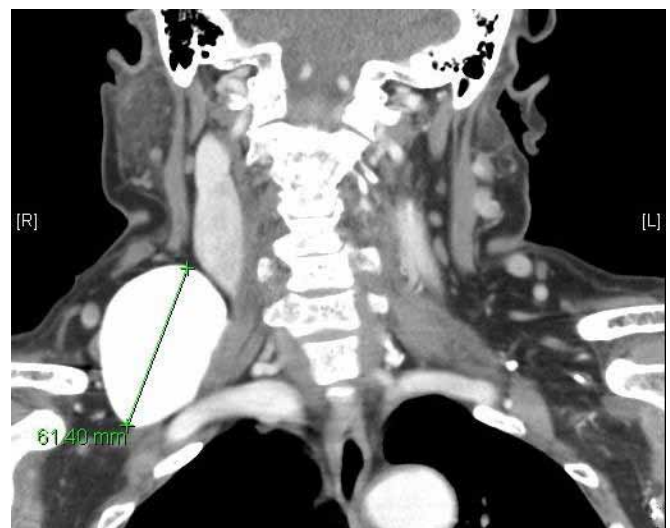

Fig. 1 Contrast-enhanced CT image shows a 6-cm aneurysm in the right neck.

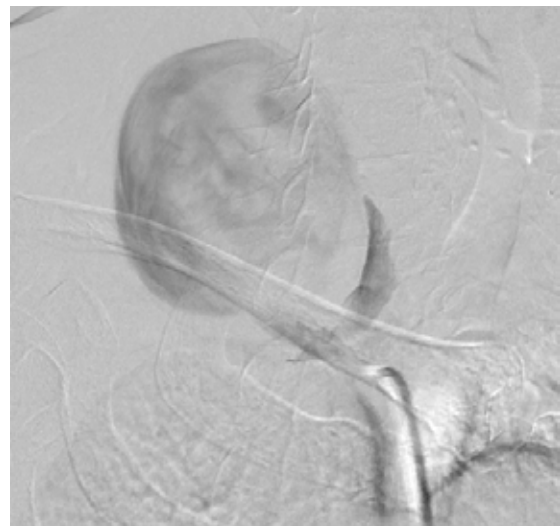


Fig. 2 Digital subtraction venography confirms the anatomical location of the aneurysm adjacent to the internal jugular vein.

¹Department of Orthopaedic Surgery, National University Hospital, ²Department of General Surgery, Khoo Teck Puat Hospital, ³Department of General Surgery, Tan Tock Seng Hospital, Singapore

Correspondence: Dr Chua Weiliang, Registrar, Department of Orthopaedic Surgery, National University Hospital, 5 Lower Kent Ridge Road, Singapore 119074. wei_liang_chua@nuhs.edu.sg

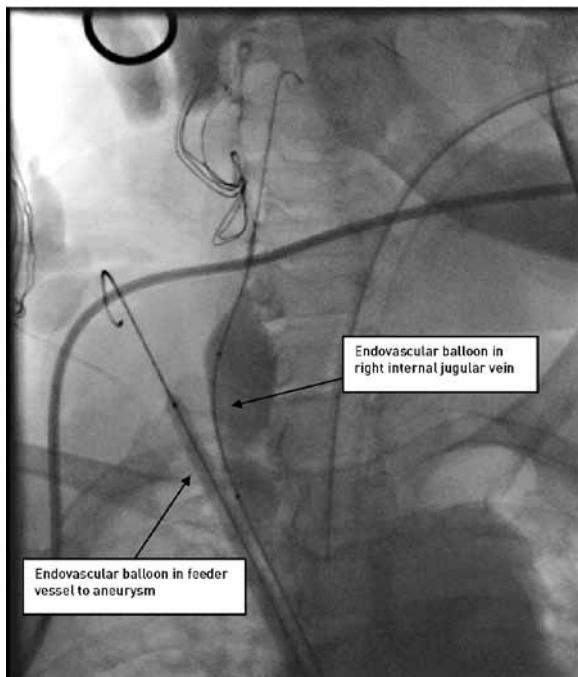


Fig. 3 Intra-operative venogram shows an endovascular balloon in the feeder vessel and internal jugular vein.

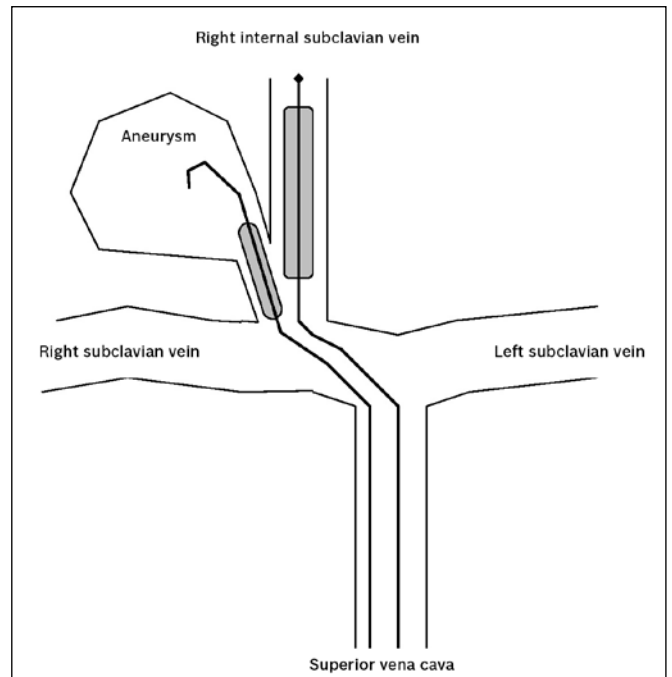


Fig. 4 Line diagram shows the placement of endovascular balloons.

to control the feeding vessel arising from the IJV (Figs. 3 & 4). Subsequently, a 4-cm skin incision was made at the level of the feeder vessel for ligation. During the dissection of the feeder vessel, the aneurysm was inadvertently torn as it arose at the junction of the IJV and SCV. There was difficult venous bleeding, which was subsequently controlled by endovascular balloons (25 mm × 40 mm) in the right IJV and SCV, allowing suture haemostasis. A larger skin incision was made to excise the aneurysm near the neck with transfixation. Final check venogram revealed a patent right IJV and SCV. The patient was under observation for one day in the intensive care unit. She had an uncomplicated recovery and was discharged on postoperative Day 5. Histopathological analysis of the specimen was consistent with a venous aneurysm.

DISCUSSION

Saccular aneurysms of the IJV are extremely rare, with only three previous reports in the English literature,⁽¹⁻³⁾ none of which discussed the surgical technique for aneurysm excision. Most previous reports are of fusiform venous aneurysms (phlebectasia) in the paediatric population due to congenital malformation.^(4,5) In addition to this case, we also report a novel surgical procedure using a combination of endovascular techniques to obtain good vascular control as well as a minimally invasive resection.

Jugular venous aneurysms usually present as a painless neck swelling. Patients may, on history-taking, volunteer critical points

such as the mass enlarging during daily activities that simulate a valsava manoeuvre, or when coughing, breath-holding or sneezing. Although most venous aneurysms have no symptoms, possible complications such as pulmonary embolism and aneurysm rupture may occur. Due to their rarity and anatomical location, clinical diagnosis can be difficult. However, with a high index of suspicion and appropriate imaging techniques such as CT or venography, accurate diagnosis and meticulous pre-operative planning are possible.

Our hybrid surgical procedure allowed us to obtain good vascular control of the feeder vessels prior to resection of the aneurysm. Additionally, an open vascular repair may have required a sternotomy with or without clavicle excision. The friable nature of the aneurysm wall and the nature of venous bleeding made suture repair of the venous bleeding difficult. Without endovascular control, this procedure would have been more hazardous.

REFERENCES

1. Lee HY, Yoo SM, Song IS, Yu H, Lee JB. Sonographic diagnosis of a saccular aneurysm of the internal jugular vein. *J Clin Ultrasound* 2007; 35:94-6.
2. Hopsu E, Tarkkanen J, Vento SI, Pitkäranta A. Acquired jugular vein aneurysm. *Int J Otolaryngol* 2009;535617.
3. Wen C, Liu R, Liu M, et al. Saccular neck venous aneurysm on color duplex sonography: an analysis of 12 cases. *Clin Imaging* 2009 33:424-9.
4. Paleri V, Gopalakrishnan S. Jugular phlebectasia: theory of pathogenesis and review of literature. *Int J Pediatr Otorhinolaryngol* 2001; 57:155-9.
5. al-Dousary S. Internal jugular phlebectasia. *Int J Pediatr Otorhinolaryngol* 1997; 38:273-80.