

# Tracheal schwannoma as a mimic of bronchial asthma

Rajesh Thomas<sup>2</sup>, MD, FRACP, Devasahayam J Christopher<sup>2</sup>, DNB, FCCP, Balamugesh Thangakunam<sup>2</sup>, MD, DM, Rekha Samuel<sup>1</sup>, MD

**ABSTRACT** Primary tracheal tumours are rare and less frequently observed than bronchial tumours. Primary neurogenic tumours of the trachea as schwannomas or neurilemmomas are extremely uncommon. We report a tracheal schwannoma in a female patient who presented with breathlessness and wheeze, and she was being treated for asthma. Flexible bronchoscopy revealed a large pedunculated tracheal mass and biopsy confirmed schwannoma. She was treated with laser ablation with partial reduction of the tumour. Subsequently, she was lost to follow-up, although resection of the tumour with tracheal reconstruction was planned.

Keywords: asthma, schwannoma, tracheal neoplasm  
Singapore Med J 2012; 53(5): e95–e96

## INTRODUCTION

Tracheal schwannomas are extremely rare tumours. Since tracheal tumours may present with features of airway obstruction, the diagnosis can be easily missed or delayed, and the patient may be mistakenly treated for bronchial asthma.

## CASE REPORT

A 37-year-old woman presented with a history of productive cough and progressive breathlessness associated with wheeze for the past three months. She also complained of three episodes of streaky haemoptysis during that period. She had been diagnosed to have bronchial asthma by a local physician, and was treated with inhaled corticosteroids and bronchodilators without significant symptomatic relief. On examination, she was dyspnoeic at rest and had noisy breathing suggestive of stridor, indicating a central airway obstruction. Auscultation of the chest revealed bilateral inspiratory and expiratory wheeze. Other systemic examination was unremarkable.

Chest roentgenogram (Fig. 1) appeared normal at the first examination; however, a close review revealed a rounded opacity superimposed on the air-column of the mid-trachea. Spirometry did not reveal any obstructive ventilatory defect, but the flow-volume loop showed flattening of the inspiratory limb (Fig. 2) and the forced expiratory volume in 1 second/peak expiratory flow rate ratio was more than 10 ml/L/min, suggestive of a variable extra-thoracic upper airway obstruction. Flexible bronchoscopy showed a large, rounded, pedunculated mass (Fig. 3a) in the mid-trachea, almost completely occluding the lumen (more than 90%). Histopathological examination of the bronchoscopic biopsy revealed a tumour composed of loose fascicles of spindle-shaped cells with indistinct cytoplasm and oval nuclei displaying nuclear palisading in foci to form Verocay bodies, consistent with benign spindle cell neoplasm as schwannoma (Fig. 4).

The patient underwent Nd-YAG laser ablation of the tumour through a rigid bronchoscope under general anaesthesia, result-

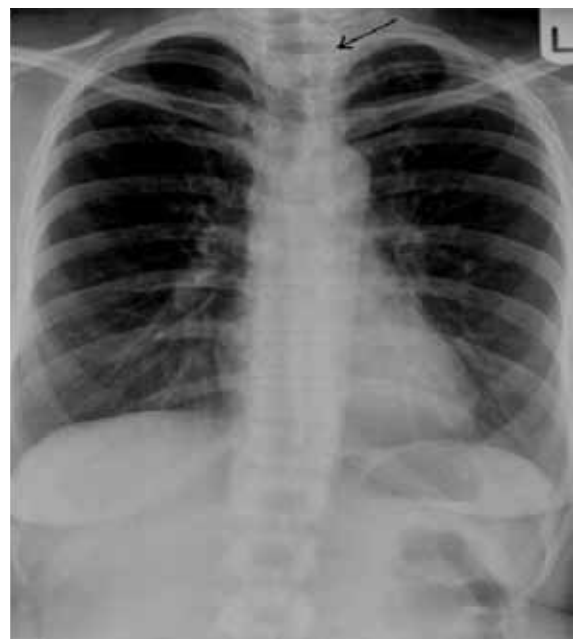

Fig. 1 Chest roentgenogram shows a rounded opacity superimposed on the air-column of the mid-trachea (arrow).

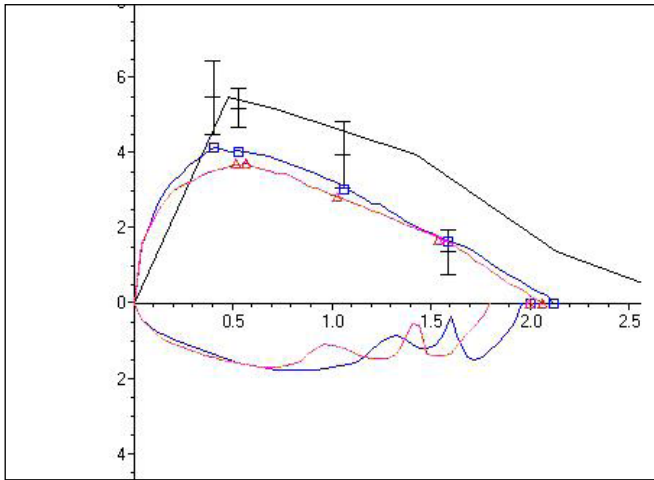
ing in partial reduction in tumour size (Fig. 3b). The tracheal lumen was opened up by approximately 50%, and there was significant symptomatic improvement. She had to undergo two further sessions of laser ablation due to local tumour recurrence. Subsequently, although computed tomography (CT) imaging followed by circumferential resection of the tumour with tracheal reconstruction was planned, the patient was lost to follow-up.

## DISCUSSION

Primary tracheal tumours are rare and less frequently observed than bronchial tumours.<sup>(1)</sup> The majority of tracheal tumours are malignant,<sup>(2)</sup> while benign tumours are much less frequently encountered. Primary neurogenic tumours of the trachea (schwannomas or neurilemmomas) are extremely uncommon,

<sup>1</sup>Department of Pathology, <sup>2</sup>Department of Pulmonary Medicine, Christian Medical College, Tamil Nadu, India

**Correspondence:** Dr DJ Christopher, Professor and Head, Department of Pulmonary Medicine, Christian Medical College, Vellore 632004, Tamil Nadu, India. djchris@cmcvellore.ac.in



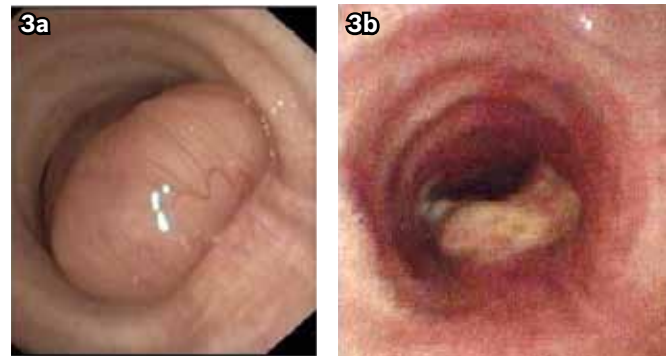
**Fig. 2** Flow-volume loop shows flattening of the inspiratory limb, which is suggestive of variable extra-thoracic upper airway obstruction.

and only around 23 cases have been previously reported.<sup>(3)</sup> According to one case series, tracheal schwannomas comprised only three of 185 benign tumours of the tracheo-bronchial tree.<sup>(4)</sup> In another large series of 1,664 patients with pulmonary neoplasms observed in 1967–1980, only four neurogenic tumours were identified (0.2%), of which three were benign neurilemmomas and one was a malignant schwannoma.<sup>(5)</sup>

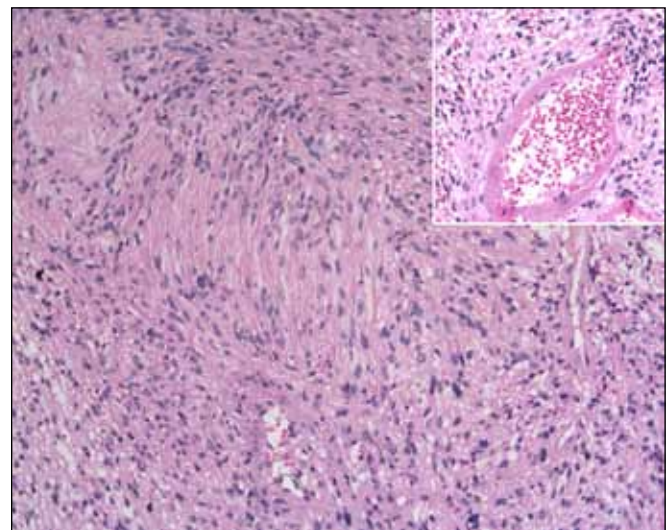
Tracheal schwannomas usually affect men below 50 years of age.<sup>(5)</sup> Due to the intra-luminal nature of the tumour, symptoms of airway obstruction predominate. Diagnosis is usually made by bronchoscopy, but CT and magnetic resonance (MR) imaging are increasingly used to delineate tumour size, location and extension.<sup>(3,6)</sup> However, these features are not specific for a schwannoma. Nevertheless, CT imaging is accurate in defining the location, degree of intra- and extratracheal extension and tumour size. MR imaging has the advantage of sectioning the trachea in both coronal and sagittal planes; thus, the location and extension of the tumour can be more precisely defined.<sup>(3)</sup>

The choice of treatment should be influenced by the endoscopic presentation of the tumour (i.e. pedunculated or sessile), the risk of tracheal resection, and the presence or absence of extratracheal component.<sup>(7)</sup> The standard management of tracheal tumours is circumferential resection with tracheal reconstruction, which often completely cures a schwannoma.<sup>(1)</sup> Alternatively, endoscopic laser resection and bronchoscopic surveillance are acceptable approaches to the management of pedunculated tumours without extratracheal component,<sup>(7)</sup> particularly if the patient is not an operable candidate. However, there is a risk of bleeding during bronchoscopic laser resection and tumour recurrence.

Our patient had significant relief of symptoms and partial resection of the tumour following laser treatment; however, the symptoms recurred subsequently. In the light of this, surgical resection and tracheal reconstruction was planned to offer permanent cure, but unfortunately, she was lost to follow-up.



**Fig. 3** (a) Flexible bronchoscopic image shows a pedunculated mass in mid-trachea, almost completely occluding the lumen (> 90%). (b) Bronchoscopic image post laser ablation shows a partial reduction in tumour size.



**Fig. 4** Photomicrograph of bronchial biopsy shows fascicles of spindle-shaped cells with indistinct cytoplasm and oval nuclei displaying nuclear palisading, consistent with schwannoma (Haematoxylin & eosin,  $\times 200$ ). Inset shows blood vessels with perivascular hyaline collection.

In conclusion, a schwannoma is a rare benign tracheal tumour. The possibility of a tracheal tumour should be considered in patients who present with symptoms of airway obstruction, especially if it is of recent onset and associated with symptoms like haemoptysis, or if it is unresponsive to conventional therapy.

## REFERENCES

- Dorfman J, Jamison BM, Morin JE. Primary tracheal schwannoma. *Ann Thorac Surg* 2000; 69:280-1.
- Grillo HC, Mathisen DJ. Primary tracheal tumors: treatment and results. *Ann Thorac Surg* 1990; 49:69-77.
- Righini CA, Lequeux T, Laverriere MH, Reyt E. Primary tracheal schwannoma: one case report and a literature review. *Eur Arch Otorhinolaryngol* 2005; 262:157-60.
- Shah H, Garbe L, Nussbaum E, et al. Benign tumors of the tracheo-bronchial tree. Endoscopic characteristics and role of laser resection. *Chest* 1995; 107:1744-51.
- Roviaro G, Montorsi M, Varoli F, Binda R, Cecchetto A. Primary pulmonary tumours of neurogenic origin. *Thorax* 1983; 38:942-5.
- Ikezoe J, Sone S, Higashihara T, et al. Schwannoma of the trachea. *Eur J Radiol* 1986; 6:65-6.
- Rusch VW, Schmidt RA. Tracheal schwannoma: management by endoscopic laser resection. *Thorax* 1994; 49:85-6.