

Reversible recurrent laryngeal nerve palsy in acute thyroiditis

Meihuan Chang¹, MBBS, James Boon Kheng Khoo², FRCR, FAMS, Hiang Khoon Tan², FRCS, PhD

ABSTRACT First reported by Nager in 1927, unilateral vocal cord paralysis associated with thyroid disease suggests the malignant and irreversible nature of the thyroid lesion. This condition is rarely seen in benign thyroid diseases, and the function of the vocal cord does not usually return. We present a 54-year-old woman with a history of right hemithyroidectomy for benign thyroid nodule, who had an episode of subacute thyroiditis associated with unilateral vocal cord paralysis. The patient was treated with intravenous antibiotics and underwent a completion thyroidectomy. Post operation, her vocal cord function recovered successfully. Unilateral vocal cord paralysis can be seen in thyroiditis, and this can be reversed with steroids and antibiotics. If surgery is necessary, care must be taken to preserve the recurrent laryngeal nerve.

Keywords: reversible vocal cord paralysis, thyroiditis
Singapore Med J 2012; 53(5): e101–e103

INTRODUCTION

Unilateral vocal cord paralysis can result from surgical iatrogenic injuries, malignant invasion of the recurrent laryngeal or vagus nerve and blunt trauma to the neck or chest.⁽¹⁾ Otherwise, it is idiopathic and presumptively secondary to viral infection or inflammation. Vocal cord paralysis in thyroid diseases is classically and most commonly associated with malignancy of the thyroid. In a review of 1,200 patients, similar paralysis in benign diseases has been reported at an incidence of 0.69% compared to 11.3% in malignancies.⁽²⁾ The most common benign condition responsible for vocal cord paralysis is multinodular goitre, and other causes include adenomas, Grave's disease, and Hashimoto's and subacute thyroiditis.^(3,4) We report vocal cord paralysis in association with acute thyroiditis in a female patient who recovered spontaneously post treatment.

CASE REPORT

A 54-year-old Chinese woman presented with a ten-year history of thyroid swelling. The swelling had acutely increased in size for the past two months. This was associated with fever, pain and hoarseness of voice. The patient had a previous right hemithyroidectomy for a benign thyroid nodule 20 years ago. On examination, there was a warm, erythematous and tender thyroid swelling on the left, displacing the trachea to the right. Nasal endoscopy showed reduced mobility of the left vocal cord with a patent airway and no laryngeal oedema. Blood investigations revealed a mildly elevated total white cell count ($11.8 \times 10^9/L$; normal range [NR] $4.0\text{--}10.0 \times 10^9/L$) and a normal differential count and high C-reactive protein (276 mg/L; NR 0.2–8.8 mg/L). Thyroid function indices revealed raised serum free thyroxine (17.1 pmol/L; NR 8.8–14.4 pmol/L) and normal thyroid stimulating

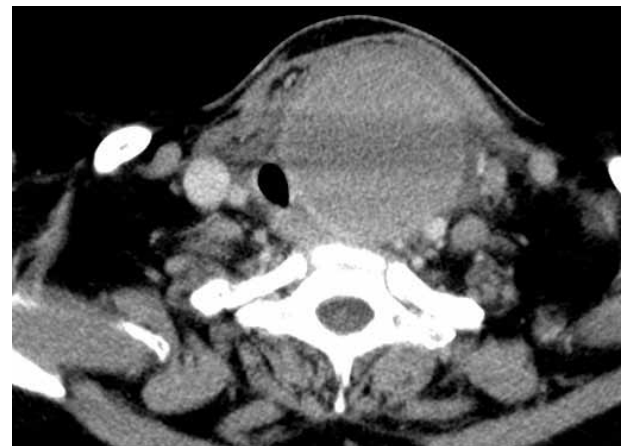

Fig. 1 CT image of the neck shows a rim-enhancing cystic lesion arising from the left lobe of the thyroid.

hormone (2.74 mU/L; NR 0.65–3.70 mU/L). The patient had elevated thyroglobulin and thyroglobulin antibodies levels at 61.0 mg/L (NR 2.0–70.0 $\times 10^3$ mg/L) and 2,477 U/mL (NR 0.0–6.0 U/mL), respectively. Computed tomography (CT) imaging of the neck and thorax showed a large cystic lesion arising from the left lobe of the thyroid with trachea deviation (Fig. 1). It measured 5.9 cm \times 5.9 cm \times 7.0 cm in size, with no intrathoracic extension. There was no evidence of inflammation of the thyroid. Fluid was noted in the retropharyngeal space, communicating with the left visceral space around the thyroid (Fig. 2). A few small air inclusions were observed within the fluid with no rim enhancement. There was no evidence of foreign body.

The biochemical picture was pathognomonic of autoimmune thyroiditis. In view of the findings of a possible abscess and raised C-reactive protein, the patient was started on intravenous augmentin and metronidazole for treatment of superimposed

¹Department of General Surgery, Singapore General Hospital, ²Department of Oncologic Imaging, ³Department of Surgical Oncology, National Cancer Centre, Singapore

Correspondence: Dr Tan Hiang Khoon, Senior Consultant Surgeon, Department of Surgical Oncology, National Cancer Centre Singapore, 11 Hospital Drive, Singapore 169610. Tan.H.K@ncss.com.sg

bacterial infection. Drainage of the abscess with completion thyroidectomy was planned immediately in order to eradicate the source of sepsis and relieve local pressure on the displaced trachea and recurrent laryngeal nerve. Intubation was difficult due to oedematous endolarynx. Intra-operatively, dense adhesion tissue was noted around the thyroid, evidencing acute thyroiditis. Parapharyngeal oedema was found, but no abscess or foreign body was seen. Left thyroidectomy was performed with preservation of the left recurrent laryngeal nerve. On postoperative Day 3, prednisolone was started for autoimmune thyroiditis, and the patient was extubated on postoperative Day 5.

Cultures of the blood and thyroid fluid did not grow any organisms. The left hemithyroidectomy specimen showed benign thyroid tissue with cystic change and acute suppurative inflammation, which was consistent with bacterial thyroiditis. The inflammatory infiltrate was noted to track out of the thyroid gland into the surrounding skeletal muscle. The patient was discharged with thyroxine replacement after completing one week of intravenous antibiotics. She was seen as an outpatient two weeks post operation, and had since regained her normal voice. Nasal endoscopy confirmed that her vocal cords were moving well bilaterally.

DISCUSSION

The recurrent laryngeal nerve plays a critical role in vocal cord mobility, as its motor branch supplies the four intrinsic laryngeal muscles: the thyroarytenoid, the lateral and posterior cricoarytenoid, and the transverse and oblique arytenoid. Vocal cord immobility also occurs in vagal and superior laryngeal nerve disruption. The vagus contains axons of the recurrent laryngeal nerve, and the superior laryngeal nerve innervates the cricothyroid muscle. In thyroid diseases, vocal cord immobility is a complication that arises due to the proximity of the recurrent laryngeal nerve to the thyroid. The left recurrent laryngeal nerve branches off the left vagus as it crosses anterior to the aortic arch in the mediastinum.⁽⁵⁾ It loops medially under the aorta and ascends within the tracheoesophageal groove. The right vagus gives off the right recurrent laryngeal nerve at the division of the innominate artery, and loops around the right subclavian artery and ascends along the superior lobe pleural. The right recurrent laryngeal nerve approaches the tracheoesophageal groove behind the common carotid artery, often reaching it at the cricothyroid joint. The two nerves then come into close contact with the inferior pole of each lobe at or near the tracheoesophageal groove.

In the literature, there are six reported cases of vocal cord paralysis diagnosed via laryngoscopy that is associated with thyroiditis,⁽⁶⁻¹¹⁾ out of which only two patients recovered fully from vocal cord paralysis after treatment. One patient had normal vocal fold mobility after three days of steroid treatment.⁽¹⁰⁾ In all six patients, normal mobility was confirmed via direct visualisation, while in two other studies,^(8,9) this was deduced via return of normal voice. The possible mechanisms for temporary

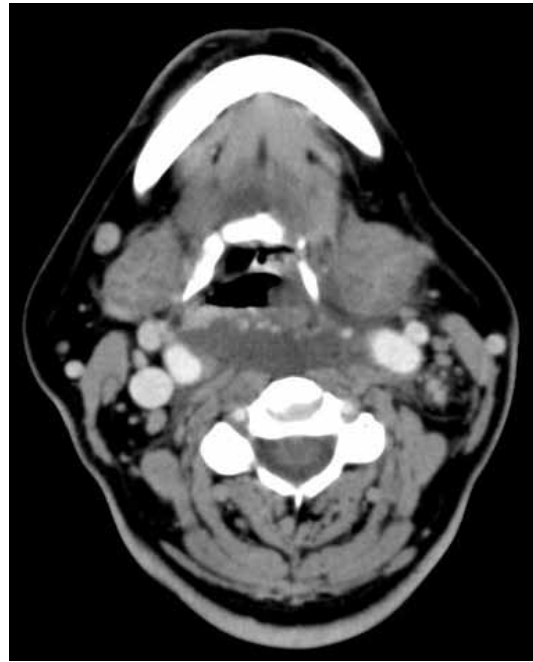


Fig. 2 CT image of the neck shows the retropharyngeal space with fluid, communicating with the left visceral space around the thyroid.

paralysis of the vocal cord include compression of the recurrent laryngeal nerve and/or its blood supply between the goitre and cervical spine or trachea, stretching of the nerve causing neuropraxia, perinodular inflammation producing minute artery thrombosis and fibrosis involving the nerve or direct involvement in thyroiditis.^(2,12) This would mean surgical removal of the goitre, and steroid administration would be adequate for nerve recovery. Nerve palsy was, however, permanent in the three cases treated with these methods,^(6,7,11) and in one of these cases,⁽⁷⁾ the onset of vocal cord palsy was after three weeks of steroid treatment for thyroiditis. Therefore, chronic perineural fibrosis is likely the main mechanism responsible for permanent nerve palsy. In our patient, the tracheal deviation and fluid seen on CT imaging of the neck (Fig. 2) suggests that relief of pressure on the left recurrent laryngeal nerve and resolution of the surrounding inflammation secondary to thyroiditis were the possible aetiologies for this patient's recovery. The decreased mobility of the vocal cords in this patient was due to laryngeal oedema.

Another interesting finding in the present case is the presence of retropharyngeal oedema seen on CT imaging of the neck (Fig. 2), which was consistent with the intra-operative finding. In view of the fluid and air inclusions, an abscess was an important differential, but this was proven to be pharyngeal oedema intra-operatively. Two case studies have documented laryngeal oedema in thyroiditis,^(13,14) likely due to local extension of inflammation. This is the first report of retropharyngeal oedema in thyroiditis in the literature. We postulate that local compression of the surrounding lymphatics by the enlarged thyroid had obstructed fluid clearance from the pharynx in our patient, which resulted in retropharyngeal oedema. Acute inflammatory process with thrombosis of the surrounding vessels and increased vessel permeability may have also played a role.

Our patient was started on steroids postoperatively for underlying chronic thyroiditis, as they have been shown to lower serum thyroglobulin levels.⁽¹⁵⁾ However, we did not start her on steroids pre-operatively, as management of the acute secondary infection had taken precedence. In addition, there is currently no consensus with regard to the timing of steroid treatment for thyroiditis in the existing literature, especially when surgical intervention is not required.

Thyroiditis is a rare cause of vocal cord immobility, but it can be reversible. Corticosteroids should be the first-line treatment, together with antibiotics. When thyroidectomy is indicated, care must be taken to identify and preserve the recurrent laryngeal nerve.

REFERENCES

1. Fitzpatrick PC, Miller RH. Vocal cord paralysis. *J La State Med Soc* 1998; 150:340-3.
2. Holl-Allen RT. Laryngeal nerve paralysis and benign thyroid disease. *Arch Otolaryngol* 1967; 85:335-7.
3. Rowe-Jones JM, Rosswick RP, Leighton SE. Benign thyroid disease and vocal cord palsy. *Ann R Coll Surg Engl* 1993; 75:241-4.
4. Collazo-Clavell ML, Gharib H, Maragos NE. Relationship between vocal cord paralysis and benign thyroid disease. *Head Neck* 1995; 17:24-30.
5. Myssiorek D. Recurrent laryngeal nerve paralysis: anatomy and etiology. *Otolaryngol Clin North Am* 2004; 37:25-44, v.
6. Langevitz P, Cabili S. Persistent vocal cord paralysis in subacute thyroiditis. *Postgrad Med J* 1983; 59:726-7.
7. Kallmeyer JC, Hackmann R. Vocal cord paralysis associated with subacute thyroiditis. A case report. *S Afr Med J* 1985; 67:1064.
8. Boyd CM, Esclamado RM, Telian SA. Impaired vocal cord mobility in the setting of acute suppurative thyroiditis. *Head Neck* 1997; 19:235-7.
9. Yasmeeen T, Khan S, Patel SG, et al. Clinical case seminar: Riedel's thyroiditis: report of a case complicated by spontaneous hypoparathyroidism, recurrent laryngeal nerve injury, and Horner's syndrome. *J Clin Endocrinol Metab* 2002; 87:3543-7.
10. Dedivitis RA, Coelho LS. Vocal fold paralysis in subacute thyroiditis. *Braz J Otorhinolaryngol* 2007; 73:138.
11. Bukvic B, Diklic A, Zivaljevic V. Acute suppurative klebsiella thyroiditis: a case report. *Acta Chir Belg* 2009; 109:253-5.
12. Rueger RG. Benign disease of the thyroid gland and vocal cord paralysis. *Laryngoscope* 1974; 84:897-907.
13. Elin DM. [Observation of edema of the larynx in acute thyroiditis]. *Vestn Otorinolaringol* 1966; 28:86-7. Russian.
14. Heinemann M. [Supraglottal laryngeal edema in the course of acute thyroiditis]. *Dtsch Gesundheitsw* 1969; 24:2278-80. German.
15. Yamamoto M, Saito S, Sakurada T, et al. Effect of prednisolone and salicylate on serum thyroglobulin level in patients with subacute thyroiditis. *Clin Endocrinol (Oxf)* 1987; 27:339-44.