

Short-term multimodal phototherapy approach in a diabetic ulcer patient

Baskaran Chandrasekaran¹, MPT_H, MIAP, Remon Chettri², MPT_H, MIAP, Neha Agrawal¹, MPT_H, MIAP, Chandrakumar Sathyamoorthy¹, MPT_H, MIAP

ABSTRACT Foot ulcers increase morbidity and mortality in diabetic patients. Due to poor healing factors, surgical wound healing is questionable in diabetic patients. We report a patient with insulin-dependent diabetes mellitus, sensory neuropathy and microangiopathy, who had an infected stump of the right three middle digits and subsequent transmetatarsal amputation. The infected postoperative ulcer was treated with complex phototherapy, including laser and ultraviolet C (UVC) radiations. A total of 23 sessions of low-intensity laser therapy and UVC irradiation were administered over a five-week period. The infected surgical wound healed completely. During the three-month follow-up period, there was no recurrence of the ulcer, although the patient's metabolic profile remained unstable. Multimodal therapy combining UVC and laser may constitute a useful and side-effect-free alternative treatment modality for the induction of wound healing post metatarsal amputation in patients with unhealed diabetic ulcers.

Keywords: amputation, diabetic ulcer, healing, laser, phototherapy
Singapore Med J 2012; 53(6): e122–e124

INTRODUCTION

Foot ulcers are common limb- and life-threatening complications in patients with diabetes mellitus,⁽¹⁾ and they increase patients' morbidity and mortality.⁽²⁾ Unhealed foot ulcers subsequently result in amputation.^(3,4) Surgical healing of postoperative wounds is hindered due to poor healing factors that are inherent to diabetes mellitus itself. Apart from the poor healing factors, opportunistic infection, sensory loss and poor immunity also create an alarming risk of infective non-healing ulcers in diabetic patients.⁽⁵⁾ Physical modalities such as ultrasonography, laser and electrical stimulation have been used for the healing of diabetic ulcers.⁽⁶⁾ Ultraviolet radiations B and C (UVB and UVC) have also been used for infected ulcers.^(7,8) We report a diabetic patient whose infected ulcerated stump completely healed with short-term high-intensity phototherapy (combined laser and UVC). None of the earlier studies had reported the combined efficacy of laser and UVC on the short-term recovery of infected transmetatarsal amputation stump in a patient with diabetic ulcers.

CASE REPORT

Our patient was a 56-year-old man who was a known case of Type II diabetes mellitus for eight years. He had not been taking diabetic medications regularly all these years. For the past two years, he had been receiving oral hypoglycaemic drugs, namely velibo-03, vogibose and pioglitazone. He had initially experienced an itching, burning sensation on the distal plantar surface of the middle three digits of his right foot in December 2008. He had noted a sore on the plantar aspect of the second digit of the same foot after a week and a whitish discharge from

the right second digit few days later. The patient had undergone quick treatment with honey on the infected wound, after which he had noted a spread of pus formation in the third and fourth digits of his right foot. He had been hospitalised twice in 2009 for medical management. The sore had spread, and intolerable pain had caused a loss of mobility and affected his activities of daily living.

Unable to bear the discomfort, the patient finally underwent transmetatarsal amputation of the second, third and fourth digits of his right foot on February 8, 2010 under general anaesthesia after consulting a surgeon. Due to microangiopathy and sensory polyneuropathy, the wound showed poor healing factors (delayed closure) of the surgical stump (Fig. 1). On postoperative Day 5, the patient was febrile (101°C) and experiencing chills and rigors. His wound swab culture revealed a growth of *Pseudomonas (P.) aeruginosa* and *Staphylococcus (S.) aureus*, for which he was started on cefipime and almxo, respectively. Despite repeated debridement, wound healing was poor. Intolerable pain and swelling of the stump had restricted the patient's movement in the hospital. He was referred to the physiotherapy department for wound healing, reduction of pain and increasing mobility on February 12, 2010.

Physiotherapy assessment for the ulcerated stump was done on the following day. The patient's primary problems were pain on the stump, infection, delayed healing and wound closure. He was conscious, oriented and appeared to be well-nourished. The stump ulcer was regular in shape and red in colour. There was inadequate granulation with necrotic debris and blackish discolouration of the dorsum of the foot and around the stump.

¹Department of Physical Medicine and Rehabilitation, Kokilaben Dhirubhai Ambani Hospital, Mumbai, India, ²Department of Physiotherapy, Sikkim Manipal Institute of Medical Sciences, Sikkim, India

Correspondence: Mr Baskaran Chandrasekaran, Senior Physiotherapist, Pulmonary Rehabilitation, PSG Institute of Pulmonology, PSG Hospital, Peelamedu, Coimbatore 641004, Tamil Nadu, India. bass_99psg@yahoo.co.in

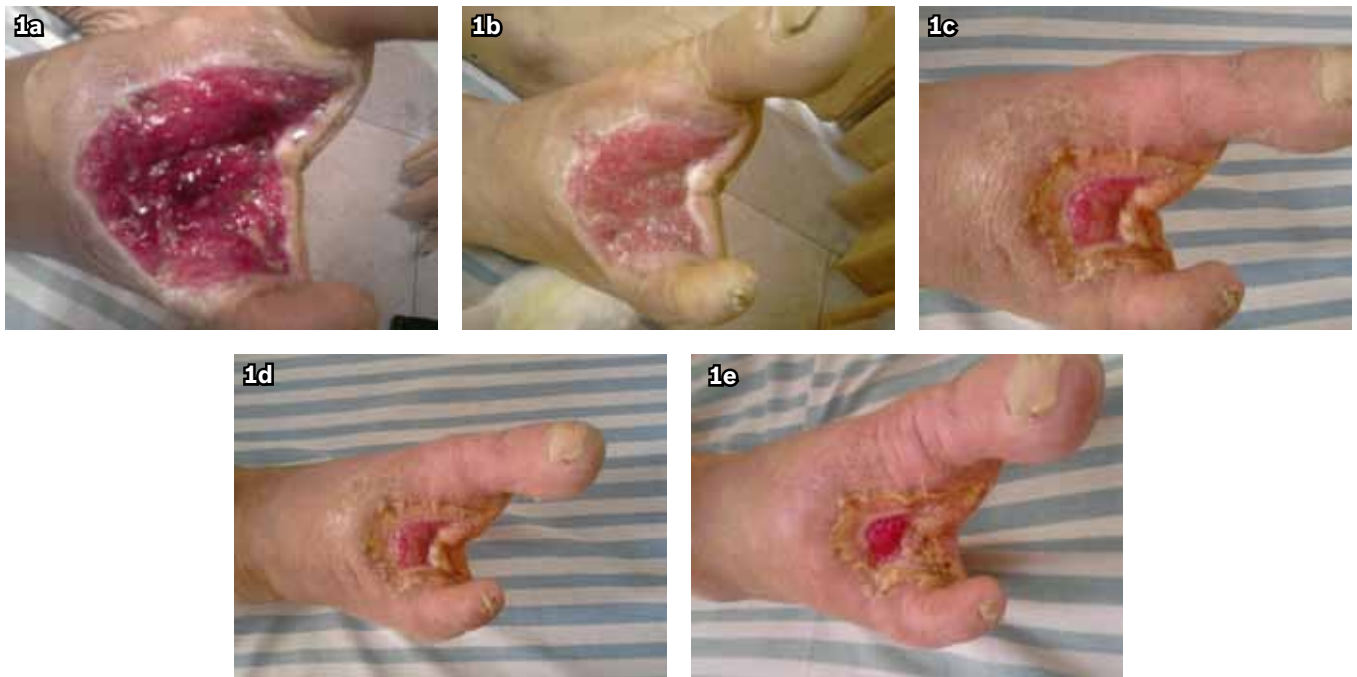


Fig. 1 Photographs show the infected open granulating surgical wound post phototherapy on (a) Day 1; (b) Day 5; (c) Day 15; (d) Day 20; and (e) Day 23.

The wound edges were dark grey, indicating an evolving necrosis of the stump site. The right foot was swollen. Hair loss was noted on the dorsum of the right foot, along with a foul-smelling odour and purulent discharge in the infected stump. Palpation revealed pitting oedema in the right foot above the stump, feeble pulsation in the right dorsalis pedis and tenderness (grade 3) around the stump. Ankle brachial index of the right side was 0.64, while that of the left side was 0.87. Sensory examination with the Semmes Weinstein filament 6.65 revealed anaesthetic regions in the lateral side of the plantar surface of the right foot. Range of motion examination on the right foot revealed painful calcaneal, talar restriction in supination and pronation movements. Motor examination revealed minimal decrease in strength in the right foot musculature compared to the left foot muscles. The patient was not given any total contact cast or splints. Non-weight-bearing walking with the aid of a walker was suggested by the surgeon.

For sterilisation of the wounds, UVC radiations were administered as they are bactericidal in nature, and have less harmful effects on the other biological tissues.⁽⁹⁾ Laser has been long known as a therapeutic modality for wound healing in diabetic ulcers due to its photo-biological effects on healing factors.⁽¹⁰⁾ We combined the two modalities as the patient had infected post-ulcerated amputation stump. He was started on a combined phototherapy approach consisting of UVC and laser on February 15, 2010. Both modalities were administered on the same day, with UVC in the first half and laser in the second half of the treatment days.

UVC was applied using a White Mercury Vapour Lamp (Model CRG 111) with 230 V AC \pm 10% 50 Hz (95% emission at 250 nm). The dosages were set in accordance with an earlier study.⁽⁸⁾ E1 dose was calculated to be 15 seconds at a lamp distance

of 2.5 cm and was administered over the red granulation tissue of the stump. E3 dose, calculated to be 90 seconds at a lamp distance of 2.5 cm, was applied to infected tissues with purulent discharge for sterilisation effect. A 2-mm thick layer of Vaseline was applied over the skin around the ulcer for sunscreen effect. As infection settled down and new granulation on the wound was noted, the dosage of E3 was reduced to E1. UVC was applied every day for the calculated E3 or E1 duration.

Laser treatment was applied using a 'Prometheus' P pen and cluster probe and was checked for its accuracy of output by the manufacturer. We administered treatment with two probes for our patient. The contact probe was used for the wound edges and a non-contact cluster probe was used for the wound bed. The contact probe had an 820-nm laser diode (beam spot diameter of 4 mm and average power of 25 mw). The power density was set at 140 mW/cm², pulse repetition rate at 2,500 pps (pulse duration of 200 ns) and energy density at 2 J/cm³ (treatment time of 20 seconds/spot). The multiprobe with eight luminous diodes was used, with four diodes having a wavelength of 660 nm and four having a wavelength of 880 nm. The power density was set at 120 mW/cm², pulse repetition rate at 5,000 pps (pulse duration of 160 ns) and energy density at 4 J/cm³.

The stump granulation had started on Day 12 of treatment. Wound culture of the stump was negative for *P. aeruginosa* and *S. aureus*. The stump was completely healed by Day 60 of the initial treatment. Follow-up two months after the initial assessment did not reveal any reappearance of ulcer in the patient. Sequential wound healing and remodelling is depicted in Figs. 2–5. The wound measurements by transparent tracings also showed a decrease in the wound area from 13.74 cm² to 0.825 cm² (60% improvement) during the two-month period (Figs. 6 & 7).

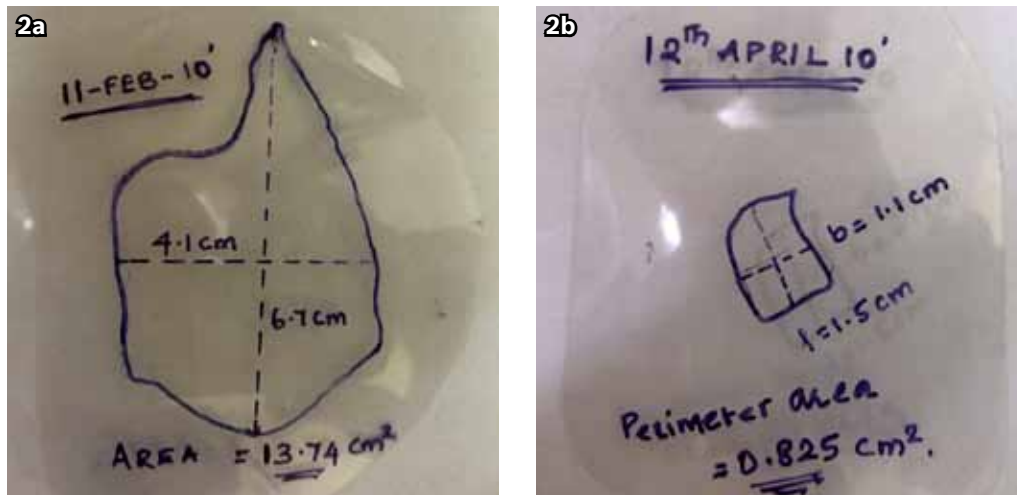


Fig. 2 Photographs of transparent tracing wound measurements on (a) February 11, 2010; and (b) April 12, 2010.

DISCUSSION

Previous studies have reported the physiological effects of laser on wound healing through angiogenesis, proliferation of granulation tissue and reduction in inflammatory substances.^(10,11) Studies have also demonstrated the efficacy of UVC radiations on tissue healing through sterilisation without biological tissue death, proliferation of the granulation tissues and increased circulation through angiogenesis, collateral circulation and the endothelial proliferation factors.^(7,8) However, no studies have attempted to combine laser and UVC in the healing of diabetic transmetatarsal amputation stump so far. Thus, we sought to study the short-term efficacy of intensive multimodal phototherapy on diabetic ulcer healing.

Although some studies have hypothesised that UVC radiations have a tumorigenesis effect on biological tissues,⁽⁹⁾ none has proven it to be a fact. With this fear in mind, the authors of a previous phototherapy research had administered UV radiations only 2–3 times weekly to their patients, which may have decreased the accentuation of wound healing by UV radiations.⁽⁸⁾ Hence, we administered UV radiations to the patient daily. Previous studies have reported the efficacy of laser or UVC in pressure sores.^(7,8) Multiple reviews and meta-analysis have also stated the efficacy of laser in diabetic ulcer healing.^(6,10) However, to our knowledge, none of the studies to date have tested the combined efficacy of the laser and UVC in post-amputation infected diabetic ulcer healing. Our case shows that high-intensity multimodal phototherapy can hasten wound healing and facilitate earlier weight-bearing and mobility.

In conclusion, high-intensity multimodal phototherapy may shorten outpatient rehabilitation and foster wound healing, thereby achieving earlier functional independence in patients with diabetic ulcers or infected postsurgical wounds. We recommend high-intensity, short-term multimodal phototherapy for infected non-healing diabetic ulcerated amputation stumps. Randomised trials to prove its effectiveness in the shortening of inpatient and outpatient rehabilitation visits may be required in future. In

addition, a larger sample size with more functional outcome measure scales may generalise the efficacy of this multimodal phototherapy in diabetic ulcers and infected amputation stumps.

ACKNOWLEDGEMENTS

The authors would like to thank Dr Abhishek Srivastava, Head of Department of Physical Medicine and Rehabilitation, Kokilaben Dhirubhai Ambani Hospital, Mumbai, Mrs Nikita Joshi, Head of Department of Physiotherapy and Prof Dr Salhan, Dean of Sikkim Manipal Institute of Medical Sciences for their unconditional support and motivation.

REFERENCES

- Kalani M, Apelqvist J, Blombäck M, et al. Effect of dalteparin on healing of chronic foot ulcers in diabetic patients with peripheral arterial occlusive disease: a prospective, randomized, double-blind, placebo-controlled study. *Diabetes Care* 2003; 9:2575-80.
- Kanji JN, Anglin RE, Hunt DL, Panju A. Does this patient with diabetes have large-fiber peripheral neuropathy? *JAMA* 2010; 21; 303:1526-32.
- Norman PE, Schoen DE, Gurr JM, Kolybaba ML. High rates of amputation among Indigenous people in Western Australia. *Med J Aust* 2010; 192:421.
- Reiber GE, Boyko EJ, Smith DG. Lower extremity foot ulcers and amputations in diabetes. In: Maureen I Harris, ed. *Diabetes in America*, 2nd edn. Bethesda: National Institutes of Health, 1995: 409-28.
- Vuorisalo S, Venermo M, Lepäntalo M. Treatment of diabetic foot ulcers. *J Cardiovasc Surg (Torino)* 2009; 50:275-91.
- Cullum N, Nelson EA, Flemming K, Sheldon T. Systematic reviews of wound care management: (5) beds; (6) compression; (7) laser therapy, therapeutic ultrasound, electrotherapy and electromagnetic therapy. *Health Technol Assess* 2001; 5:1-221.
- Thai TP, Houghton PE, Campbell KE, Woodbury MG. Ultraviolet light C in the treatment of chronic wounds with MRSA: a case study. *Ostomy Wound Manage* 2002; 48:52-60.
- Nussbaum EL, Biemann I, Mustard B. Comparison of ultrasound/ultraviolet-C and laser for treatment of pressure ulcers in patients with spinal cord injury. *Phys Ther* 1994; 74:812-23.
- Xia X, Park E, Liu B, et al. Reduction of IKK α expression promotes chronic ultraviolet B exposure-induced skin inflammation and carcinogenesis. *Am J Pathol* 2010; 176:2500-8.
- Sobanko JF, Alster TS. Laser treatment for scars and wounds. *G Ital Dermatol Venereol* 2009; 144:583-93.
- Forney R, Mauro T. Using lasers in diabetic wound healing. *Diabetes Technol Ther* 1999; 1:189-92.