

CMEARTICLE

A guide to requesting outpatient and emergency radiographs

Gerald Jit Shen Tan^{1,2}, MBBS, FRCR, Er Luen Lim³, MBBS, MRCSE, Choon How How⁴, MMed, FCFP

It is another busy evening clinic and there are many patients waiting to be seen. You are attending to two football players who collided in a soccer match. One complains of neck pain, while the other says he has twisted his ankle. You do not think they have fractures, but wonder if they require X-rays. Just then, your assistant brings you the forearm X-ray for 68-year-old Mary Tan who fell on her outstretched hand. The report says "No fracture seen", but she has severe pain and tenderness over her anatomical snuffbox and you really suspect a fracture. What should you do next?

INTRODUCTION

Radiology is an important adjunct to clinical practice. For many clinicians, requesting X-rays was not formally taught but learnt on the job. While X-rays can be invaluable, over-usage can result in wastage of resources and unnecessary radiation exposure. Equally important is to understand the limitations of X-rays, so as not to develop a false sense of confidence and miss a diagnosis. This article summarises the guidelines in deciding whether an X-ray is required, and if so, which X-ray to request.⁽¹⁾

OPTIMAL USE OF X-RAYS

There are three questions to bear in mind when requesting an X-ray: (1) Does the patient really need an X-ray, and will it affect my diagnosis and management?; (2) What X-ray should I order, and do I need additional views?; (3) Is there another diagnostic test that is better or complementary?

COMPLETING THE REQUEST FORM

Clinically relevant history

The clinical history is important even before the X-ray is taken. Firstly, the study may be performed differently, for example, by placing a marker for foreign bodies. Secondly, the radiographer may be able to suggest alternative or additional views. It does not need to be long – the presenting complaint, location and duration, as well as the clinical question will suffice.

Comparison studies

Comparison with old studies is invaluable and leads to a change in diagnosis in up to 14% of studies.⁽²⁾ If the images or reports are not available, one should still mention the existence of prior studies, and if possible, where and when they were performed.

Contact details

Contact details allow for clarifications and communication of critical findings. For electronic order systems, check that the correct doctor is logged-in or selected, in order to avoid mis-directed phone calls and medicolegal responsibility.

Correct study

This 'C' is the one that clinicians worry about the most, but in reality, it causes the least angst to the reporting radiologist. If in doubt, contact the radiographer and/or radiologist prior to requesting the study. This may prevent delays in diagnosis and reduce patient recalls, cost and radiation exposure.

You start by reviewing Mary Tan's forearm X-ray report, and realise that in your haste, all you had written in the history was "? #". You pull out the films to have a look yourself, and there seems to be a crack in the scaphoid, but you are not very sure because of all the overlap. You decide to give the radiologist a call. He takes a second look, but agrees that it is hard to be sure and suggests doing a dedicated scaphoid view. Thankfully, the patient is still around and understands the need for more X-rays.

REQUESTING THE CORRECT STUDY

Head and facial trauma

Skull X-rays cannot be used to exclude intracranial haemorrhage, as X-ray abnormalities are present in only 38% of cases. Any significant head injury should be referred to the emergency department, and proceed directly for computed tomography (CT) imaging, as affirmed by the NICE guidelines.⁽³⁾ If skull

¹Department of Radiology, Tan Tock Seng Hospital, ²Lee Kong Chian School of Medicine, ³Emergency Medicine Department, National University Hospital, ⁴Singhealth Polyclinics – Sengkang, Singapore

Correspondence: A/Prof Gerald Tan Jit Shen, Consultant, Department of Diagnostic Radiology, Tan Tock Seng Hospital, 11 Jalan Tan Tock Seng, Singapore 308433. radio@geraldtan.com

X-rays are performed for other reasons, the standard views are anteroposterior (AP) and lateral. Additional views include the Townes view (for the posterior skull vault) and submentovertex (SMV) view for the skull base. It bears emphasising that by the time one suspects skull base injury, one should seriously consider obtaining a CT image instead.

For facial and orbital fractures, the standard views include posteroanterior (PA), occipitomeatal (OM) and lateral views. The Jughandle view (so called because the arches resemble jug handles on this view) can also be performed for zygomatic arch fractures. The majority of nasal fractures involve the anterior nasal septum, which is cartilaginous and not visible on X-rays. Therefore, a normal nasal X-ray does not exclude a nasal fracture.

For mandibular fractures, the PA, lateral and both obliques are standard mandibular views. The mandible is considered a 'ring bone' (like the pelvis), and additional fractures are present in 50% of 'isolated' mandibular fractures. Therefore, if a mandibular fracture is diagnosed, for example, incidentally on an AP skull X-ray, the complete mandibular series should be obtained. Dynamic (mouth open/mouth closed) views of the temporomandibular joint (TMJ) can also be performed if there is suspicion of dislocation. An orthopantomogram (OPG) shows the mandible in a single panoramic view, but is often available only in dental units rather than traditional X-ray departments. For orbital foreign body, X-rays are useful only when there is clinically evident ocular penetration by a radio-opaque foreign body. Supplying this history is important, as the radiographer will then obtain dynamic (look up/look down) views.

Cervical spine trauma

The two most widely used clinical protocols in deciding if X-rays are required to "clear the spine" are the Canadian C-spine rule and the NEXUS low-risk criteria (Table I). If X-rays are required, a number of different views have been used.⁽⁴⁾ Most authors agree that a minimum of two views (AP and lateral) are required, and some departments also include the open mouth (odontoid or OM, and not to be confused with occipitomeatal) view. If the C7/T1 junction is not visualised on the lateral view, a Swimmer's view should also be obtained. These views are summarised in Table II.

You then call the soccer player who is complaining of neck pain into your room. He says he was jumping to head the ball, but instead collided with his friend in mid-air. He points to the right side of his neck as the site of pain, but is otherwise well and able to slowly turn his head from side to side. Do you need to clear the C-spine radiologically?

Rib fractures

Rib fractures are present in up to 10% of cases of blunt chest trauma. However, only 30% of undisplaced rib fractures are

Table I. National Emergency X-Radiography Utilization Study (NEXUS) criteria.

NEXUS criteria to clear the cervical spine clinically	
1.	Normal level of alertness
2.	No posterior midline cervical tenderness
3.	No focal neurologic deficit
4.	No alcohol intoxication
5.	No distracting injury
If any of the above is not met, then radiological clearance should be performed.	

Table II. Radiographic views for head and cervical spine trauma.

Score	Standard views	Additional views
Skull	AP, lateral	Townes, SMV*
Face	PA, OM, lateral	Jughandle (zygomatic arch)
Orbits	PA, OM, lateral	Foreign body views
Mandible	PA, lateral, both obliques	OPG*, TMJ views
Nasal bone	OM, lateral*	
Cervical spine	AP, lateral	OM (Odontoid), Swimmer's

*See text

SMV: submentovertex; OPG: orthopantomogram; AP: anteroposterior; PA: posteroanterior; OM: occipitomeatal; TMJ: temporomandibular joint

visible on a chest X-ray. Oblique views may help, but a significant proportion of fractures would still be missed. Nonetheless, given that the initial treatment of uncomplicated rib fractures and rib contusions is similar, a delayed diagnosis would not impact treatment significantly. If definitive diagnosis is required (e.g. for medicolegal purposes), repeat X-rays after 1–2 weeks may demonstrate interval displacement and/or callus formation to help make the diagnosis.

Extremity trauma

The general principles in imaging extremity trauma are to obtain two orthogonal (right angle) views and to include the joint above and below. Most radiographers would do this automatically as long as the site of injury is specified. Although we distinguish between AP versus PA and lateral versus oblique views in this article, in practice, it is acceptable to request 'AP Lat' or even 'Two views' as long as sufficient history is provided. Views of the contralateral (and presumably normal) side may also be useful, usually when attempting to distinguish an accessory ossicle (in adults) or unfused ossification centre (in children) from a fracture. The reason should be clearly explained to the patient as well as on the request form.

INDICATIONS AND VIEWS FOR SELECTED SITUATIONS

Wrist

The carpal bones are complex three-dimensional structures best assessed with PA, oblique and lateral views. If a scaphoid fracture is suspected (e.g. tenderness in the anatomical snuffbox), dedicated 'scaphoid views' should be requested.

Table III. Indications for X-rays in lower limb trauma.

<p>Knee: Pittsburgh decision rules Blunt trauma or a significant fall as mechanism of injury plus either of the following:</p> <ol style="list-style-type: none"> 1. Age < 12 years or > 50 years; or 2. Inability to weight-bear for four steps <p>Ankle: Ottawa ankle rules Pain in the malleolar zone plus any one of the following:</p> <ol style="list-style-type: none"> 1. Tenderness along the tip of the medial malleolus or posterior tibia; or 2. Tenderness along the tip of the lateral malleolus or posterior fibula; or 3. Inability to weight-bear for four steps <p>Foot: Ottawa foot rules Pain in the midfoot plus any one of the following:</p> <ol style="list-style-type: none"> 1. Bone tenderness at the base of the fifth metatarsal; or 2. Bone tenderness at the navicular bone; or 3. Inability to weight-bear for four steps
--

Table IV. Radiographic views for trauma of the extremities.

Region of interest	Standard views	Additional views
Wrist	PA, oblique	True lateral, scaphoid views
Hand	PA, oblique	Individual fingers
Knee	AP, lateral	Skyline
Ankle	AP/mortise, lateral	Calcaneal

PA: posteroanterior; AP: anteroposterior

Hand

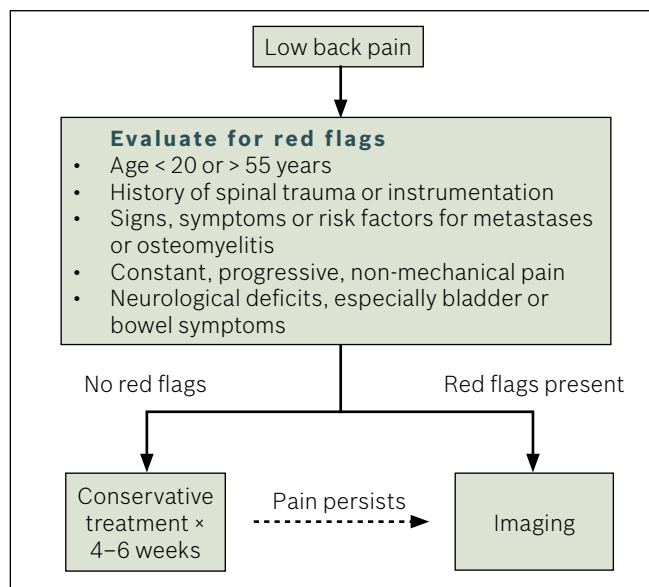
There is often overlap of the proximal phalanges on the oblique/lateral view, especially in injured patients with limited range of motion. Therefore, if a finger fracture is suspected, a specific X-ray of that finger should be requested.

Knee

The Ottawa Knee Rules or Pittsburgh Decision Rules can be used when deciding on the need for knee X-rays (Table III). AP and lateral X-rays are standard; however, they are obtained differently for traumatic and non-traumatic indications, and an adequate history should be provided. Skyline views of the patella can be added if patella dislocation or fracture is suspected.

Ankle and foot

The Ottawa Ankle Rules are useful to decide if a patient with an ankle injury should have an X-ray. Lateral and AP/mortise X-rays are standard. An axial calcaneal view may be added if there is a history of axial loading (e.g. fall from height) and standard X-rays are unrevealing. In addition, ankle pain may be due to a fracture of the base of the 5th metatarsal. If the patient reports an inversion injury of a plantar flexed foot, or point tenderness over the 5th

**Fig. 1** Algorithm for evaluation of low back pain.

metatarsal base, a foot X-ray should also be performed. Other indications for foot X-rays (Ottawa Foot Rules) are listed in Tables III and IV.

Finally, you see the second soccer player, who collided with his friend in mid-air and landed awkwardly on his right ankle. He complains of pain over the medial side, and on examination, the ankle is markedly swollen and there is indeed pain over the medial malleolus on palpation. However, he can still hobble slowly around the room. Does he need an X-ray?

Low back pain

Low back pain affects two-thirds of adults during their lifetime, and is the leading cause of work disability in the developed world. However, only 5% of cases have serious underlying diseases or neurological symptoms requiring surgical treatment, and the aim of imaging is to pick up these 5%. As for the rest, there is no firm evidence that the presence of radiological abnormalities correlates with a specific cause of low back pain, and a cause may not be found in up to 85% of patients despite extensive investigation.⁽⁵⁾ Therefore, in the absence of 'red flags', it would be reasonable to treat low back pain conservatively for 4–6 weeks before performing imaging, which in the first instance, would consist of AP and lateral views (Fig. 1). Oblique views (also known as the 'Scotty Dog' views) may be used to diagnose spondylolysis (fracture of the pars interarticularis), most commonly in the setting of spondylolisthesis (anterior slippage of the vertebrae). Other special views include flexion and extension views to assess for instability and views of the sacroiliac joints for early ankylosing spondylitis. Multiple views would, however, increase the radiation dose, particularly to the female gonads, and should not be requested routinely.

Acute abdominal pain

Abdominal pain may range from mild to severe. A prospective series found that X-rays were most likely to be positive in the following scenarios: severe abdominal pain (acute abdomen), intestinal obstruction and renal colic/haematuria. Conversely, 98% of the X-rays for diffuse, nonspecific abdominal pain, nausea, vomiting or gastrointestinal bleeding were negative.⁽⁶⁾ A single supine abdominal X-ray (AXR) is sufficient for most indications. Although traditional teaching is that erect views may be used in the evaluation of intestinal obstruction, these are rarely required. If there is suspicion of bowel perforation, an erect chest X-ray should be performed instead.

The distinction between a kidneys, ureter and bladder (KUB) X-ray and AXR has blurred with the advent of digital X-rays. Nonetheless, it is a good practice to request a KUB rather than an AXR for evaluation of the urinary tract, particularly for lower tract symptoms, as an AXR may sacrifice coverage of the pubic symphysis in order to include the sub-diaphragmatic region.

Luckily, you had kept the guidelines, and based on these, you decide that the first soccer player's C-spine can be cleared clinically, but that his friend needs an ankle X-ray. Mary's scaphoid series also comes back, and true enough, there was a scaphoid fracture. She thanks you for picking it up, and you also heave a sigh of relief.

TAKE HOME MESSAGES

1. Prior to requesting an X-ray, ask if the result would change your diagnosis and management.
2. The request form should include Clinically relevant history, Comparison studies (if any) and Contact details in addition to the Correct study.
3. Skull X-rays are rarely of use in head injury. Any significant head injury should be referred to the emergency department and proceed directly for CT imaging.

4. Extremity trauma in general will be imaged appropriately as long as you indicate the site of injury in the request. Additional views may be required for the wrist, ankle and foot.
5. Low back pain, in the absence of 'red flags', can be treated conservatively for 4–6 weeks before performing imaging.

ABSTRACT Radiology is an important adjunct to clinical practice, but for many clinicians, requesting X-rays was something that was learnt on the job. This article provides guidelines on when and how to request X-rays for acute conditions such as head and cervical spine trauma, suspected rib and extremity fractures, low back pain and acute abdominal pain. We also highlight what to write in the request form, in order to obtain maximum value from the examination and allow the radiologist to generate a useful, accurate report.

Keywords: X-ray, trauma, fracture, guidelines
Singapore Med J 2012; 53(7): 423–427

REFERENCES

1. Halvorsen JG, Swanson D. Indications for office radiographs. J Fam Pract 1990; 31:521-9.
1. Aideyan UO, Berbaum K, Smith WL. Influence of prior radiologic information on the interpretation of radiographic examinations. Acad Radiol 1995; 2:205-8.
2. National Institute for Health and Clinical Excellence. Head injury. Triage, assessment, investigation and early management of head injury in infants, children and adults. 2007. Available at: www.nice.org.uk/CG56. Accessed June 26, 2012.
3. Daffner RH. Controversies in cervical spine imaging in trauma patients. Semin Musculoskelet Radiol 2005; 9:105-15.
4. Jarvik JG, Deyo RA. Diagnostic evaluation of low back pain with emphasis on imaging. Ann Intern Med 2002; 137:586-97.
5. Eisenberg RL, Heineken P, Hedgcock MW, Federle M, Goldberg HI. Evaluation of plain abdominal radiographs in the diagnosis of abdominal pain. Ann Surg 1983; 197:464-9.

SINGAPORE MEDICAL COUNCIL CATEGORY 3B CME PROGRAMME

(Code SMJ 201207A)

	True	False
1. The 4 Cs to consider when requesting an X-ray are clinically relevant history, cost of the exam, coverage by insurance or third party payer and correct views.	<input type="checkbox"/>	<input type="checkbox"/>
2. A normal X-ray definitively excludes a fracture.	<input type="checkbox"/>	<input type="checkbox"/>
3. It is important to provide old X-rays for comparison, as this may result in a change in final diagnosis in more than 10% of radiology reports.	<input type="checkbox"/>	<input type="checkbox"/>
4. More than 80% of patients with severe head injuries and intracranial haemorrhage have a concurrent skull fracture visible on their skull X-rays.	<input type="checkbox"/>	<input type="checkbox"/>
5. A head injury patient presenting with cerebrospinal fluid rhinorrhoea should proceed for CT imaging even if skull X-rays have not been performed yet.	<input type="checkbox"/>	<input type="checkbox"/>
6. A single anteroposterior (AP) view is sufficient to clear the cervical spine if the patient is immobilised or cannot turn his head.	<input type="checkbox"/>	<input type="checkbox"/>
7. An intoxicated man complaining of neck pain does not need a cervical X-ray as long as his Glasgow Coma Scale score is 15 and he has no other injuries or focal neurological deficits.	<input type="checkbox"/>	<input type="checkbox"/>
8. If the C7/T1 junction cannot be seen on the lateral view of the cervical spine, the only option is to proceed for CT imaging.	<input type="checkbox"/>	<input type="checkbox"/>
9. Rib fractures may still be present in up to 30% of normal PA and oblique chest X-rays.	<input type="checkbox"/>	<input type="checkbox"/>
10. The site of injury or the suspected site of fracture should be clearly stated in the request document for the radiographer to obtain the most appropriate views.	<input type="checkbox"/>	<input type="checkbox"/>
11. X-rays of the normal elbow for comparison are contraindicated in children due to the harmful effects of radiation at this age.	<input type="checkbox"/>	<input type="checkbox"/>
12. Two (AP and lateral) views are sufficient to exclude wrist fractures.	<input type="checkbox"/>	<input type="checkbox"/>
13. Inability to weight bear and walk for four steps on the injured ankle or foot is an indication to request an X-ray.	<input type="checkbox"/>	<input type="checkbox"/>
14. An axial calcaneal view may be useful to evaluate heel injuries if there is a history of falling from height.	<input type="checkbox"/>	<input type="checkbox"/>
15. A foot X-ray may be indicated when a patient presents with pain following an injury to the ankle.	<input type="checkbox"/>	<input type="checkbox"/>
16. In the absence of 'red flags', it would be reasonable to treat low back pain conservatively for 4–6 weeks before performing imaging.	<input type="checkbox"/>	<input type="checkbox"/>
17. Renal colic and gross haematuria are appropriate indications to perform a kidney, ureter and bladder X-ray.	<input type="checkbox"/>	<input type="checkbox"/>
18. The majority of abdominal X-rays for diffuse abdominal pain, vomiting and gastrointestinal bleeding will be normal.	<input type="checkbox"/>	<input type="checkbox"/>
19. A 20-year-old motorcyclist who hit his head following a road traffic accident and is complaining of persistent headache with two episodes of vomiting can be discharged if his skull X-ray is normal.	<input type="checkbox"/>	<input type="checkbox"/>
20. Based on the Pittsburgh Decision Rules for knee X-rays, a 68-year-old woman who fell heavily on her knee, but is able to weight-bear for four steps, should still have an X-ray.	<input type="checkbox"/>	<input type="checkbox"/>

Doctor's particulars:

Name in full : _____
MCR number : _____ Specialty: _____
Email address : _____

SUBMISSION INSTRUCTIONS:

(1) Log on at the SMJ website: <http://www.sma.org.sg/publications/smjcurrentissue.aspx> and select the appropriate set of questions. (2) Provide your name, email address and MCR number. (3) Select your answers and click "Submit".

RESULTS:

(1) Answers will be published in the SMJ September 2012 issue. (2) The MCR numbers of successful candidates will be posted online at the SMJ website by 24 August 2012. (3) Passing mark is 60%. No mark will be deducted for incorrect answers. (4) The SMJ editorial office will submit the list of successful candidates to the Singapore Medical Council. (5) One CME point is awarded for successful candidates.

Deadline for submission: (July 2012 SMJ 3B CME programme): 12 noon, 17 August 2012.