

CMEARTICLE

Clinics in diagnostic imaging (148)

Sanjeev *Bhagwani*¹, MMed, FRCR, Wilfred CG *Peh*¹, FRCP, FRCR

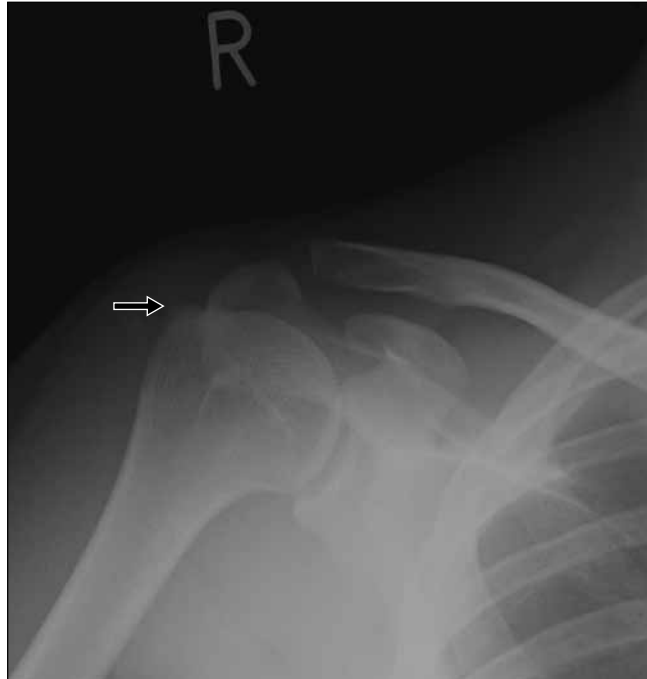

Fig. 1 Frontal radiograph of the right shoulder obtained immediately after the road traffic accident, three months after the initial presentation of shoulder pain.

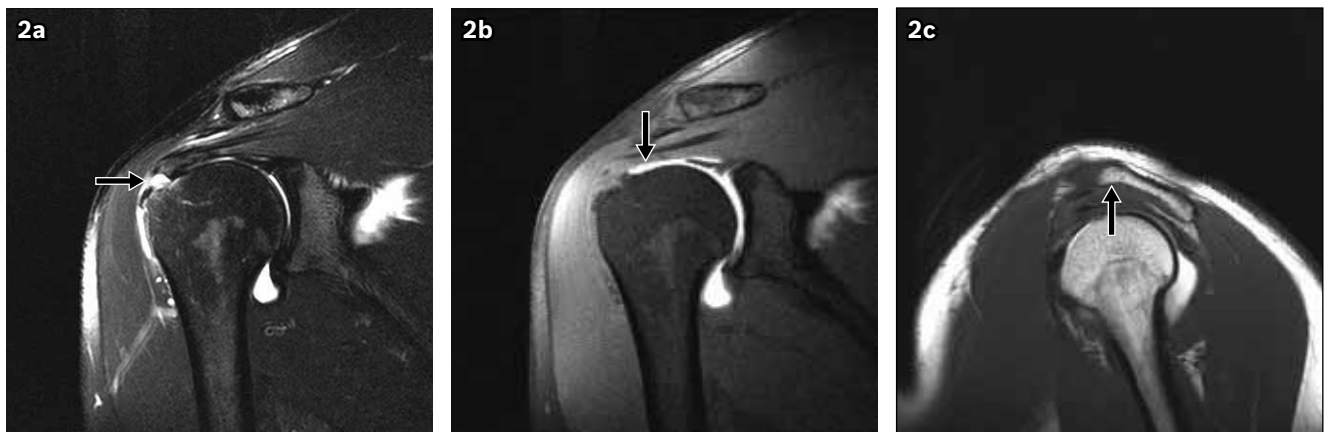

Fig. 2 Coronal fat-suppressed (a) T2-W, (b) T1-W and (c) sagittal T1-W MR arthrographic images of the right shoulder obtained after the road traffic accident, three months after the initial presentation of shoulder pain.

CASE PRESENTATION

A 29-year-old man presented with right shoulder pain for a period of one year. His pain was associated with difficulty in abduction of his shoulder. The patient had no significant past medical history and was treated conservatively with

analgesics. His pain was worsened by a road traffic accident three months later, when his car was hit from behind by a bus. What do the radiograph (Fig. 1) and magnetic resonance (MR) arthrograms (Figs. 2a–c) of the right shoulder show? What is the diagnosis?

¹Department of Diagnostic Radiology, Khoo Teck Puat Hospital, Singapore

Correspondence: Prof Wilfred CG Peh, Professor and Head, Department of Diagnostic Radiology, Khoo Teck Puat Hospital, Alexandra Health, 90 Yishun Central, Singapore 768828. wilfred.peh@gmail.com

IMAGE INTERPRETATION

The right shoulder radiograph (Fig. 1) shows mild bony prominence at the greater tuberosity (arrow), with no evidence of fracture or dislocation. Coronal fat-suppressed T2-weighted MR arthrographic image (Fig. 2a) shows abnormal focal fluid collection (arrow) within the supraspinatus tendon, near its insertion. This T2-hyperintense collection is continuous, with an effusion in the subacromial-subdeltoid bursa. The corresponding coronal fat-suppressed T1-weighted MR image (Fig. 2b) shows the injected contrast agent (arrow) confined within the glenohumeral joint, with a normal smooth outline of the supraspinatus tendon undersurface. Interpreted information from these two sets of images was indicative of a high-grade, bursal-sided partial-thickness tear of the supraspinatus tendon. Sagittal T1-weighted MR arthrographic image (Fig. 2c) shows slight hooking (arrow) of the anterior acromial arch (type III acromion).

DIAGNOSIS

Bursal-sided partial-thickness supraspinatus tendon tear.

CLINICAL COURSE

The patient was initially managed conservatively with symptomatic analgesic treatment. However, in view of worsening clinical symptoms, surgery was performed ten months later. During the operation, a full-thickness rotator cuff tear near the insertion of the supraspinatus tendon, a tight subacromial space and a protruding bony humeral head prominence over the area of the rotator cuff tear were observed. Subacromial decompression was achieved with anterior acromioplasty. Supraspinatus tendon debridement and removal of the bony prominence on the humeral head were done, followed by mini-open rotator cuff repair with suture anchor. The patient improved clinically following surgery and made a good recovery. MR arthrograms (Figs. 3a & b) obtained 17 months after surgery show thickening and mild signal alteration of the otherwise intact supraspinatus tendon insertion, compatible with postsurgical changes.

DISCUSSION

The exact pathogenesis of rotator cuff injuries remains controversial. They are believed to be the result of an interplay between intrinsic age-related tendon damage aggravated by chronic microtrauma⁽¹⁾ and extrinsic causes.⁽²⁾ The extrinsic rotator cuff impingement theory proposed by Neer⁽²⁾ implicated acromial hypertrophic changes and spur formation, and has been supported by other authors.^(3,4) A higher incidence of impingement has also been found to be associated with types II and III acromial arch morphology.⁽⁵⁾ Our patient had a type III acromion (Fig. 2c), which could be an aggravating factor.

Routine shoulder radiographs in acute rotator cuff tears are usually normal.⁽⁶⁾ They may show subacromial bony spurs^(7,8) and eventual superior migration of the humeral head⁽⁶⁾

(acromiohumeral distance < 7 mm) in full-thickness chronic tears (Fig. 4). Radiographs in symptomatic rotator cuff tears and acute shoulder impingement syndrome may show degenerative bony changes at the greater tuberosity of the humerus,^(8,9) such as osteophytes, subchondral cysts, sclerosis and osteolysis.⁽⁹⁾

In patients with rotator cuff tears, MR imaging can provide information on tear dimensions, extent of tendon retraction, muscle atrophy and coracoacromial arch morphology.⁽¹⁰⁾ Rotator cuff tendinopathy manifests as increased signal intensity within the tendon on T2-weighted sequences (Figs. 5a & 6), which is less hyperintense than fluid signal.⁽⁵⁾ MR imaging can also demonstrate reported associations of anterior greater tuberosity subchondral cysts (Fig. 6) with rotator cuff disorders.⁽¹¹⁾ However, on conventional MR imaging, it can be difficult to differentiate between tendinopathy and partial-thickness tear due to focal fat, subclinical degeneration, muscle fibres and vascularisation anomalies.⁽⁵⁾ These limitations can be overcome with the help of direct MR arthrography.⁽¹²⁾ Contrast distension of the joint capsule with outlining of the intra-articular structures and leakage of contrast into the abnormalities help confer superior diagnostic capability to MR arthrography.⁽¹³⁾ It has been found that image interpretation of indirect MR arthrography after intravenous contrast injection is more difficult⁽⁵⁾ than for direct MR arthrography, especially in the differentiation of small tears from tendinopathy.

Partial-thickness tears of the supraspinatus rotator cuff tendon most commonly occur in the 'critical zone', located about 1 cm from its insertion into the greater tuberosity.⁽⁵⁾ They are broadly divided into articular or bursal surface and concealed interstitial tears.⁽¹⁴⁾ Although estimation of the incidence of partial-thickness rotator cuff tears has been made from several cadaveric and imaging studies, the exact incidence is still unknown.⁽¹⁵⁾ The most common tears are articular surface tears (Fig. 7),^(10,14,16) with an incidence of up to 54% on arthroscopy.⁽¹⁶⁾ The incidence of bursal-sided tears is variable, with reported incidence of 2.9%,⁽¹⁷⁾ 18%⁽¹⁸⁾ and up to 26%⁽¹⁶⁾ in different studies. The incidence of combined bursal- and articular-sided partial-thickness tears were found to be 20% on arthroscopy,⁽¹⁶⁾ while the incidence of concealed interstitial tears comprised up to 33% of cases in another study.⁽¹⁹⁾ Ellman graded partial-thickness tears according to their depth, namely < 3 mm (grade I), 3–6 mm (grade II) and > 6 mm (grade III).⁽²⁰⁾

Bursal surface tears are not well appreciated on T1-weighted sequences (Fig. 2b) because the contrast agent injected directly into the glenohumeral joint does not extend into the bursa,⁽⁵⁾ but they are well demonstrated on T2-weighted images (Fig. 2a). Our case also emphasises the value of correlating the corresponding coronal fat-suppressed T1- and T2-weighted MR arthrogram images (Figs. 2, 3 & 5), in order to avoid confusion between pre-existing subacromial bursal fluid and the injected contrast agent extending from

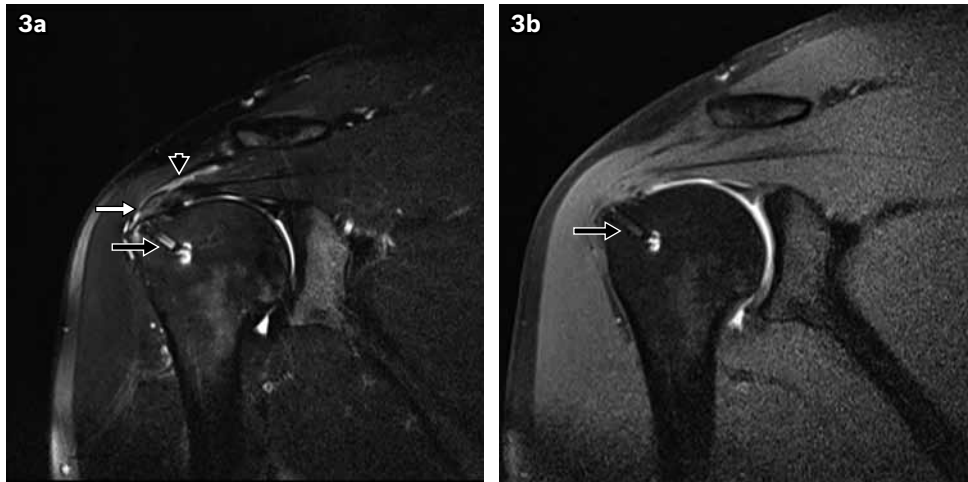


Fig. 3 Coronal fat-suppressed (a) T2-W and (b) T1-W MR arthrographic images obtained 17 months after surgical rotator cuff repair show the presence of a suture anchor (black arrows) in the humeral head. There is thickening and mild signal alteration of the otherwise intact supraspinatus tendon insertion (white arrow), compatible with post-surgical changes. A small amount of subacromial-subdeltoid bursal fluid (arrowhead) is present.

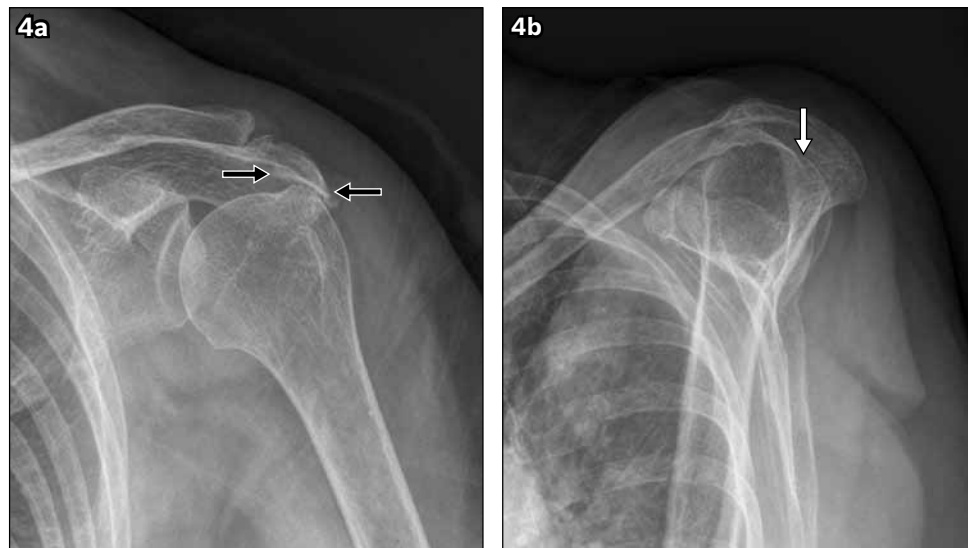


Fig. 4 (a) Frontal and (b) transcapular shoulder radiographs of a patient with full-thickness chronic rotator cuff tear show acromial and humeral osteophyte formation (black arrows) with superior migration of the humeral head (white arrow).

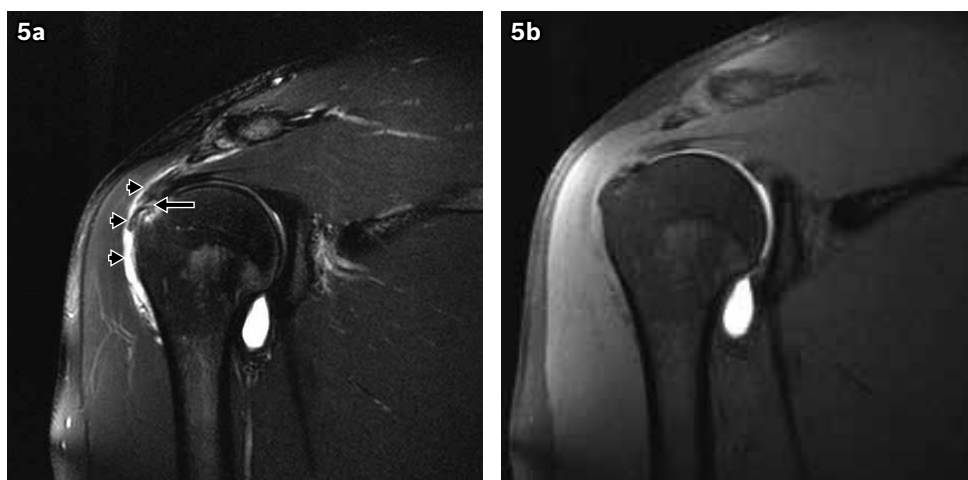


Fig. 5 Coronal fat-suppressed (a) T2-W and (b) T1-W MR arthrographic images of our patient's right shoulder at the time of initial presentation of shoulder pain, taken three months prior to the road traffic accident, show a focal area of hypertense signal (which is less than that of fluid) (arrow) in the distal supraspinatus tendon, compatible with tendinopathy. Effusion is present in the subacromial-subdeltoid bursa (arrowheads).

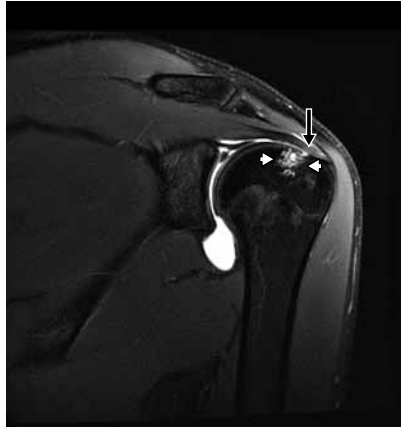

Fig. 6 Coronal fat-suppressed T2-W MR arthrographic image in a 20-year-old man shows supraspinatus tendinopathy (arrow) and subchondral cysts (arrowheads) in the anterior aspect of the greater tuberosity.

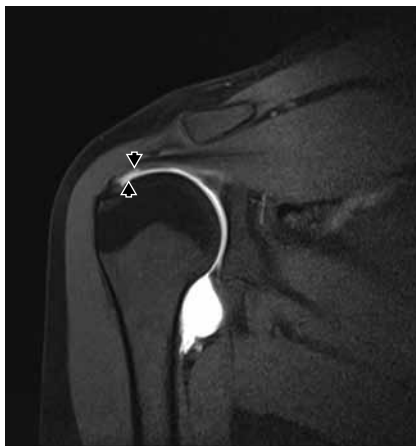

Fig. 7 Coronal fat-suppressed T1-W MR arthrographic image of a 44-year-old woman shows an articular-sided partial tear of the distal supraspinatus tendon, with extension of contrast into the tear (arrowheads).

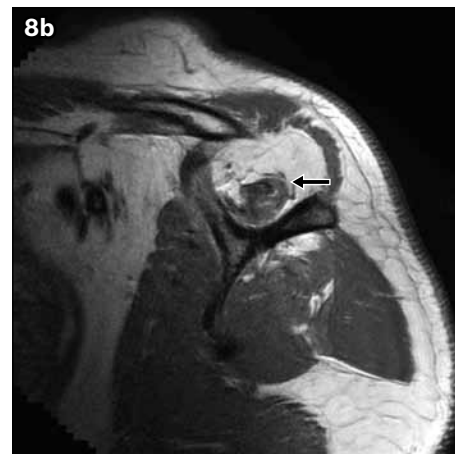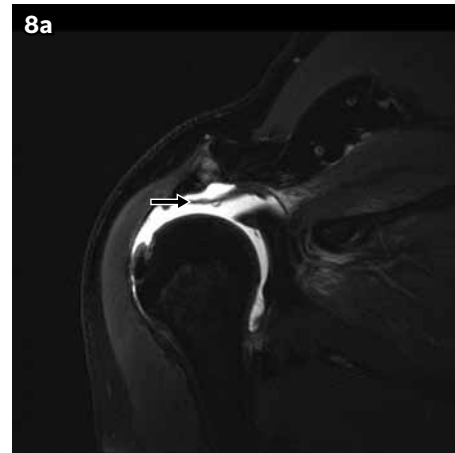


Fig. 8 Coronal fat-suppressed (a) T2-W MR arthrographic image of a 51-year-old man shows a full-thickness tear of the supraspinatus tendon with retraction of the torn edge (arrow) up to the level of the humeral dome, and extension of contrast into the subacromial bursa. (b) Sagittal T1-W MR arthrographic image in the same patient shows severe supraspinatus muscle atrophy (arrow), and mild subscapularis and infraspinatus muscle atrophy, indicative of a chronic rotator cuff tear.

the glenohumeral joint.⁽⁵⁾ On MR arthrography, full-thickness tears appear as a gap in the entire thickness of the tendon, with contrast agent filling the gap (Fig. 8a) and extending into the subacromial bursa.⁽⁵⁾ Other useful information on full-thickness tears, such as the extent of tendon retraction and the degree of muscle atrophy, can also be obtained using MR arthrography via coronal images (Fig. 8a) and sagittal T1-weighted sequences (Fig. 8b), respectively. MR arthrography has been found to have the highest sensitivity and specificity for diagnosing both partial- and full-thickness tears.⁽²¹⁾ However, this needs to be weighed against the associated invasiveness of the procedure, patient discomfort,^(22,23) temporary increase in joint-related pain,⁽²⁴⁾ ionising radiation exposure and the resultant longer examination time. There may be injected intra-articular air bubbles simulating loose bodies, leak of contrast material through the joint capsule puncture site or extra-articular injection, which may lead to diagnostic difficulties.⁽¹³⁾ Traughber et al opined that baseline MR arthrography of the shoulder is expensive, invasive and unnecessary in most patients. They have instead recommended that both coronal plane T2-weighted and fat-suppressed

proton density sequences parallel to the supraspinatus tendon long axis be obtained and supplemented with at least one other planar imaging.⁽²⁵⁾ The aforementioned method often allows simultaneous identification of both rotator cuff and labrum abnormalities.

Ultrasonography can demonstrate partial-thickness supraspinatus tears as focal hypoechoic or anechoic defects involving only the bursal (Fig. 9a) or articular surface.⁽²⁶⁾ Extension of the defect across the tendon to involve both surfaces with fluid in the subacromial bursa (Fig. 9b) confirms the presence of a full-thickness tear, which may be associated with retraction of the torn fragments (Fig. 9c) and fluid replacing the area of the torn tendon.⁽²⁶⁾ The accuracy of ultrasonographic evaluation for rotator cuff tears has been reported to be comparable to that of MR imaging, with no statistically significant differences.^(21,27) However, ultrasonography is an operator-dependent modality⁽²⁸⁻³¹⁾ that requires a sufficient level of operator experience⁽²⁸⁾ and standardisation of scanning techniques in order to decrease interobserver variability.⁽²⁹⁾ Thus, it can be associated with detection and misinterpretation errors, as well as inherent

errors such as difficulties in distinguishing tendinopathy from partial-thickness tears and large partial-thickness tears from full-thickness tears.⁽³⁰⁾ Furthermore, while MR imaging may detect intra-articular pathology and deep-seated lesions of the labral cartilage or bone, which may alter the patient's management, these additional findings may not be readily detected on ultrasonography.⁽²⁷⁾ However, ultrasonography offers the benefits of lower cost, reduced examination time and comparable diagnostic efficacy as MR imaging for full-thickness tears.⁽²²⁾ In one study, it was found to obviate the need for further imaging in up to 95% of cases.⁽²⁷⁾ Hence, ultrasonography is used as the first-line investigation for the screening and detection of rotator cuff tears in several centres.

Surgery was performed in our patient due to worsening clinical symptoms. During the operation, we found a full-thickness rotator cuff tear, which did not correlate with the imaging findings obtained ten months prior to surgery. This case elucidates the continual spectrum of rotator cuff injury. Follow-up studies in the literature have shown that, over a period of one year, subsequent increase in size occurred in 34% of partial-thickness tears and progression of symptomatic non-operated partial-thickness rotator cuff tears to full-thickness tears took place in 18% of cases.⁽³²⁾ Interval tear propagation influencing the decision for surgical treatment has also been reported by Andarawis-Puri et al.⁽³³⁾ A period of nonoperative conservative management for partial-thickness tears is usually advocated prior to consideration of a surgical option for symptoms of sufficient intensity and duration.⁽³⁴⁾ However, no evidence has been documented to refute or support these options, nor are there any prescribed guidelines for the allowable time for nonoperative treatment.^(35,36) MR imaging can help demonstrate morphologic features, the extent and dimensions of the rotator cuff tears, the condition of the involved tendon or tendons (with or without involvement of contiguous structures) and the presence of muscle atrophy, all of which may influence rotator cuff tear management and prognosis.⁽¹⁰⁾ It can, therefore, be used to monitor rotator cuff changes and guide patient management in the long-term follow-up of tears of the rotator cuff that are not managed operatively.⁽³⁷⁾

de Jesus et al⁽²¹⁾ reported that MR arthrography is the most accurate technique for the diagnosis of both partial- and full-thickness rotator cuff tears, with increased diagnostic accuracy as compared to conventional MR imaging, especially in small partial-thickness tears.⁽⁵⁾ This differentiation between partial- and full-thickness tears can help practitioners decide whether to use conservative or surgical management.^(38,39) Postoperative MR images after rotator cuff repair have expectedly shown findings of tendon signal alteration due to fibrosis or granulation tissue, as well as changes in tendon morphology related to the quality of residual tendon and type of procedure performed.^(40,41) Only 10% of repaired asymptomatic rotator cuff tendons were found to show normal MR imaging appearances.⁽⁴²⁾ This supports the use of MR arthrography in the follow-up assessment of

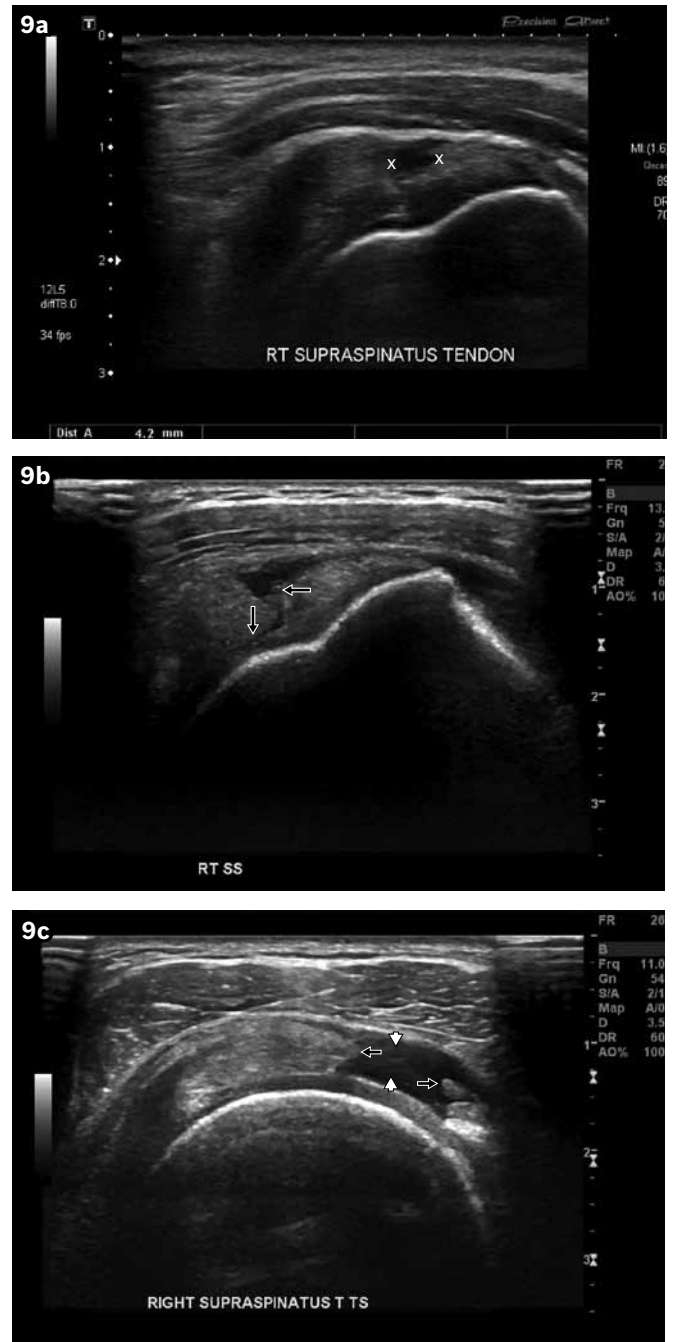


Fig. 9 US images of the supraspinatus tendon in three different patients reveal (a) bursal-sided partial-thickness tear (space between crosses); (b) full-thickness tear (arrows); and (c) full-thickness tear with retraction of the torn tendon (arrows) and intervening fluid (arrowheads).

rotator cuff tendon repairs.⁽⁴³⁾ A postoperative MR imaging finding of subacromial-subdeltoid space fluid is nonspecific and may be associated with an intact rotator cuff or recurrent tear, or may indicate a functional non-watertight repair.⁽⁴²⁾

In summary, supraspinatus injury comprises a spectrum ranging from initial tendinopathy, which may subsequently progress to a partial-thickness tear and eventually culminate in a full-thickness tear, with or without retraction of the torn fragments. The roles of the different imaging modalities and their impact on treatment options and postoperative follow-up have been discussed.

ABSTRACT Rotator cuff injury comprises a continual spectrum of lesions ranging from tendinopathy, which may progress to partial- or full-thickness tear. This progression may be influenced by the interplay of extrinsic and intrinsic factors. We describe the case of a 29-year-old man who presented with right shoulder pain for one year. His initial magnetic resonance (MR) arthrogram showed supraspinatus tendinopathy. Subsequent MR arthrogram, obtained after a road traffic accident, showed a bursal-sided partial-thickness tear of the supraspinatus tendon. In view of his worsening clinical symptoms, surgery was performed ten months later, revealing a full-thickness rotator cuff tear near the tendon insertion, with a tight subacromial space and bony protuberance of the humeral head. The pathogenesis of rotator cuff injuries, the roles of different imaging modalities in the diagnosis of rotator cuff injuries, as well as the advantages and limitations of various radiological modalities, are discussed.

Keywords: bursal-sided partial-thickness supraspinatus tendon tear, partial-thickness supraspinatus tendon tear, rotator cuff injury, supraspinatus tendon injury

REFERENCES

- Codman EA. The shoulder: Rupture of the supraspinatus tendon and other lesions in or about the subacromial bursa. Boston, MA: Thomas Todd Company, 1934.
- Neer CS 2nd. Anterior acromioplasty for the chronic impingement syndrome in the shoulder: A preliminary report. *J Bone Joint Surg Am* 1972; 54:41-50.
- Petersson CJ, Gentz CF. Ruptures of the supraspinatus tendon. The significance of distally pointing acromioclavicular osteophytes. *Clin Orthop Relat Res* 1983; 174:143-8.
- Bigliani LU, Ticker JB, Flatlow EL, Soslowky LJ, Mow VC. The relationship of acromial architecture to rotator cuff disease. *Clin Sports Med* 1991; 10:823-38.
- Vanhoenacker FM, Van der Woude HJ, Vanhoenacker PK, De Praeter G. MR arthrography of the rotator cuff. *JBR-BTR* 2007; 90:338-44.
- Bloom RA. The active abduction view: a new manoeuvre in the diagnosis of rotator cuff tears. *Skeletal Radiol* 1991; 20:255-8.
- Cone RO 3rd, Resnick D, Danzig L. Shoulder impingement syndrome: radiographic evaluation. *Radiology* 1984; 150:29-33.
- Hardy DC, Vogler JB 3rd, White RH. The shoulder impingement syndrome: prevalence of radiographic findings and correlation with response to therapy. *Am J Roentgenol* 1986; 147:557-61.
- Pearsall AW 4th, Bonsell S, Heitman RJ, et al. Radiographic findings associated with symptomatic rotator cuff tears. *J Shoulder Elbow Surg* 2003; 12:122-7.
- Morag Y, Jacobson JA, Miller B, et al. MR imaging of rotator cuff injury: what the clinician needs to know. *Radiographics* 2006; 26:1045-65.
- Fritz LB, Ouellette HA, O'Hanley TA, Kassarian A, Palmer WE. Cystic changes at supraspinatus and infraspinatus tendon insertion sites: association with age and rotator cuff disorders in 238 patients. *Radiology* 2007; 244:239-48.
- Vanhoenacker FM, Van der Woude HJ, Vanhoenacker PK, De Praeter G. MR arthrography of the rotator cuff. *JBR-BTR* 2007; 90:338-44.
- Steinbach LS, Palmer WE, Schweitzer ME. Special Focus Session, MR arthrography. *Radiographics* 2002; 22:1223-46.
- McMonagle JS, Vinson EN. MRI of the shoulder: Rotator cuff. *Appl Radiol* 2012; 41:20-7.
- Shin KM. Partial-thickness rotator cuff tears. *Korean J Pain* 2011; 24:69-73.
- Chun KA, Kim MS, Kim YJ. Comparisons of the various partial thickness rotator cuff tears on MR arthrography and arthroscopic correlation. *Korean J Radiol* 2010; 11:528-35.
- Vinson EN, Helms CA, Higgins LD. Rim-vent tear of the rotator cuff: a common and easily overlooked partial tear. *Am J Roentgenol* 2007; 189:943-6.
- Fukuda H. Partial-thickness rotator cuff tears: a modern view on Codman's classic. *J Shoulder Elbow Surg* 2000; 9:163-8.
- Schaeffeler C, Mueller D, Kirchoff C, et al. Tears at the rotator cuff footprint: prevalence and imaging characteristics in 305 MR arthrograms of the shoulder. *Eur Radiol* 2011; 21:1477-84.
- Ellman H. Diagnosis and treatment of incomplete rotator cuff tears. *Clin Orthop Relat Res* 1990; 254:64-74.
- de Jesus JO, Parker L, Frangos AJ, Nazarian LN. Accuracy of MRI, MR arthrography, and ultrasound in the diagnosis of rotator cuff tears: a meta-analysis. *AJR Am J Roentgenol* 2009; 192:1701-7.
- Dinnes J, Loveman E, McIntyre L, Waugh N. The effectiveness of diagnostic tests for the assessment of shoulder pain due to soft tissue disorders: a systematic review. *Health Technol Assess* 2003; 7:1-166.
- Seibold CJ, Mallisee TA, Erickson SJ, et al. Rotator cuff: evaluation with US and MR imaging. *Radiographics* 1999; 19:685-705.
- Saupe N, Zanetti M, Pfirrmann CW, et al. Pain and other side effects of MR arthrography: prospective evaluation in 1085 Patients. *Radiology* 2009; 250:830-8.
- Traugher PD, Merandi S, Traugher KA. MR arthrography is not proven to be preferred baseline MRI examination. *AJR Am J Roentgenol* 2006; 186:265-6.
- Moosikasuwan JB, Miller TT, Burke BJ. Rotator cuff tears: clinical, radiographic and US findings. *Radiographics* 2005; 25:1591-607.
- Rutten MJ, Spaargaren GJ, van Loon TV, et al. Detection of rotator cuff tears: the value of MRI following ultrasound. *Eur Radiol* 2010; 20: 450-7.
- O'Connor PJ, Rankine J, Gibbon WW, et al. Interobserver variation in sonography of the painful shoulder. *J Clin Ultrasound* 2005; 33:53-6.
- Scheel AK, Schmidt WA, Hermann KG, et al. Interobserver reliability of rheumatologists performing musculoskeletal ultrasonography: results from a EULAR "Train the trainers" course. *Ann Rheum Dis* 2005; 64:1043-9.
- Middleton WD, Teefey SA, Yamaguchi K. Sonography of the rotator cuff: analysis of interobserver variability. *AJR Am J Roentgenol* 2004; 183:1465-8.
- Jacobson JA. Musculoskeletal ultrasound: focused impact on MRI. *Am J Roentgenol* 2009; 193:619-27.
- Yamanaka K, Matsumoto T. The joint side tear of the rotator cuff. A follow up study by arthrography. *Clin Orthop Relat Res* 1994; 304:68-73.
- Andarawis-Puri N, Ricchetti ET, Soslowky LJ. Rotator cuff tendon strain correlates with tear propagation. *J Biomech* 2009; 42:158-63.
- Wolff AB, Sethi P, Sutton KM, et al. Partial-thickness rotator cuff tears. *J Am Acad Orthop Surg* 2006; 14:715-25.
- Smith CD, Corner T, Morgan D, Drew S. Partial thickness rotator cuff tears: what do we know? *Shoulder & Elbow* 2010; 2: 77-82.
- Papalia R, Franceschi F, Del Buono AD, Maffulli M, Denaro V. Results of surgical management of symptomatic shoulders with partial thickness tears of the rotator cuff. *Br Med Bull* 2011; 99:141-54.
- Maman E, Harris C, White L, et al. Outcome of nonoperative treatment of symptomatic rotator cuff tears monitored by magnetic resonance imaging. *J Bone Joint Surg Am* 2009; 91:1898-906.
- Ruotolo C, Nottage WM. Surgical and nonsurgical management of rotator cuff tears. 38. *Arthroscopy* 2002; 18:527-31.
- Mantone JK, Burkhead WZ Jr, Noonan J Jr. Nonoperative treatment of rotator cuff tears. *Orthop Clin North Am* 2000; 31:295-311.
- Resnick D. Shoulder. In: Resnick D, Kang HS, eds. *Internal derangements of joints: emphasis on MR imaging*. Philadelphia: Saunders, 1997: 163-333.
- Zlatkin MB. MRI of the postoperative shoulder. *Skeletal Radiol* 2002; 31:63- 80.
- Spielmann AL, Foster BB, Kokan P, Hawkins RH, Janzen DL. Shoulder after rotator cuff repair: MR imaging findings in asymptomatic individuals – initial experience. *Radiology* 1999; 213:705-8.
- Mohana-Borges AV, Chung CB, Resnick D. MR imaging and MR arthrography of the postoperative shoulder: spectrum of normal and abnormal findings. *Radiographics* 2004; 24:69-85.

SINGAPORE MEDICAL COUNCIL CATEGORY 3B CME PROGRAMME

(Code SMJ 201309B)

	True	False
Question 1. Regarding rotator cuff tears:		
(a) Partial-thickness tears of the supraspinatus rotator cuff tendon occur most commonly about 1 cm from its insertion into the greater tuberosity.	<input type="checkbox"/>	<input type="checkbox"/>
(b) Articular surface tears have been reported to be the least common.	<input type="checkbox"/>	<input type="checkbox"/>
(c) A higher incidence of impingement has been associated with types II and III acromial arch morphology.	<input type="checkbox"/>	<input type="checkbox"/>
(d) Interval tear propagation can influence the decision for surgical treatment.	<input type="checkbox"/>	<input type="checkbox"/>
Question 2. Concerning radiography of rotator cuff tears:		
(a) Shoulder radiographs are usually abnormal in acute tears.	<input type="checkbox"/>	<input type="checkbox"/>
(b) Acromiohumeral distance is normally less than 7 mm.	<input type="checkbox"/>	<input type="checkbox"/>
(c) Full-thickness chronic tears may show eventual superior migration of the humeral head on shoulder radiographs.	<input type="checkbox"/>	<input type="checkbox"/>
(d) Radiographs in acute shoulder impingement syndrome may show degenerative bony changes at the greater tuberosity of the humerus.	<input type="checkbox"/>	<input type="checkbox"/>
Question 3. Conventional magnetic resonance (MR) imaging of rotator cuff tears:		
(a) Can provide information on tear dimensions, extent of tendon retraction, muscle atrophy and coracoacromial arch morphology.	<input type="checkbox"/>	<input type="checkbox"/>
(b) Can easily differentiate between tendinopathy and partial-thickness tear.	<input type="checkbox"/>	<input type="checkbox"/>
(c) May detect intra-articular pathology and deep-seated lesions of labral cartilage or bone.	<input type="checkbox"/>	<input type="checkbox"/>
(d) Rotator cuff tendinopathy manifests as fluid signal intensity on T2-weighted sequences.	<input type="checkbox"/>	<input type="checkbox"/>
Question 4. Concerning MR arthrography of rotator cuff tears:		
(a) Full-thickness tears appear as a gap in the entire thickness of the tendon, with contrast agent filling the gap and extending into the subacromial bursa.	<input type="checkbox"/>	<input type="checkbox"/>
(b) Bursal surface tears are well appreciated on T1-weighted sequences.	<input type="checkbox"/>	<input type="checkbox"/>
(c) Intra-articular injected air bubbles or extra-articular injection assist in diagnosis.	<input type="checkbox"/>	<input type="checkbox"/>
(d) Procedural requirement needs to be weighed against the associated invasiveness of the procedure, patient discomfort, temporary increase in joint-related pain, ionising radiation exposure and resultant longer examination time.	<input type="checkbox"/>	<input type="checkbox"/>
Question 5. Ultrasonography of rotator cuff tears:		
(a) Can demonstrate full-thickness supraspinatus tears, but not partial-thickness tears.	<input type="checkbox"/>	<input type="checkbox"/>
(b) Is an operator-dependent modality and may be associated with detection errors, misinterpretation and inherent errors.	<input type="checkbox"/>	<input type="checkbox"/>
(c) Helps to detect deep-seated lesions of labral cartilage or bone.	<input type="checkbox"/>	<input type="checkbox"/>
(d) Offers the benefits of lower cost and reduced examination time, and is used as the first-line investigation for the screening and detection of rotator cuff tears in several centres.	<input type="checkbox"/>	<input type="checkbox"/>

Doctor's particulars:

Name in full : _____

MCR number : _____ Specialty: _____

Email address : _____

SUBMISSION INSTRUCTIONS:

(1) Log on at the SMJ website: <http://www.sma.org.sg/publications/smjcurrentissue.aspx> and select the appropriate set of questions. (2) Provide your name, email address and MCR number. (3) Select your answers and click "Submit".

RESULTS:

(1) Answers will be published in the SMJ November 2013 issue. (2) The MCR numbers of successful candidates will be posted online at the SMJ website by 25 October 2013. (3) Passing mark is 60%. No mark will be deducted for incorrect answers. (4) The SMJ editorial office will submit the list of successful candidates to the Singapore Medical Council. (5) One CME point is awarded for successful candidates.

Deadline for submission: (September 2013 SMJ 3B CME programme): 12 noon, 18 October 2013.